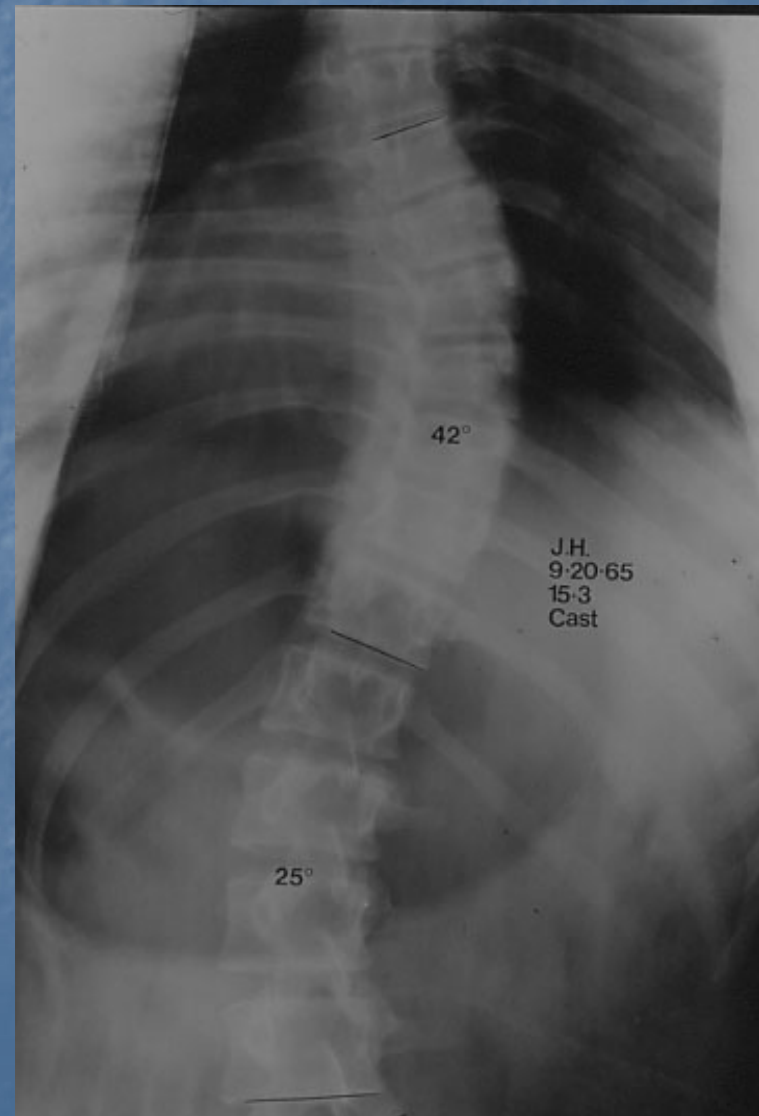
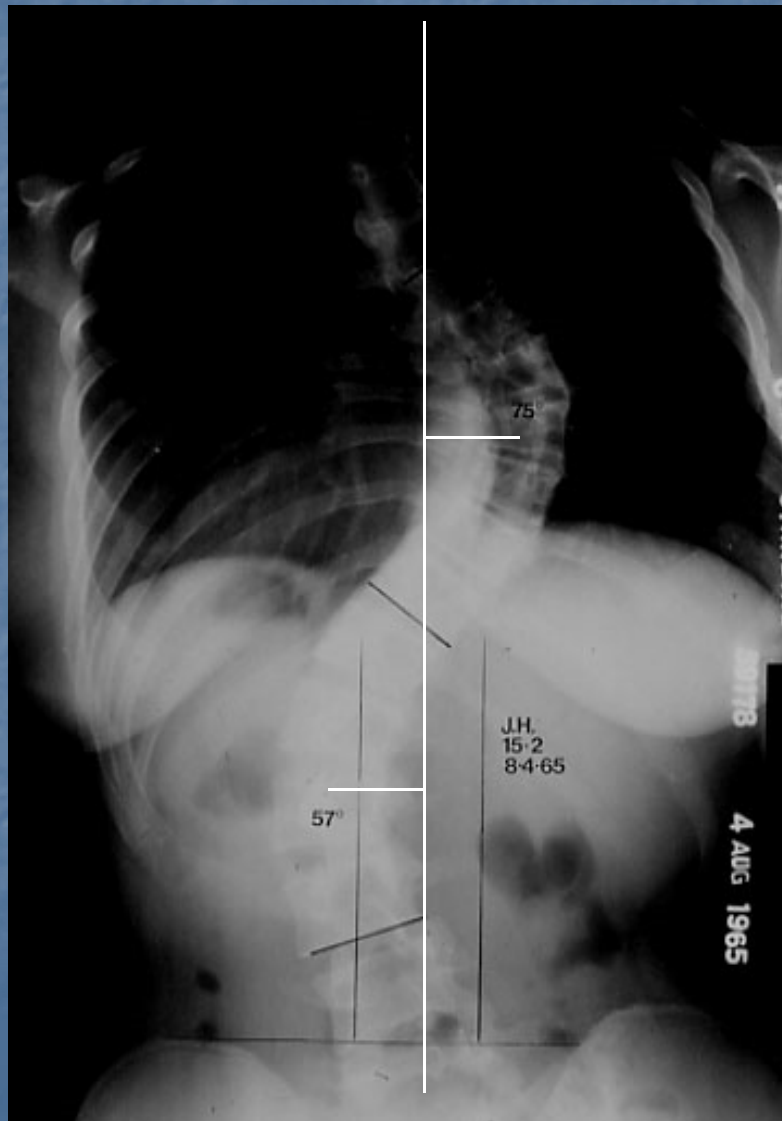


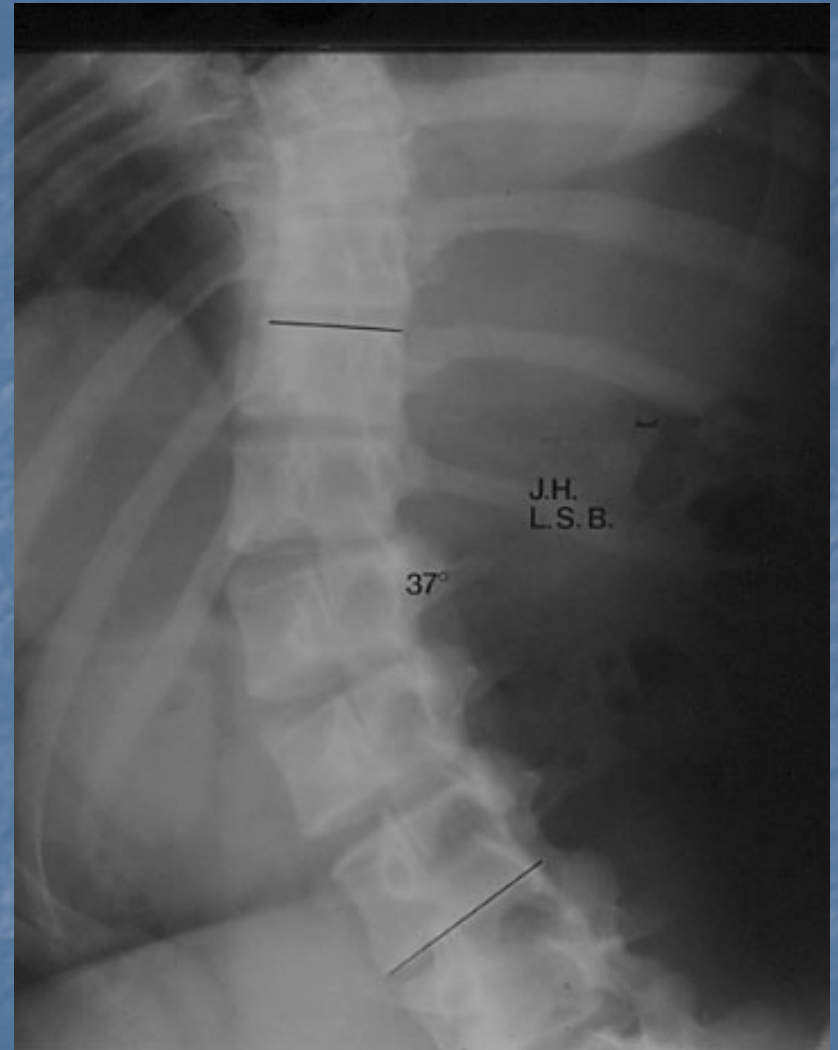
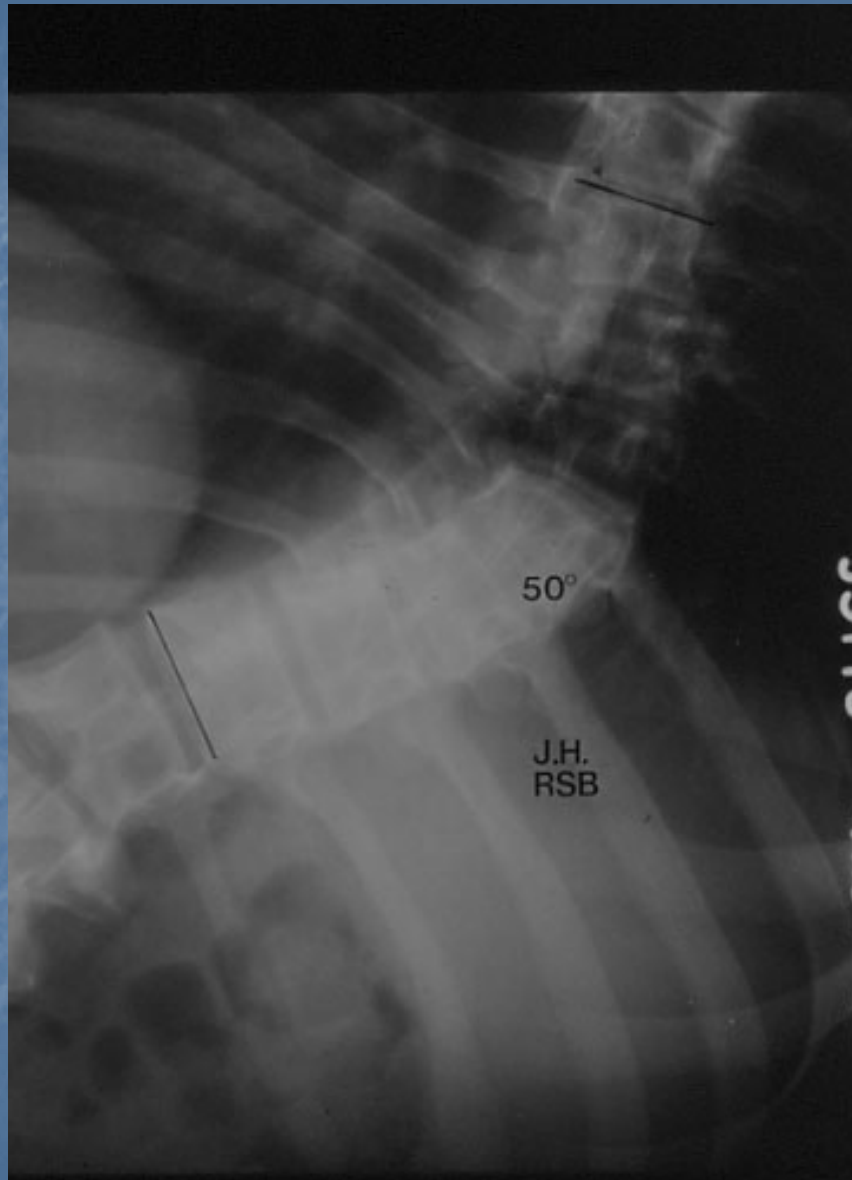


FUSION

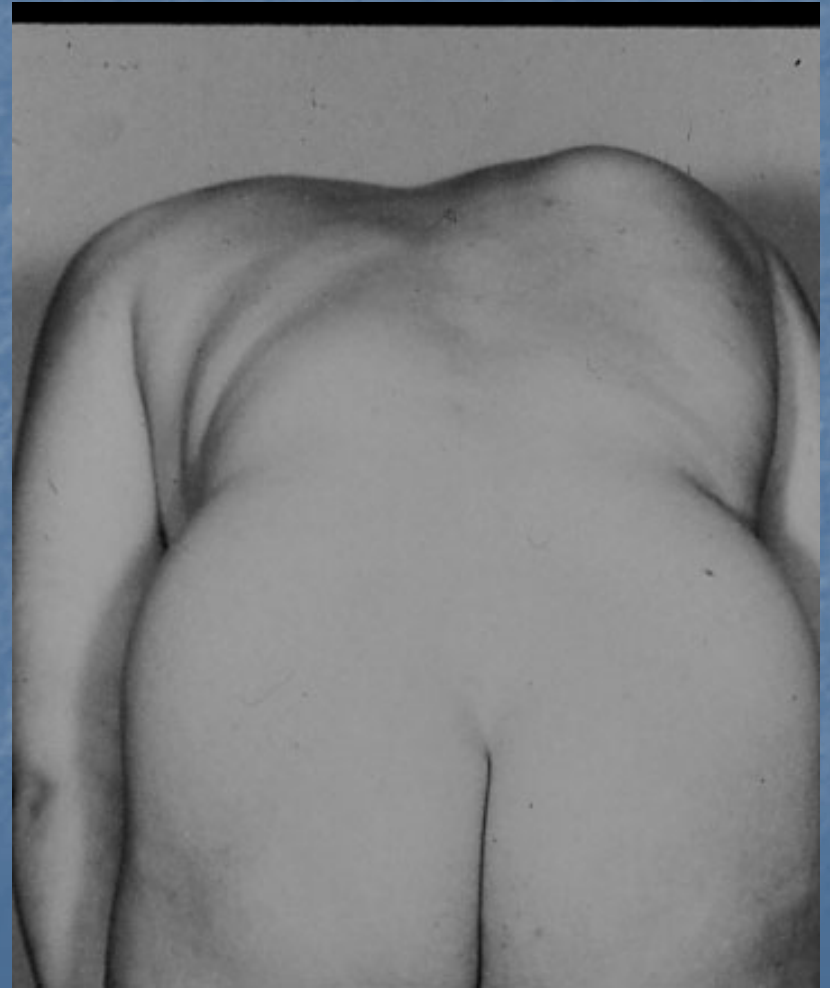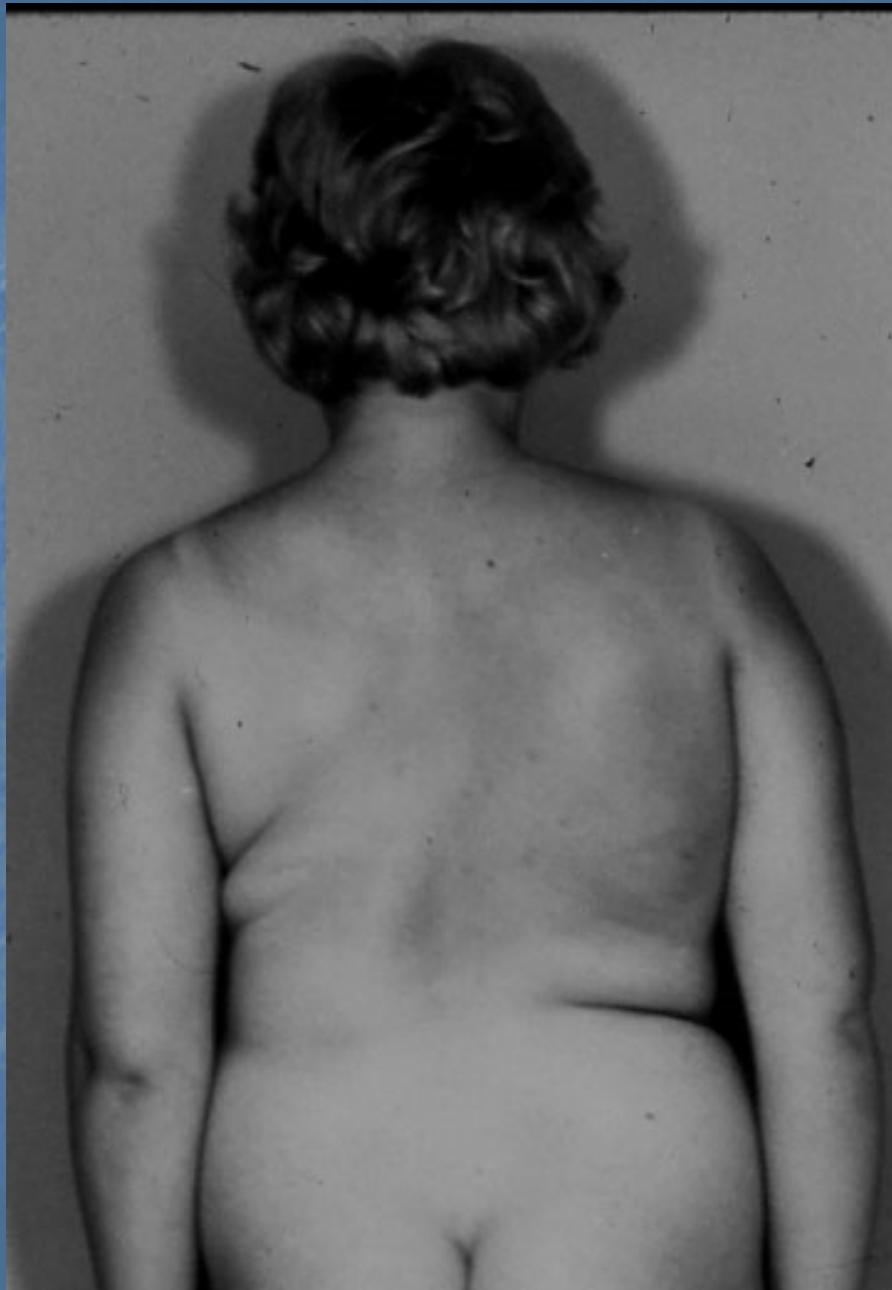WWW.QAAUAS.COM

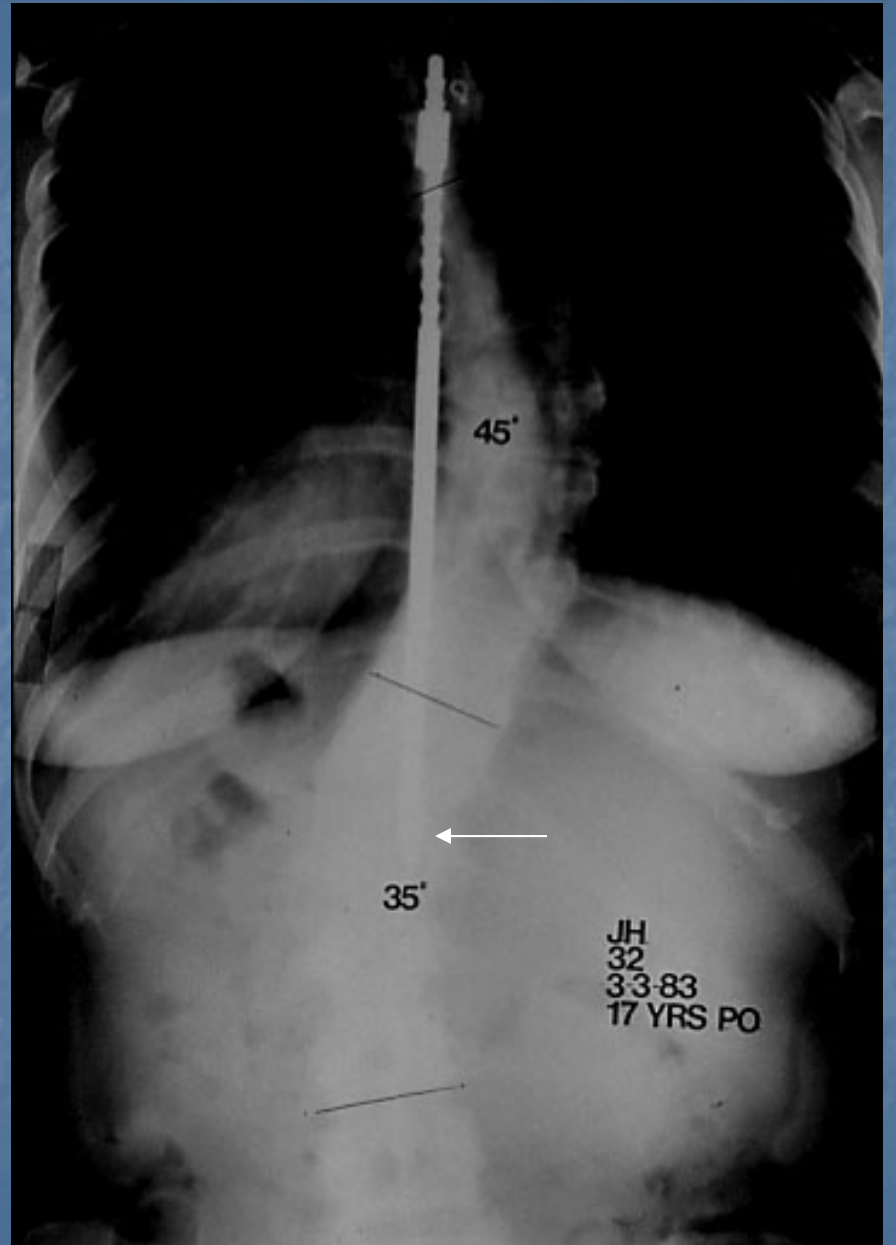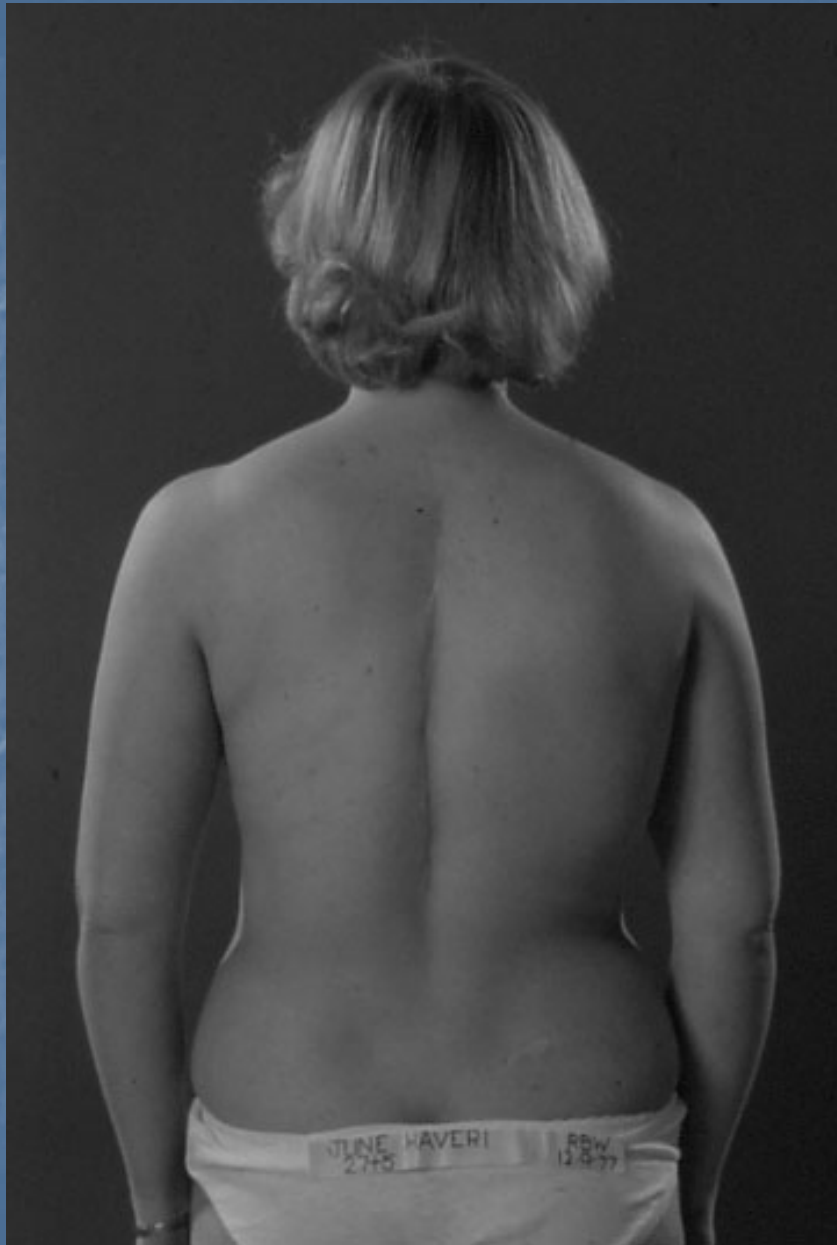With Gratitude to JH Moe and RB Winter
King-Moe II (Lenke 1C)

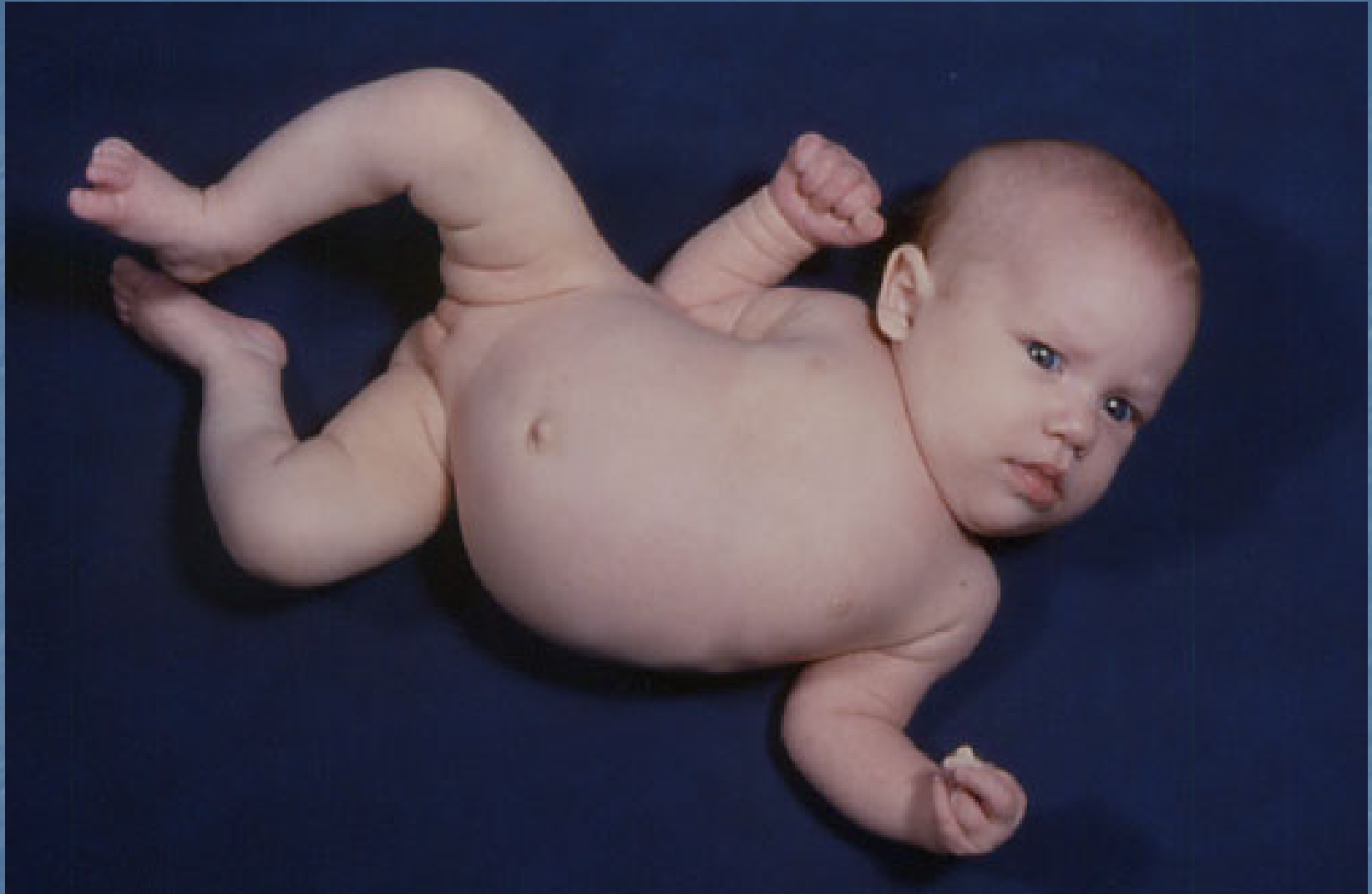



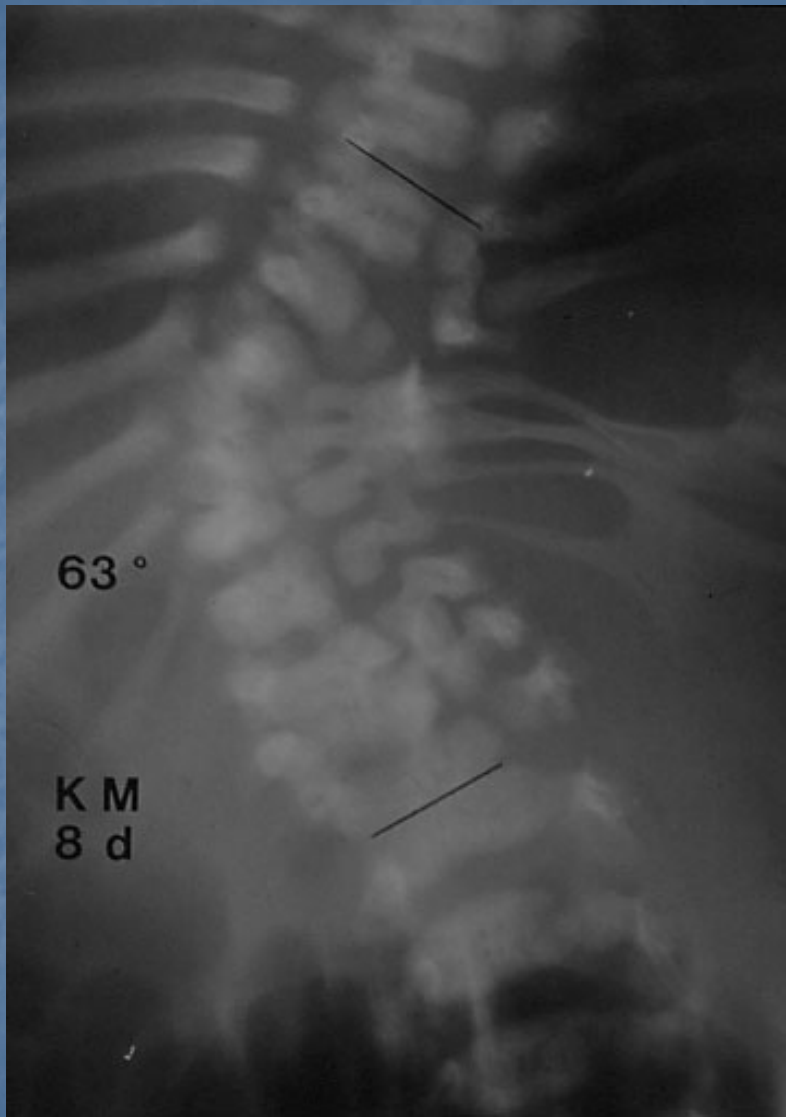
Supine bend film analysis



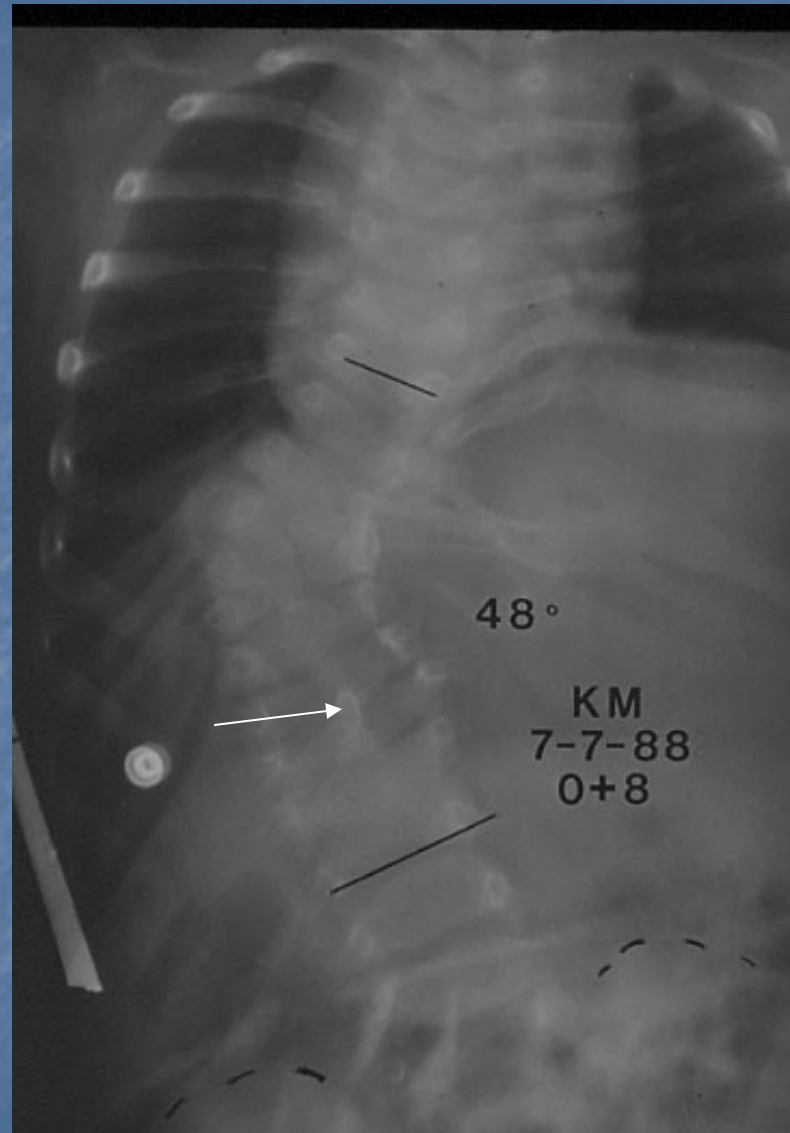




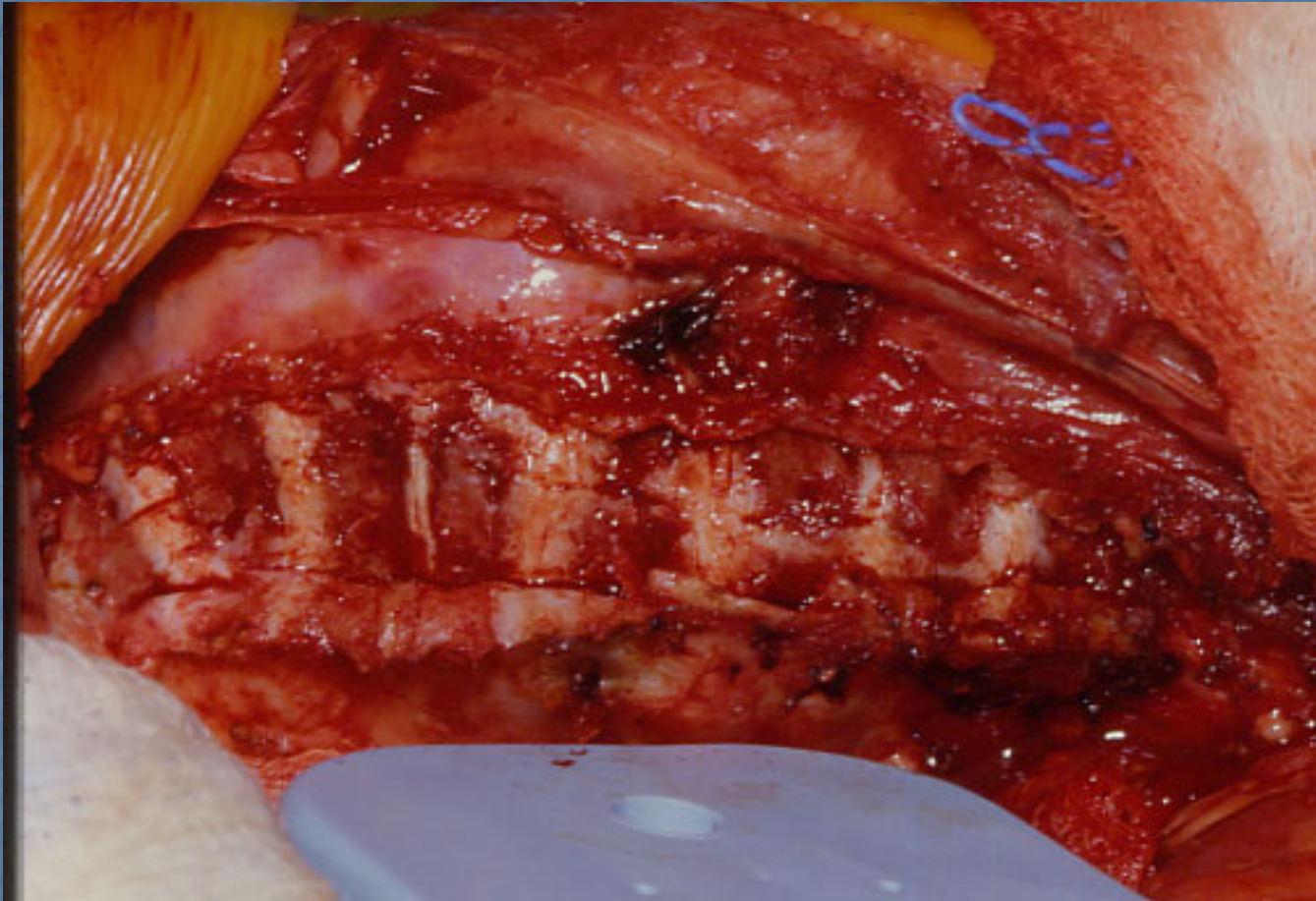
10 week old baby



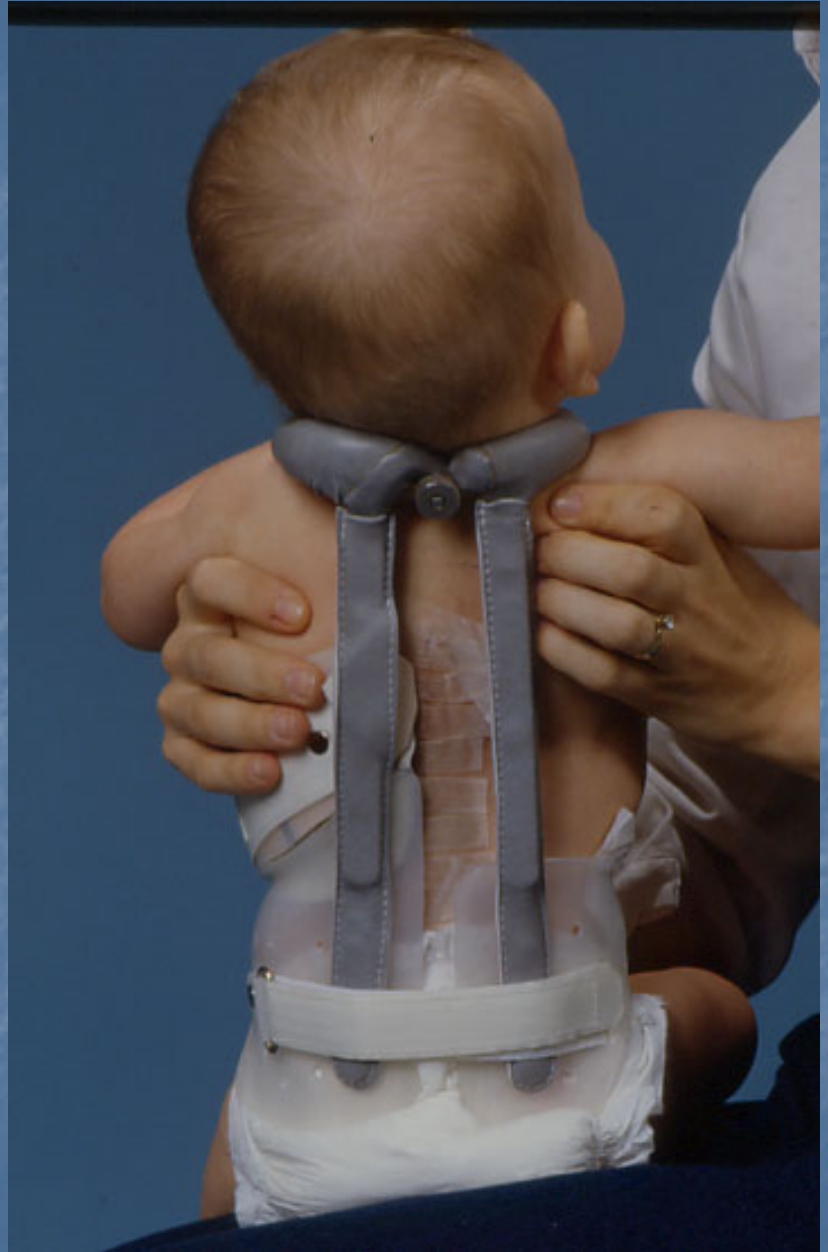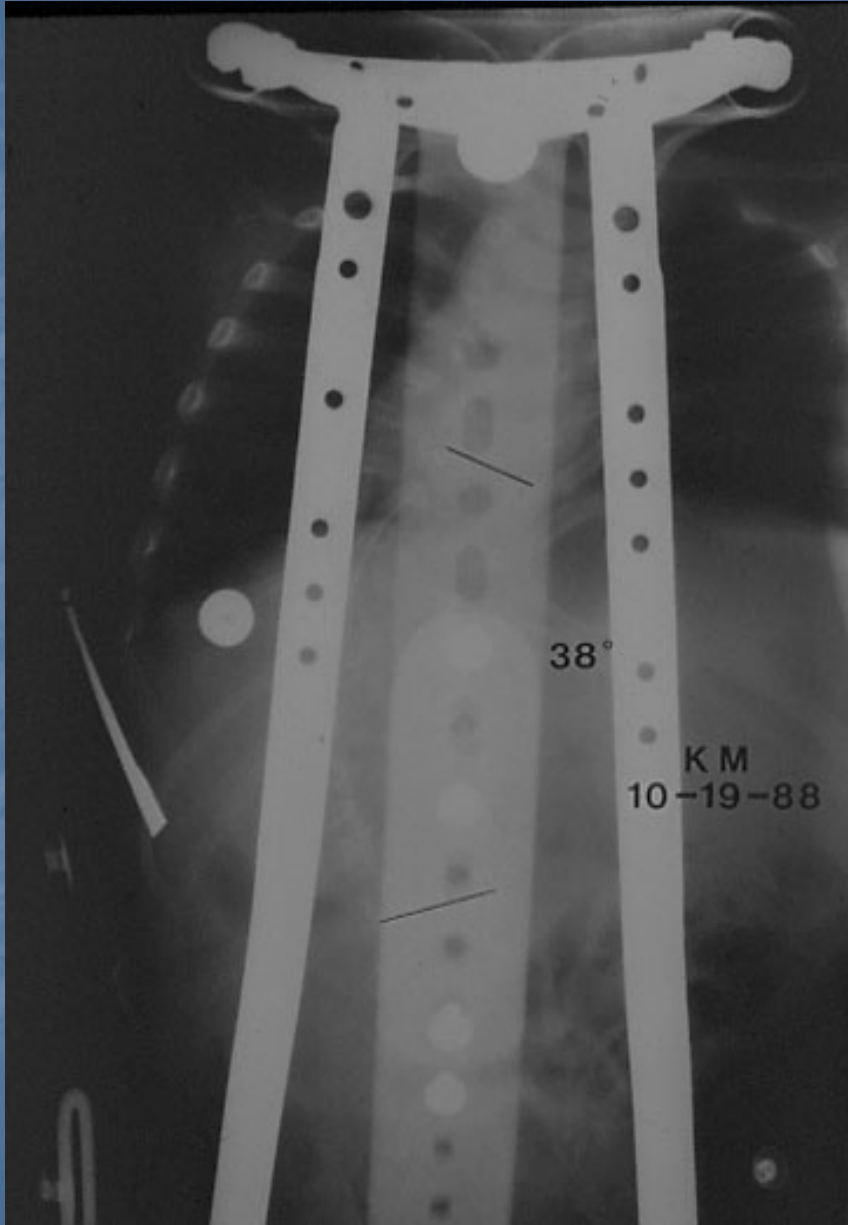
Age 8 days

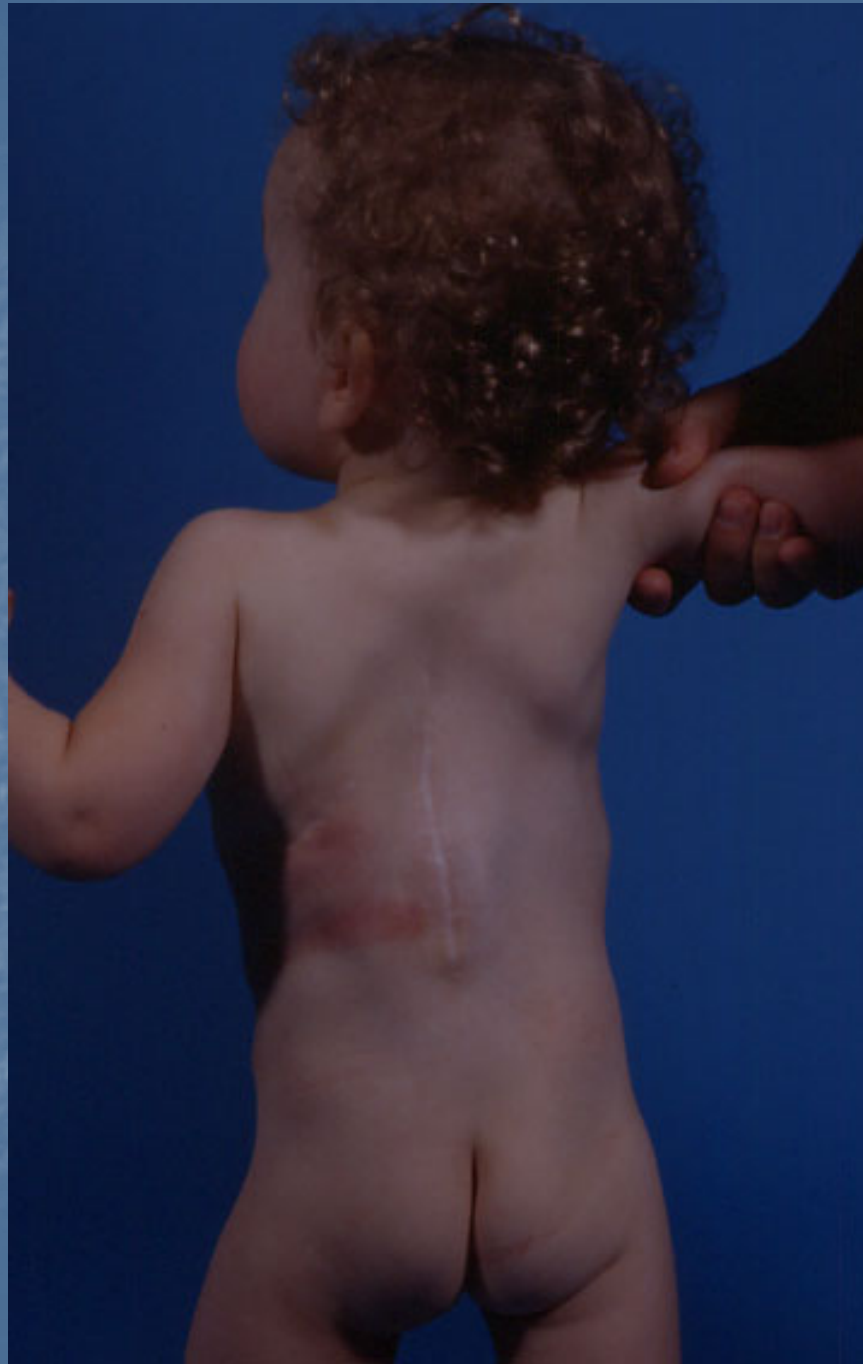

Age 8 mo. In brace

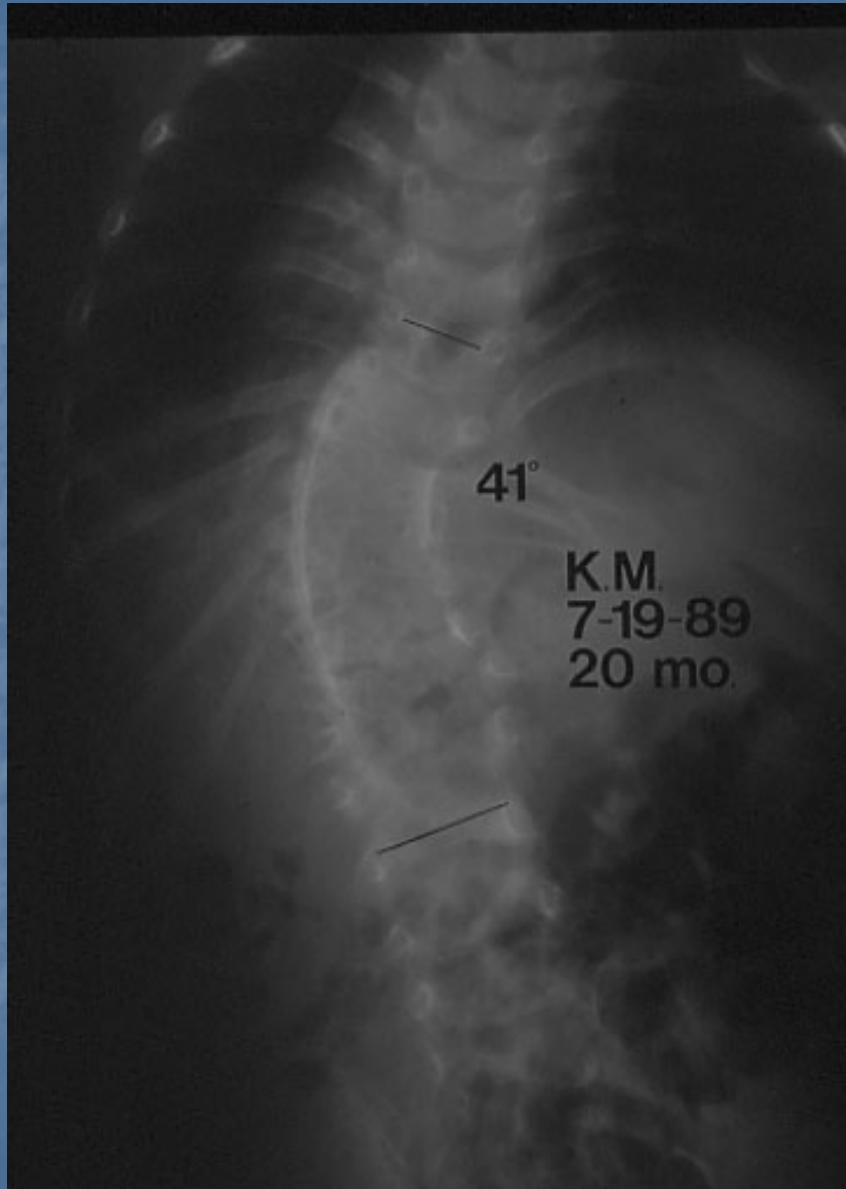


Epiphysiodesis at 12 months

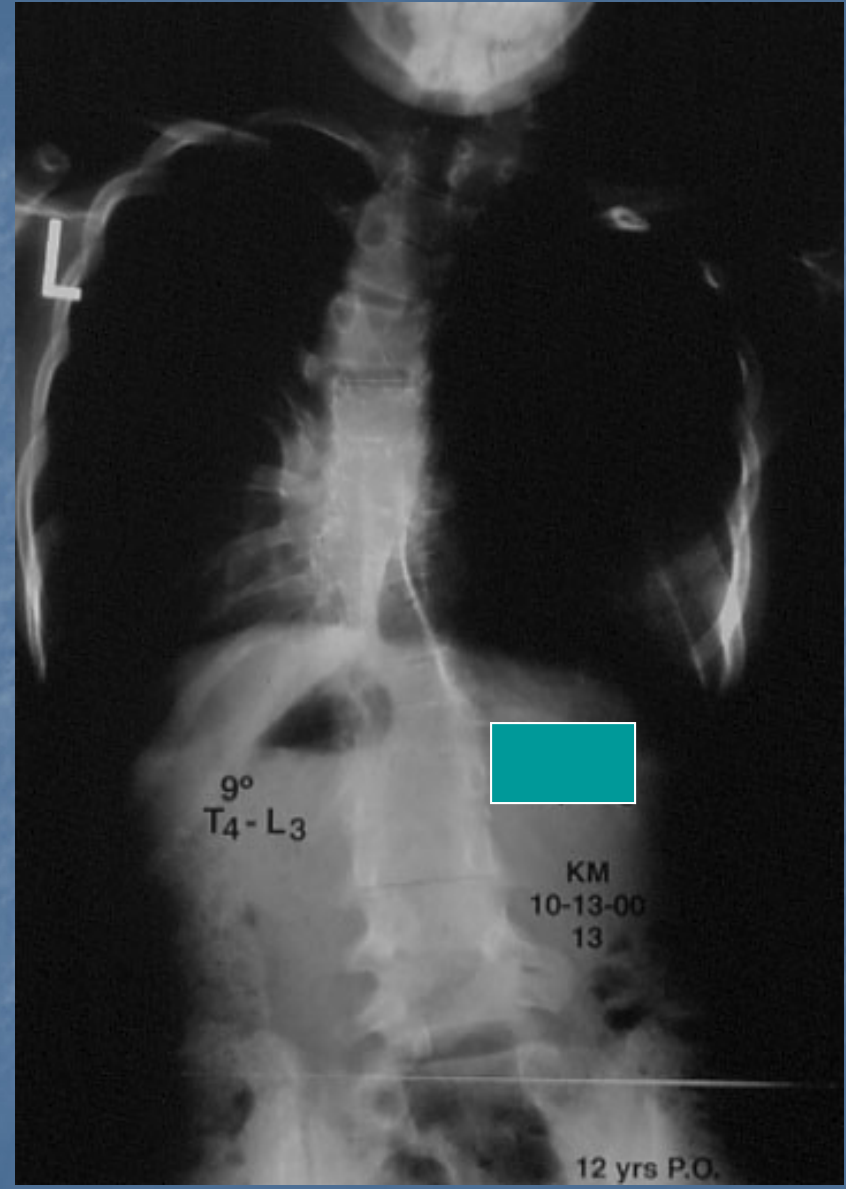




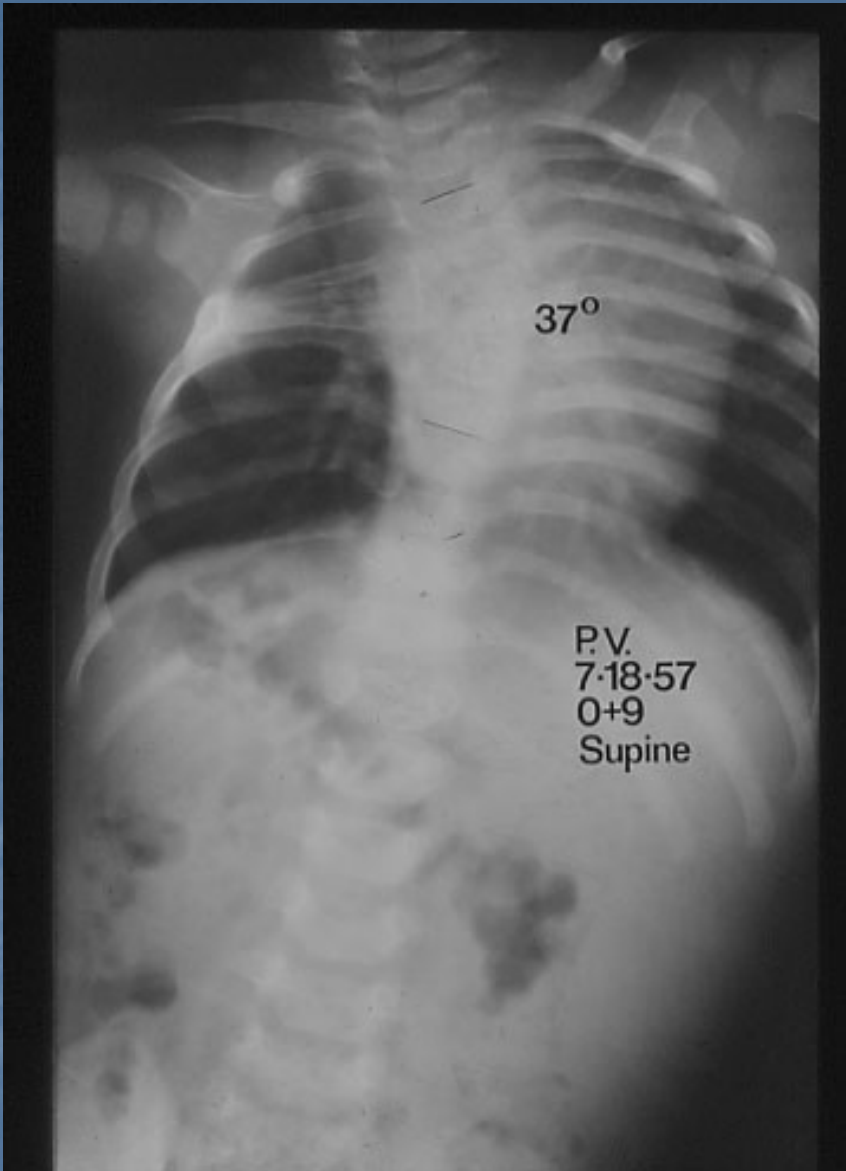
Age 18 months,
6 months after
surgery



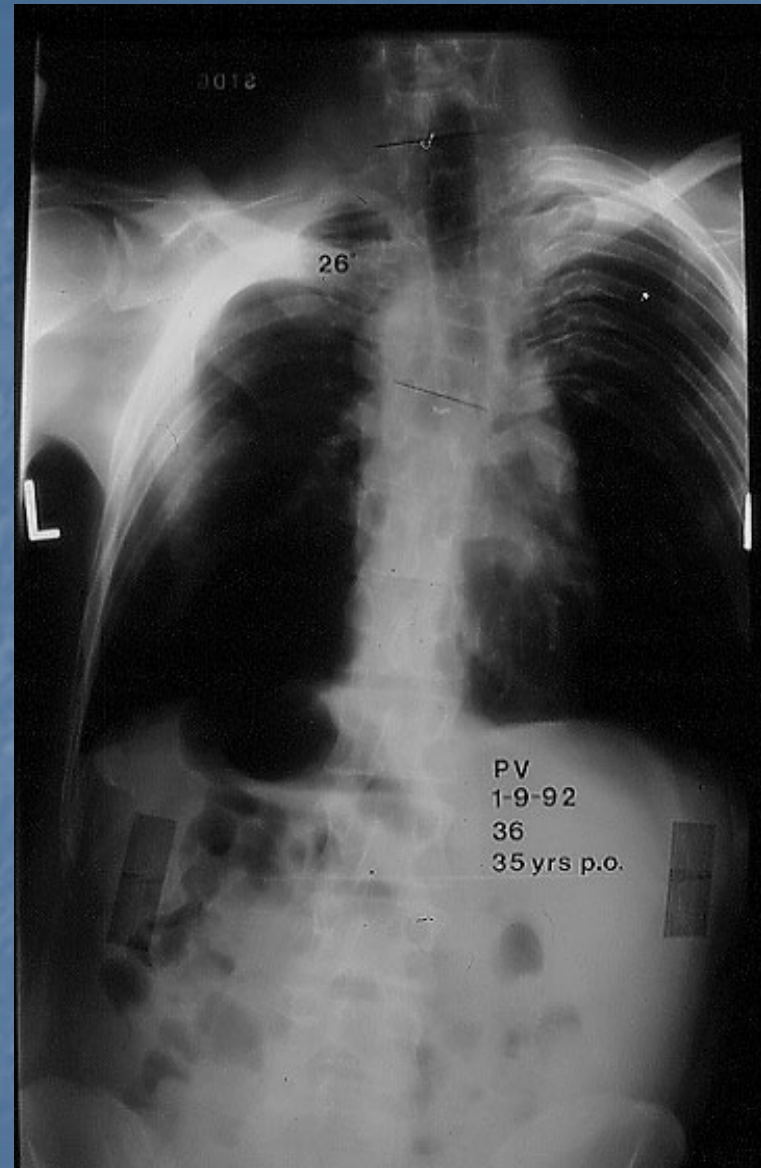
One year post-op



12 years post-op



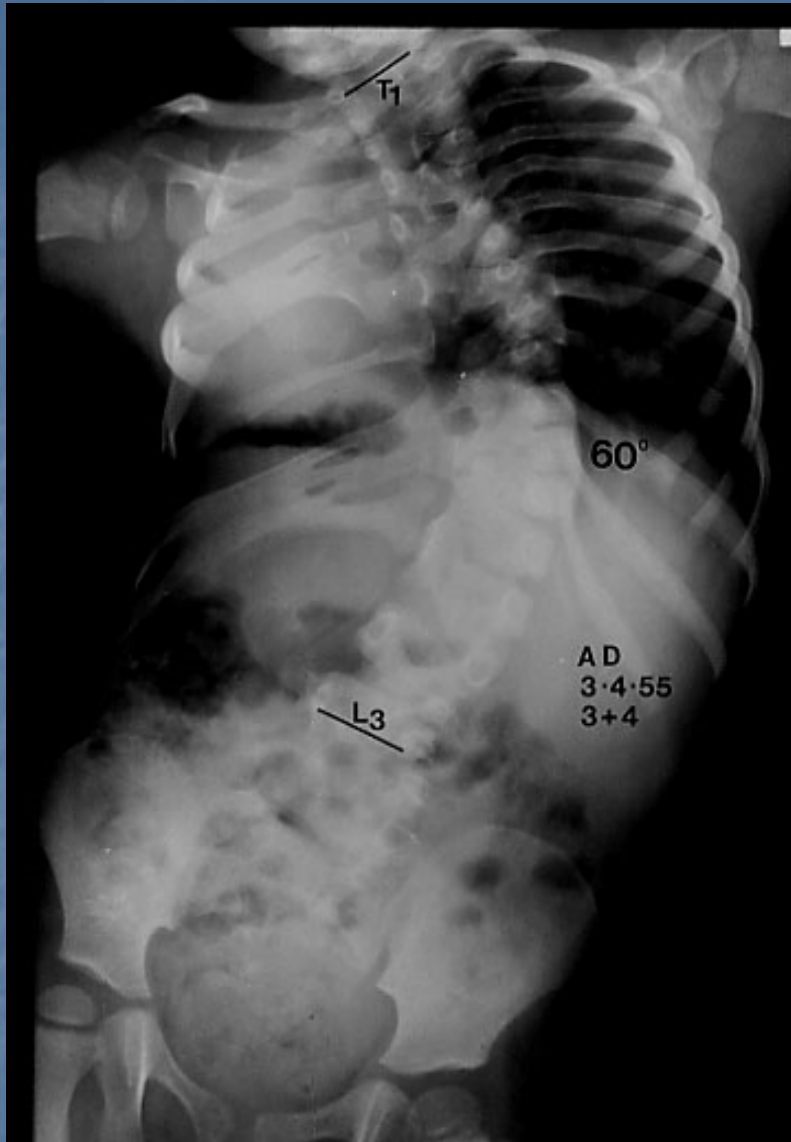
Posterior spine fusion C7-T8, age 1



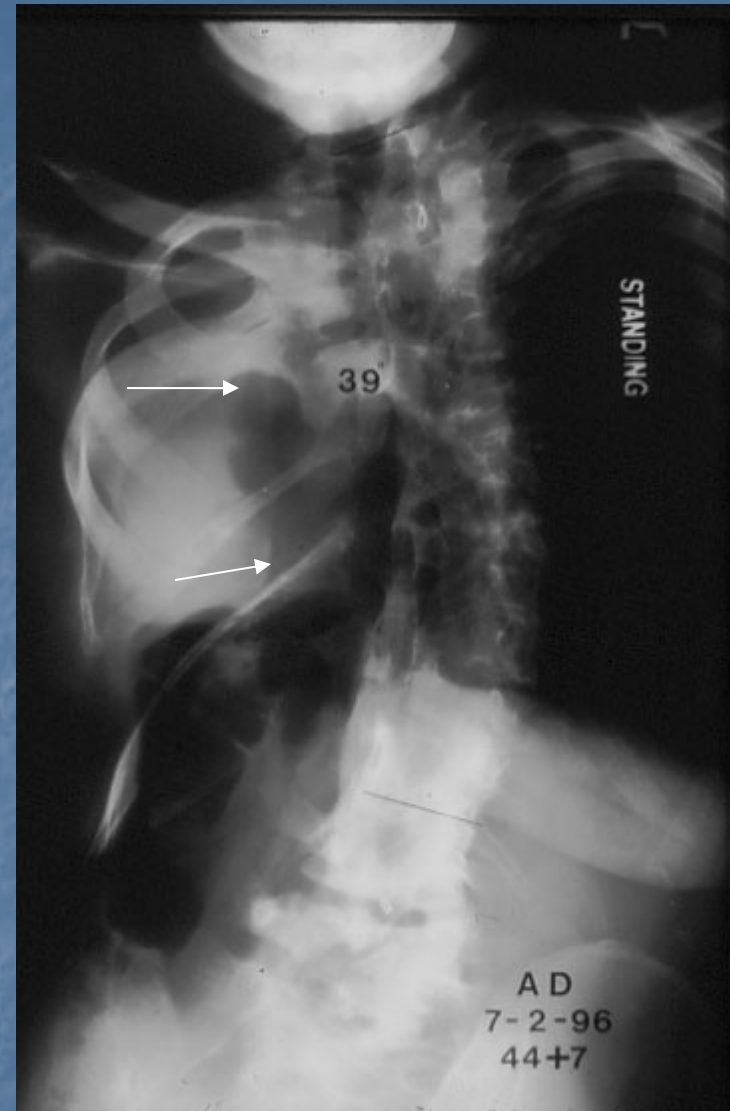
35 year follow-up, FVC 70%



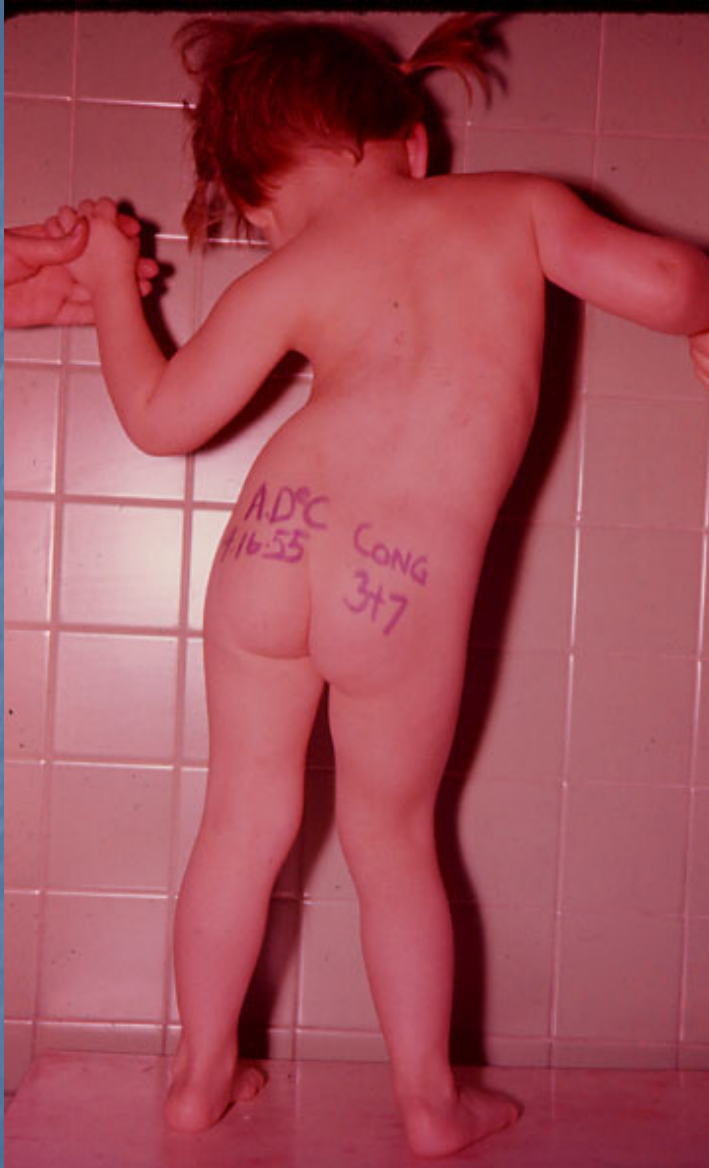35 years after fusion at age 1 year.



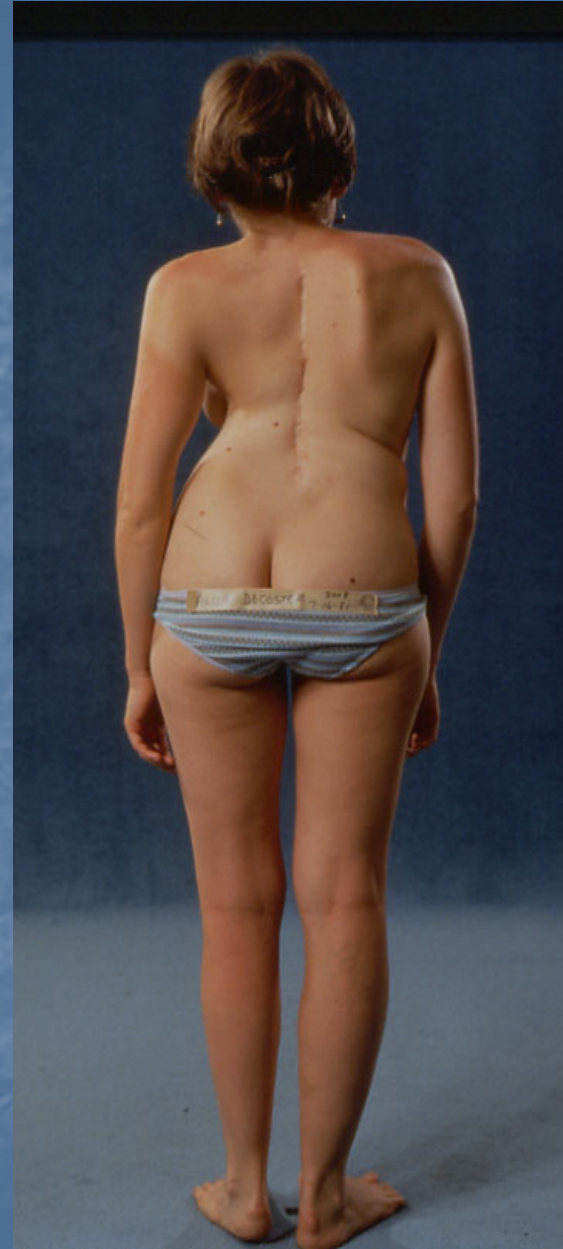
Posterior spine fusion age 3 years,
Note agenesis of left lung. Was 90°
at 12 months



41 year follow-up, FVC 70%
(total thoracic fusion)



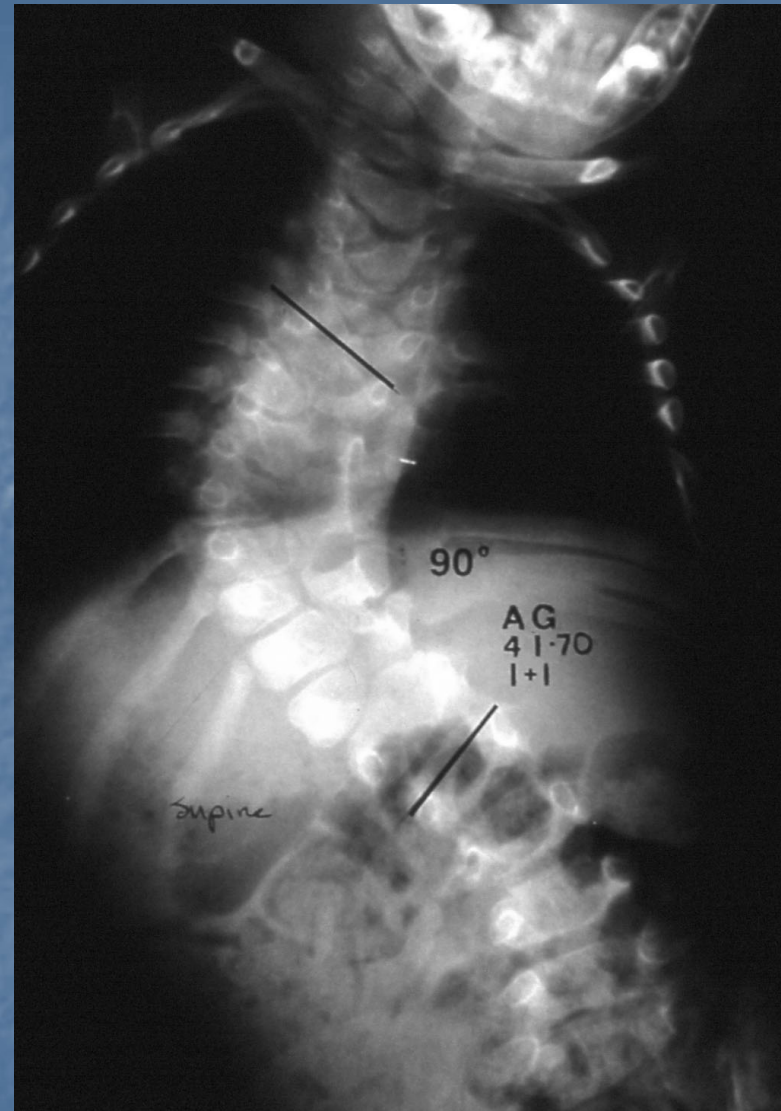
Age 3 years



Age 44 years

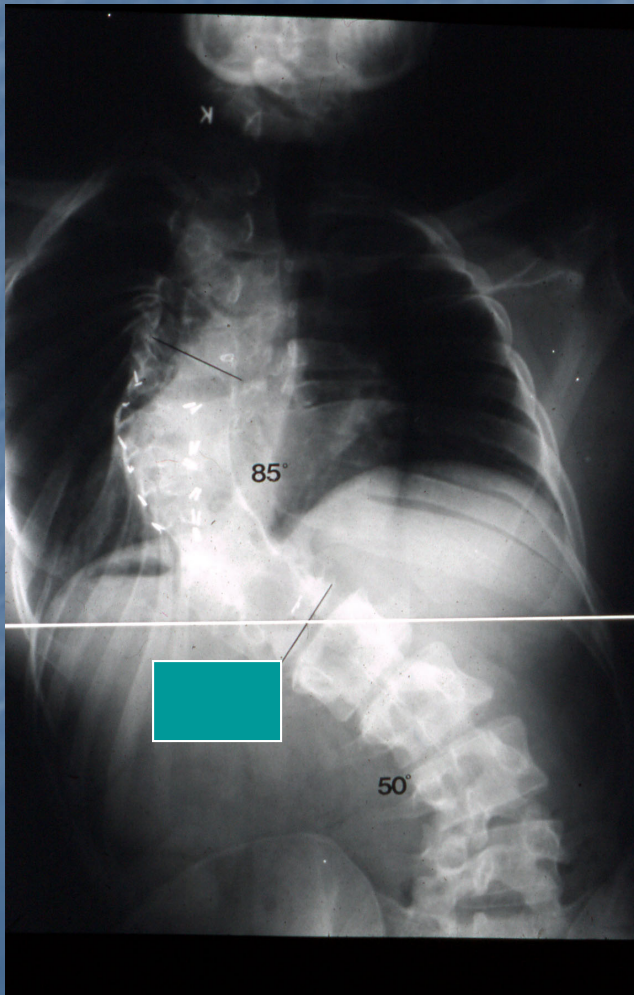
Progressive congenital scoliosis due to a unilateral unsegmented bar with contralateral hemivertebra and fused ribs in the concavity.

What is the best treatment?



Age 1, pre-fusion

Is this a good result?



- Follow-up at age 36, 35 years after surgery.
- Blood gasses normal
- FVC 50%
- Married, 3 children
- Excellent golfer
- No back pain