

Spinal Height (T1-T12) in Shilla Patients Who Have Reached Maturity

Richard E. McCarthy, M.D.

Frances L. McCullough, MNSc.

Disclosures

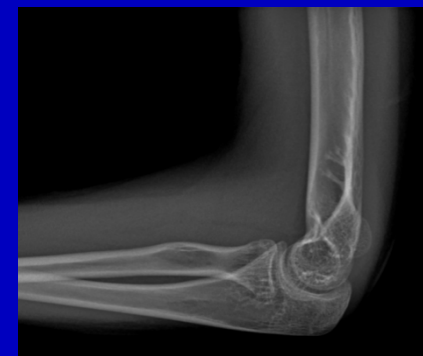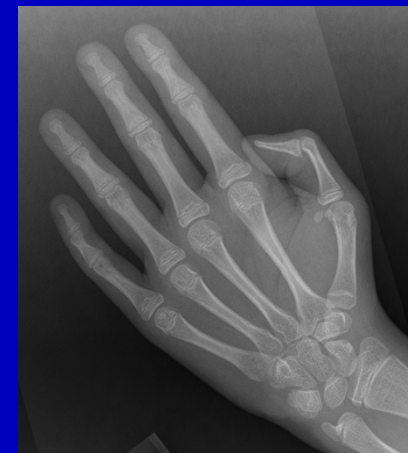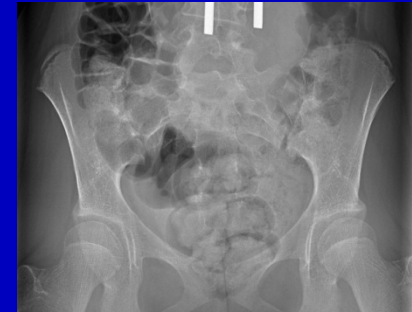- The Primary Author is the Inventor of this procedure and its most vigilant critic
- Consultant for Medtronic (teaching courses, planning group, royalties)

Background

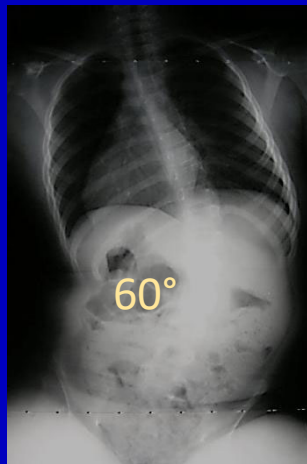
- The Shilla technique is a growth guidance technique that does not require scheduled returns to the operating room every 6 months
- Spinal height of **180 mm** is a minimal goal of treatment in EOS (Karol, et al.)

SYMPOSIUM: EARLY ONSET SCOLIOSIS
Early Definitive Spinal Fusion in Young Children
What We Have Learned
Lori A. Karol MD
Clin Orthop Relat Res (2011) 469:1323–1329

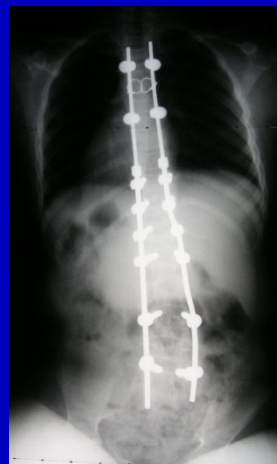
- **16 patients** (13 males, 3 females) who underwent the Shilla procedure have reached sufficient skeletal maturity to undergo their definitive procedure
 - Skeletal maturity was determined by bone age, Risser sign, menarche, and/or closure of triradiate cartilage while considering menarche and chronologic age.
 - Diagnosis (important factor)
 - Idiopathic (4)
 - Syndromic (5)
 - Neuromuscular (6)
 - Congenital (1)



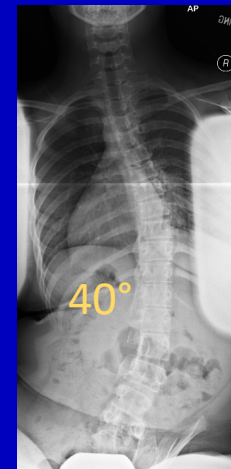
- Definitive procedures consisted of:
 - Removal of Growing Rods, Insertion of permanent instrumentation with fusion and any necessary further correction: 14 patients
 - Implant removal alone: 4 patients
- Average age at definitive procedure: 13+5 yrs
(Range 8+11 to 15+4 yrs)
- Average growth period with Shilla instrumentation preceding definitive procedure: 4+4 yrs
(Range 1+6 to 8+6 yrs)



Preop films of 8 yr old
with spinal cord injury



Postop Shilla

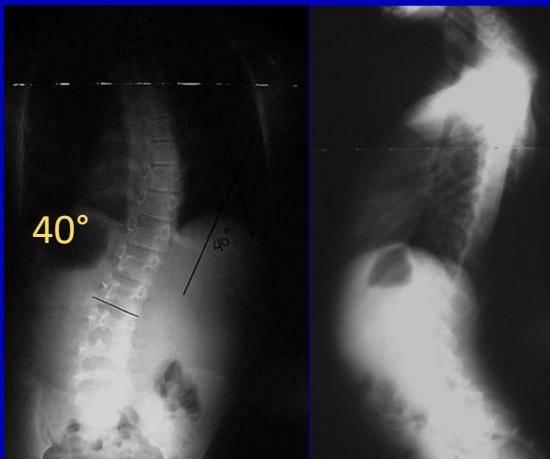


2 yrs after implant removal
at age 12

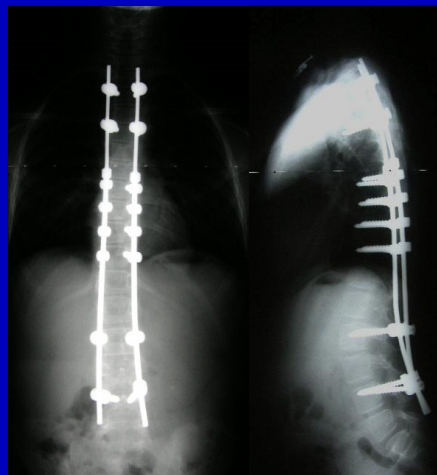
T1-T12 measurements

- Initial measurement on first postop film after index procedure
 - Average T1-T12 was 220 mm (range 180-231 mm)
- Second measurement on film immediately prior to definitive procedure
 - Average T1-T12 was 234 mm (range 185-277 mm)
- Final measurement immediately following definitive procedure
 - Average T1-T12 was 246 mm (range 205-323 mm)

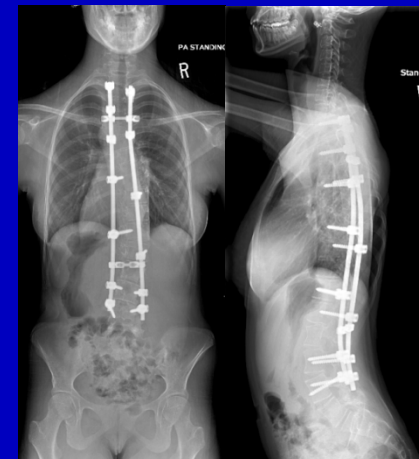
- **At skeletal maturity, all patients reached or surpassed the goal of 180 mm (246mm)**
- **There was a 12.4% improvement in spinal height with growth alone**
 - There was an additional **6.3% increase** in height with final correction (representing the flexibility remaining in spine at end of growth)



Preop films of 10 yr old with tubular myopathy



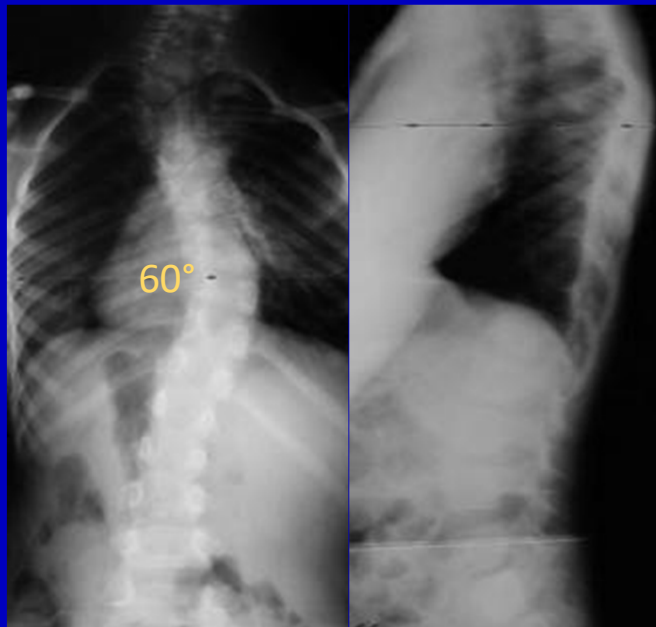
Post Shilla



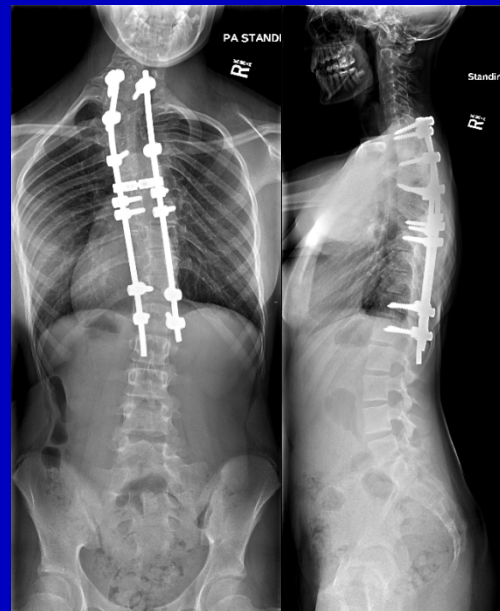Films post definitive fusion at 14 yrs of age

Conclusion

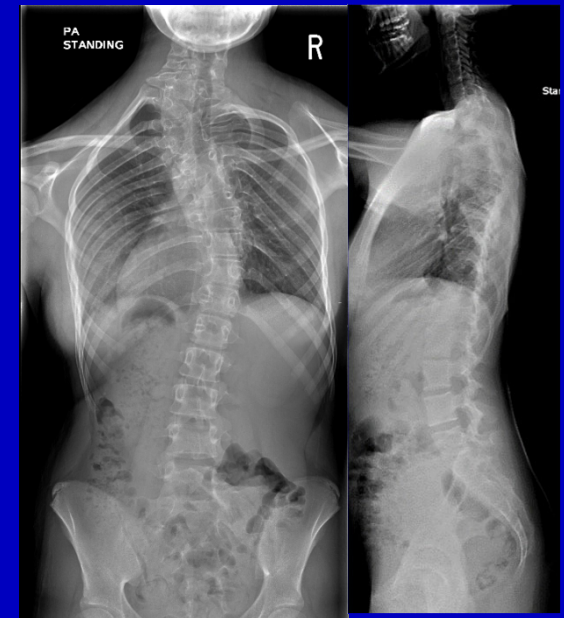
Shilla growth guidance technique does result in a satisfactory increase in spinal height without repeated artificial spinal distraction



Congenital Scoliosis
Preop 6 yrs old



14+9 yrs old
Prior to implant removal



Post implant removal