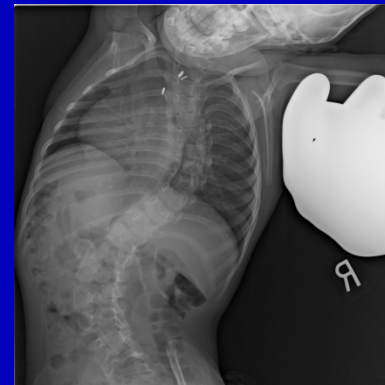
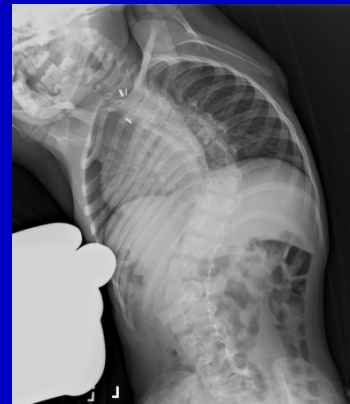

# Shilla: Techniques, Tips, and Tricks

Richard E. McCarthy, M.D.  
Professor, Departments of Orthopaedics and Neurosurgery  
University of Arkansas for Medical Sciences  
Arkansas Children's Hospital  
Little Rock, Arkansas

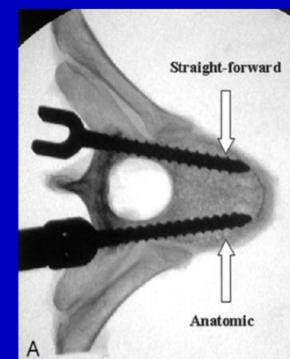
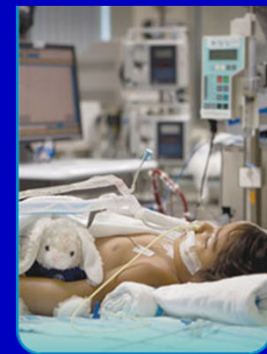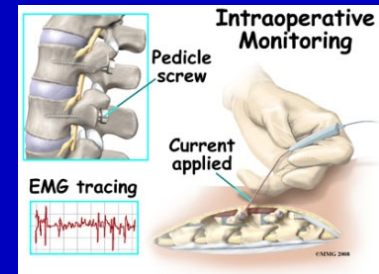
# Preoperative Assessment

- Flexibility films
- MRI-intrathecal
- CT- check pedicles
- Bone density

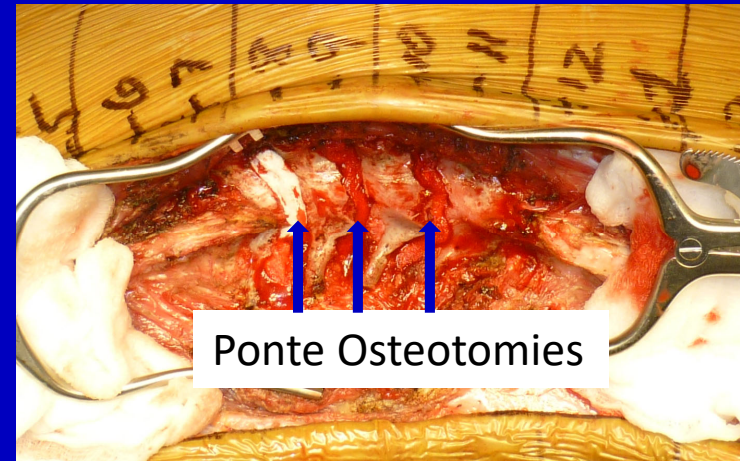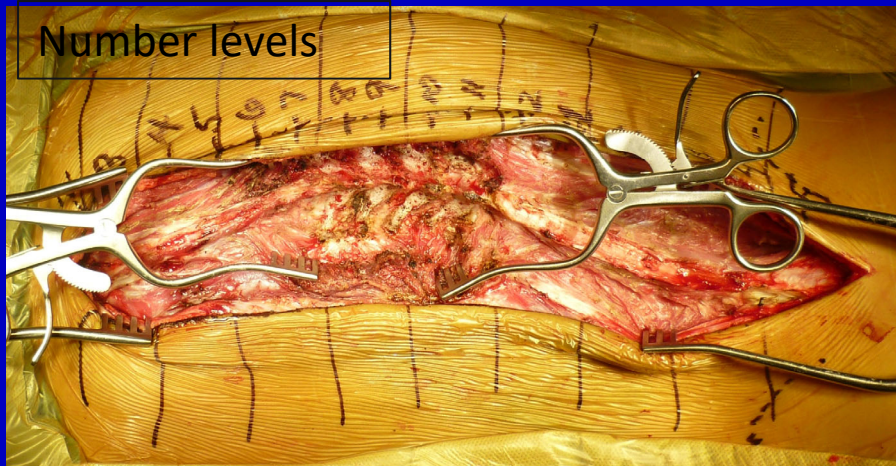


# Intraoperative Safety Factors

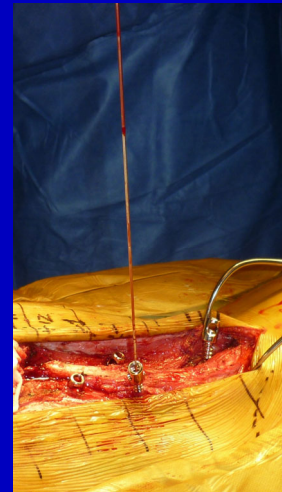
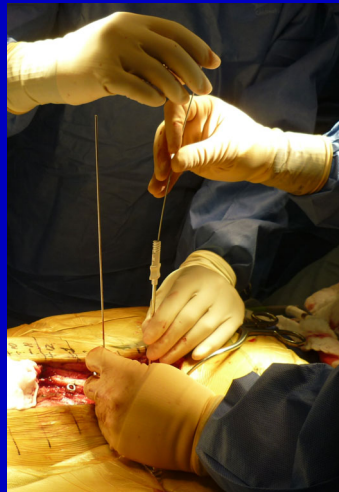- Ability to monitor cord function
  - SSEP and MEP
- Cell saver
- C-arm, O-arm, navigation systems
- Skilled anesthesia team
- Antibiotics, antifibrinolytics
- Skill and attention to detail in surgical team



- Dissection – subperiosteal at apex

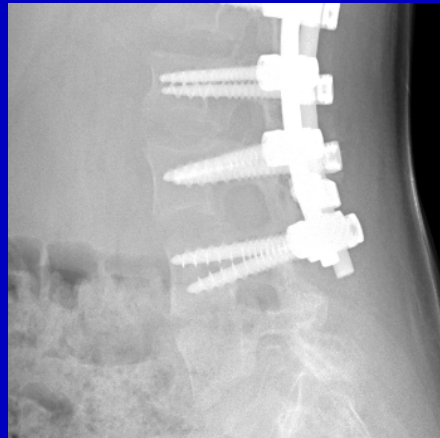


- Flouroscoy for growing screws (Pediguard)

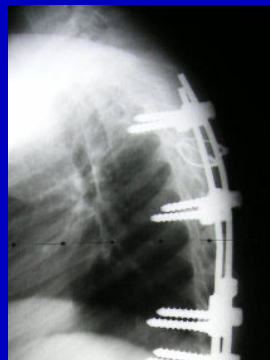
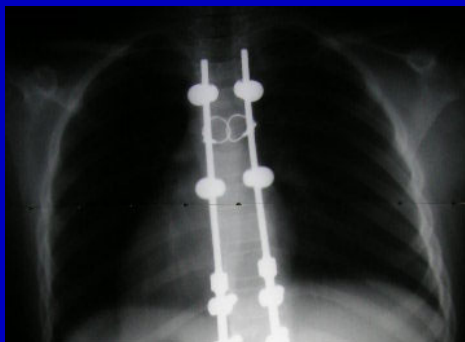


# Screws

- Fill the pedicle (large size screws)
  - Deep into vertebral body

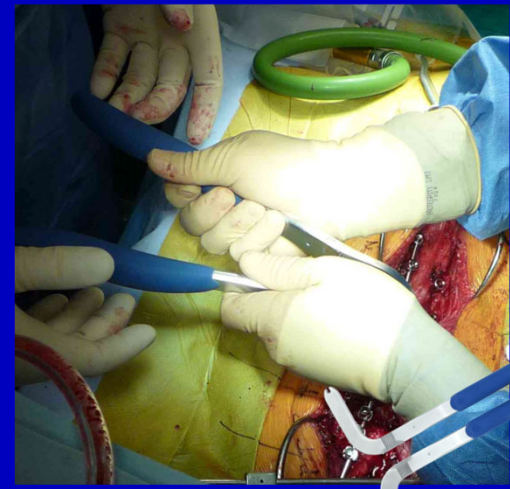
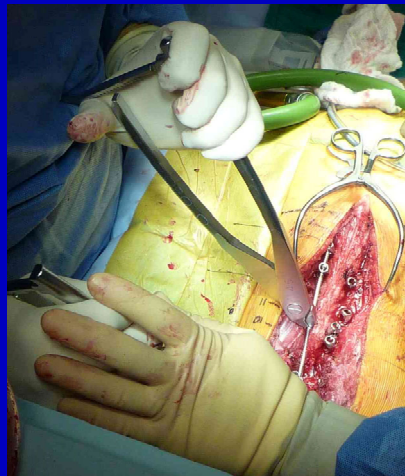
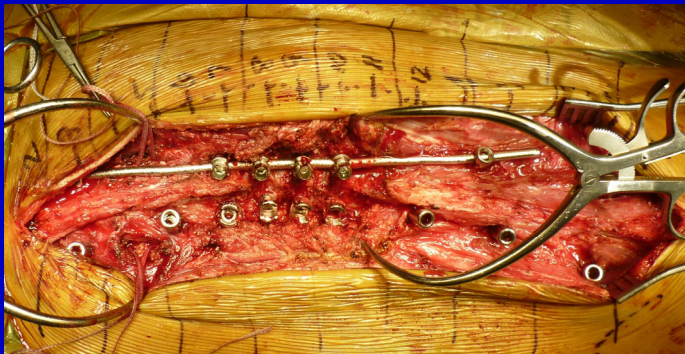


- Wires or tapes (fiberwire) may help to reinforce



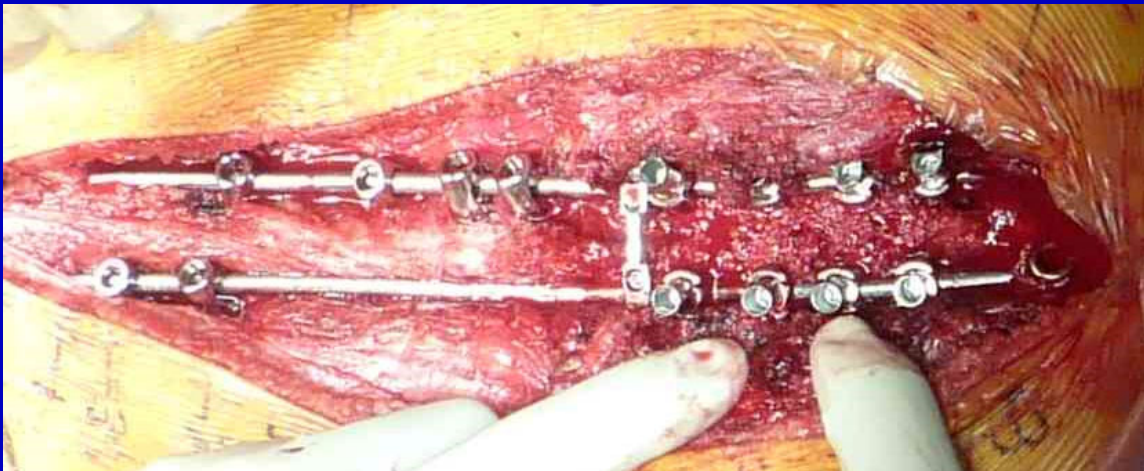
# Correction

- Goal is apex to neutral
- Provisional convex rod with in situ bending
  - Push apex towards concavity



# Correction

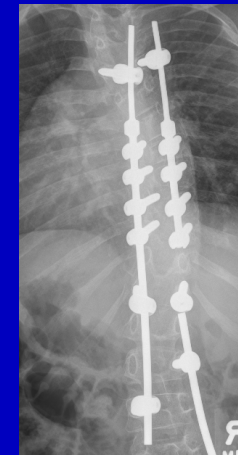
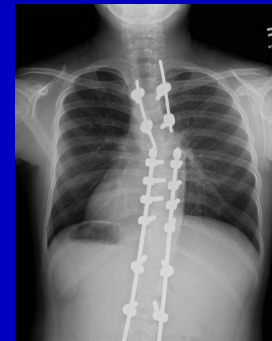
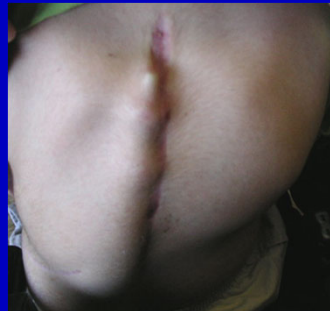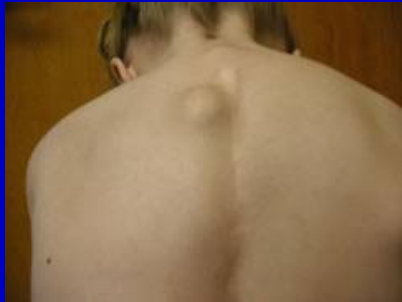- Cross link just below the apex to control the tendency of rods to spring back



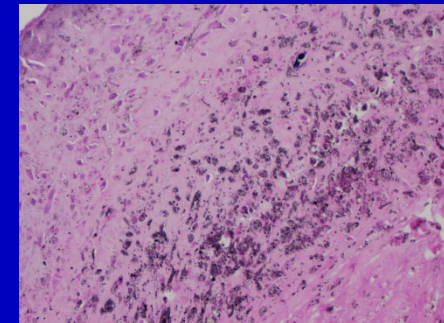
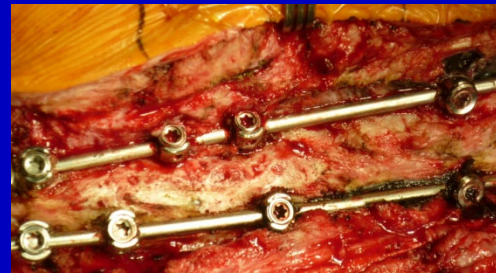
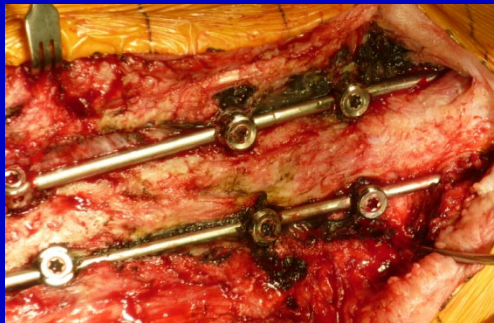
- In child less than 5 yrs old, use sliding crosslink to allow growth of canal diameter

# Follow-up: Persistence helps

- Implant problems happen
  - Prominence and breakage (replace both rods)

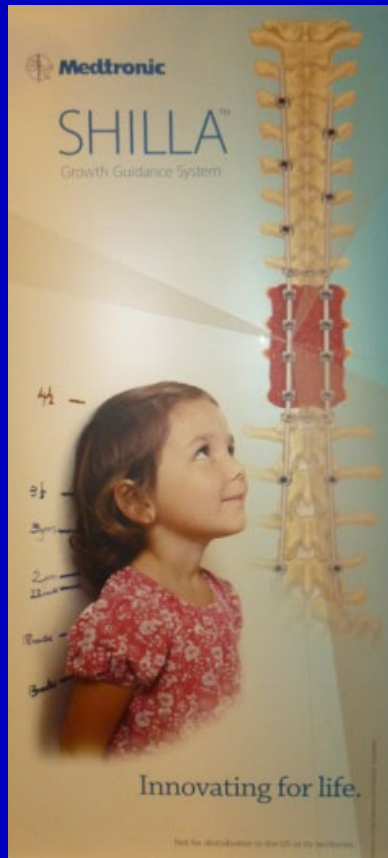


- Metallosis happens





# Long-term results



- Allows spine to grow
- Keeps child out of O.R.
- Some sports allowed