

# Combined Use of Transpedicular Enucleating and a New Instrumentation Fixation in One Stage Operation as a Treatment for Progressive Hemivertebral Scoliosis

**Ye Qibin**, Wang Guanjun, Kuang Zhengda, Du Mingkui, Cao yang

Third Department of orthopedics, General Hospital of  
Chinese Armed Police Forces, and Peking Union  
Medical College Hospital

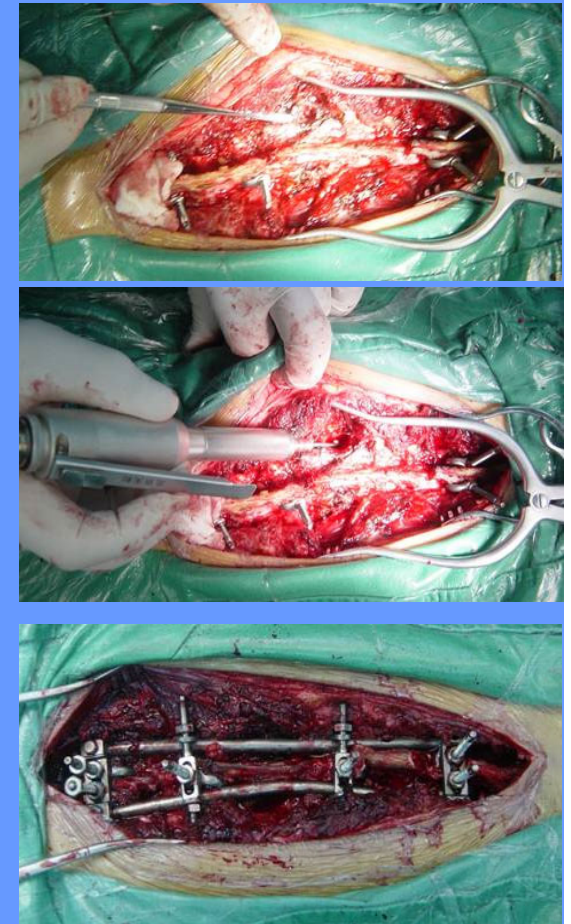
**Email:**[yeqibin@263.net](mailto:yeqibin@263.net)

- **BACKGROUND AND PURPOSE:** No study has reported the results of combined posterior hemiepiphysiodesis and instrumentation which is able to **modulate the asymmetrical spinal growth of the spinal column** in the later growing years after operation.
- Our study is a retrospective assess the effectiveness of combined use of transpedicular enucleating and a new instrumentation PRSS (Plate Rod System for Scoliosis) fixation in the treatment for growing hemivertebral (HV) scoliosis.

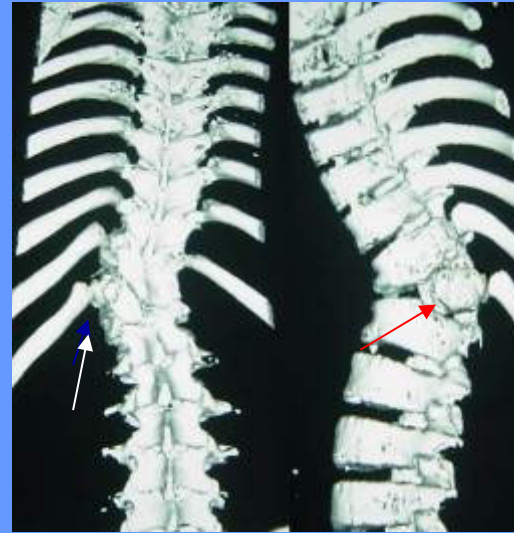
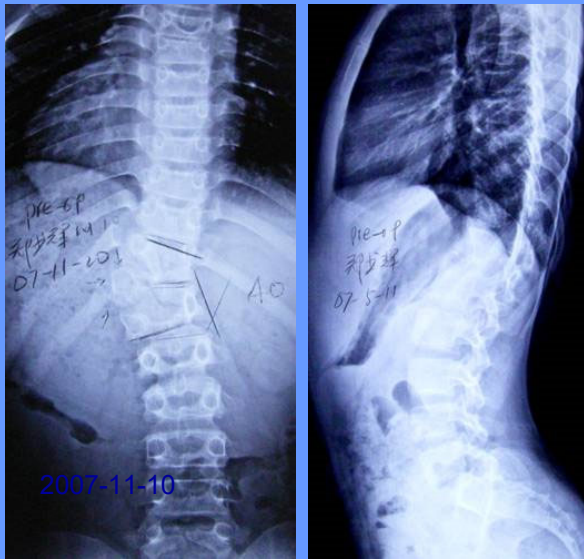**METHODS:** From June 2003 to April 2009, total 16 patients with progressive HV scoliosis underwent our combined methods. The mean age at operation was  $8.125 \pm 1.82$  years.

The technique involves :A small curette and a electrical drill was used to cannulate the pedicle and entere into the heimivertebral body to remove the cancellous bone for eliminating the blood supply of the cartilaginous endplate and destroy the superior and inferior vertebral end plate from the inner side of HV body, followed by PRSS fixation for desirable correction of the main curve and compensation curve and to maintained it .

Analysis included age at surgery, measured changes in scoliosis angle and complications.

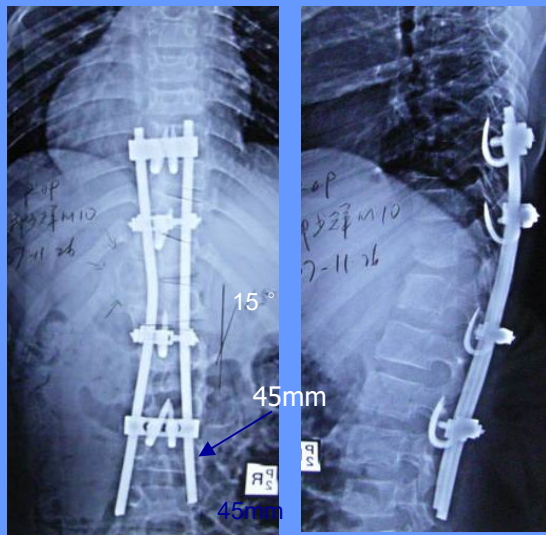


- **RESULTS:** The mean follow-up period was  $37.25 \pm 22.24$  months. The scoliosis curve was corrected from average  $55.06^\circ \pm 25.68^\circ$  preoperation to  $21.25^\circ \pm 15.51^\circ$  post-op with corrective rate 60.5%, and in the latest follow-up, the Cobb angle was  $24.38^\circ \pm 16.44^\circ$  compared with immediate postoperative angle, there was no significant differences ( $P > 0.05$ ), indicating no significant loss of correction. No complication of neurological deficit was found in our series.

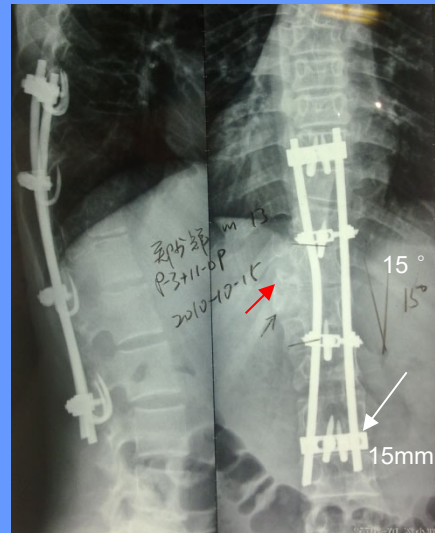


Zhen x h M 10  
with T12 HV  
scoliosis 40 ° ,  
The combined  
method was used  
to enucleate  
cancellous bone of  
the hemivertebra  
body & fixed with  
PRSS,  
Scoliotic curve  
was corrected  
40° ⇒ 15° P-op ⇒  
15° (p-3+11) p-op,  
instrumented  
spinal column  
growth 30mm.  
after op.

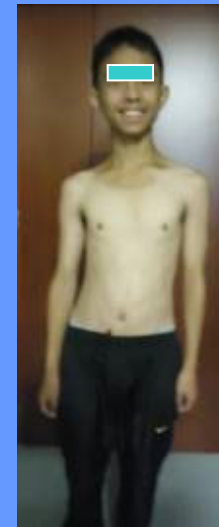Zhen x h M 10 with T12 HV scoliosis 40 ° ,



.p-op, scoliosis 15 ° 2007-11-16



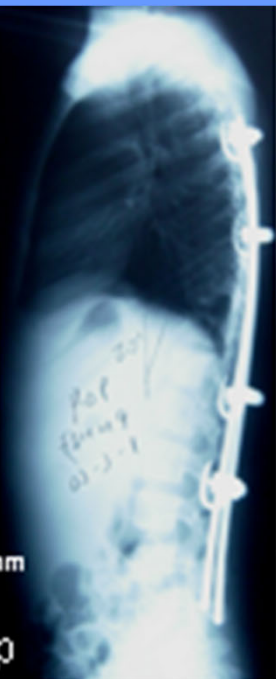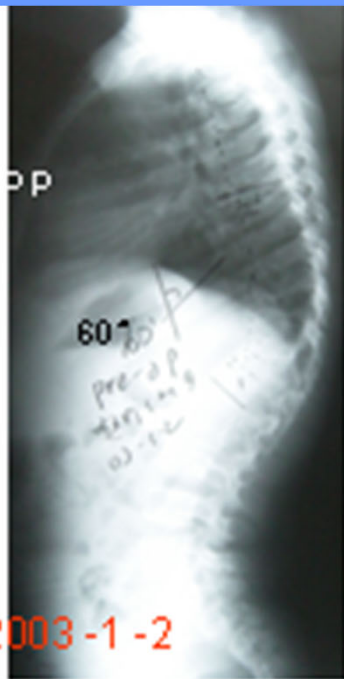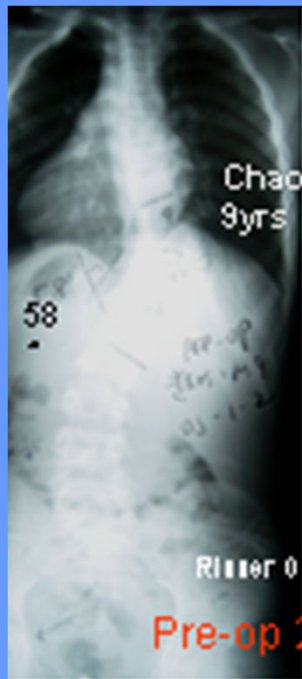P-3+11 op, 2011-10-11, scoliosis  
15 ° . bony fusion appears  
around the area of Hv (↗ )



## Discussion

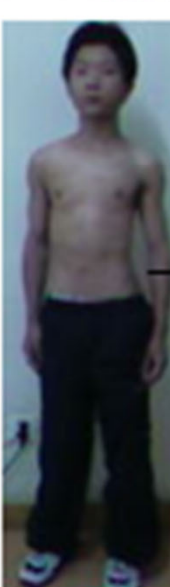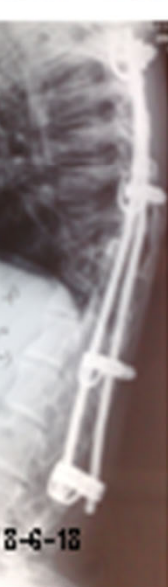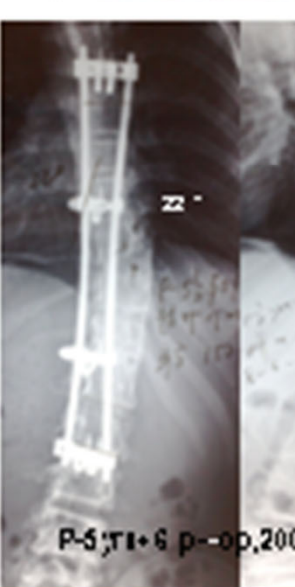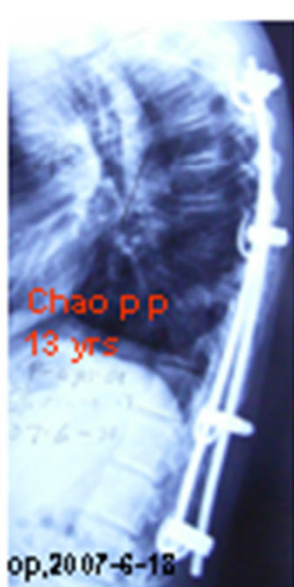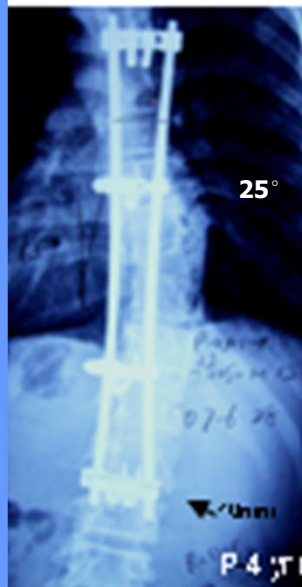
- Recent studies :Several papers (Ruf et al /Mikles et al..... ) reported transpedicular hemiepiphysiodesis(eggshell technique) and posterior instrumentation to treat hemivertebral scoliosis . Their major effect is to eliminate the growth potential of the offending HV. But a number of reinterventions revealed curve progression despite HV resection. That suggested **we need further continued correction mechanism for those cases in the later growing years.**
- we combined use of transpedicular enucleating which offers advantage of an one-stage, one approach operation **to eliminate the growth potential of the offending HV.** and PRSS was used to extend the corrective level including 2 to 3 segments above and below the HV **to maximum spontaneous correction after operation.** PRSS with its special design will provide modulating efficiency in normalizing the spinal growth and gradual realignment of the spine curvature in the later growing period ,good results was obtained.





Chao P P M 9 yrs, with T9 HV congenital scoliosis, posterior resection of hami-vertebrae & PRSS, curve correction: 58°

→ 40° (P-op) →  
22° P5yrs+6 op),



Growth of instrumented segments was 5cm. (from 66mm to 10mm)

## CONCLUSION:

- Combined use of transpedicular enucleating and PRSS fixation is a safe and effective method for the management of HV scoliosis in one stage operation in growing children.
- The desirable correction was abtained and maintained in growing year after one stage operation due to the efficiency of **modulating the asymmetrical spinal growth** provided by PRSS.



谢谢！ Thank you!

