

# **Correction of L5 body wedging by bone remodeling during growing rod treatment**

**Nobumasa SUZUKI**

**Scoliosis Center, Medical Scanning Tokyo  
Tokyo, Japan**

**○ Katsuki KONO**

**Orthopedic Surgery, Eiju General Hospital  
Tokyo, Japan**

# Introduction

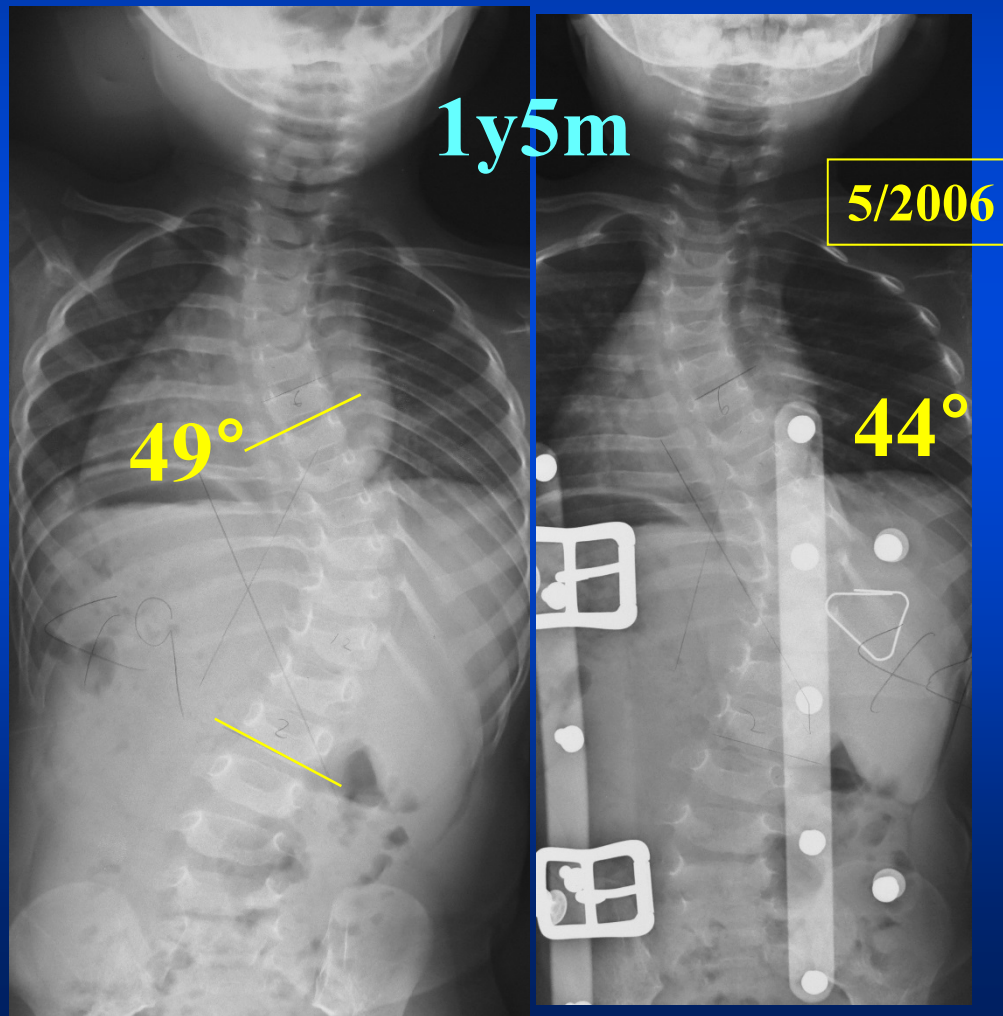
**This is a case report of the correction of L5 Body wedging, which occurred during Growing Rod Treatment, using a Lumbosacral Distraction Rod.**

**Application of a Lumbosacral Distraction Rod without fusion resulted in successful treatment.**

# Case: Female, Idiopathic Scoliosis

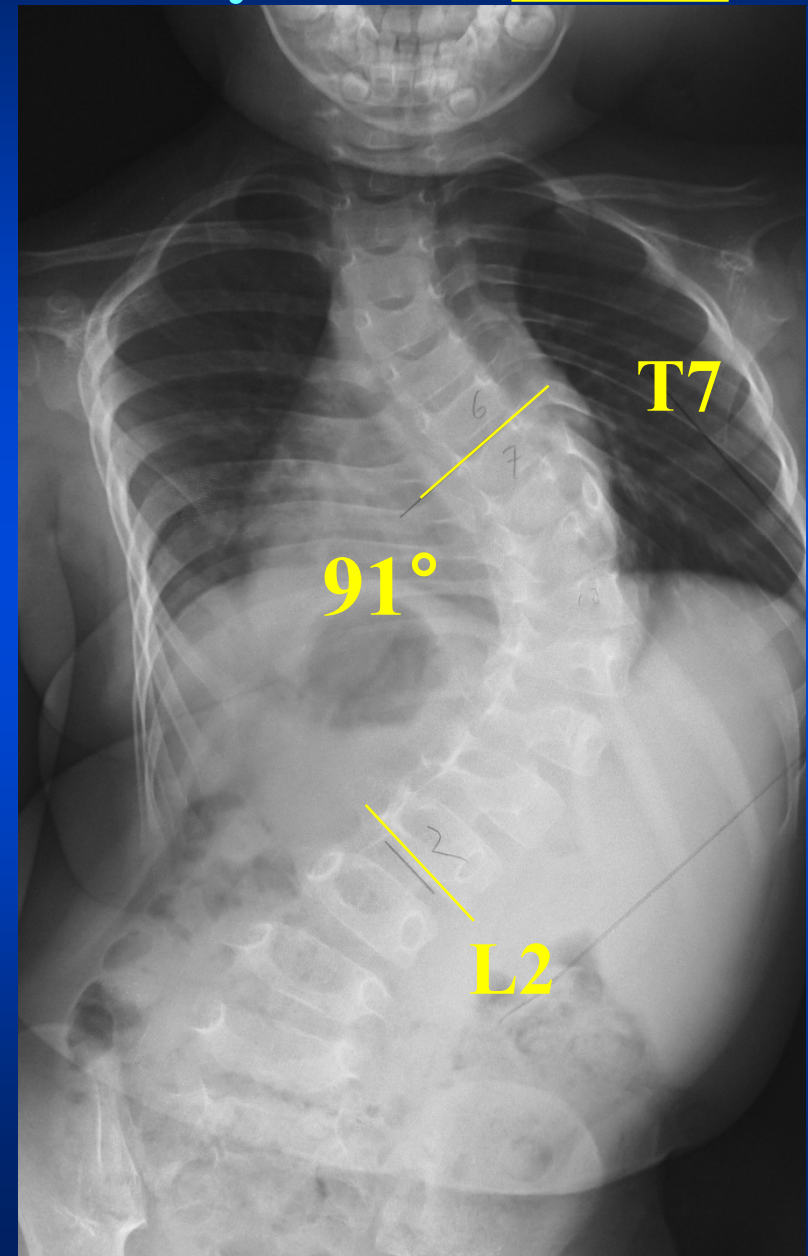
1y3m at First visit

Starting Brace Treatment



2y9m

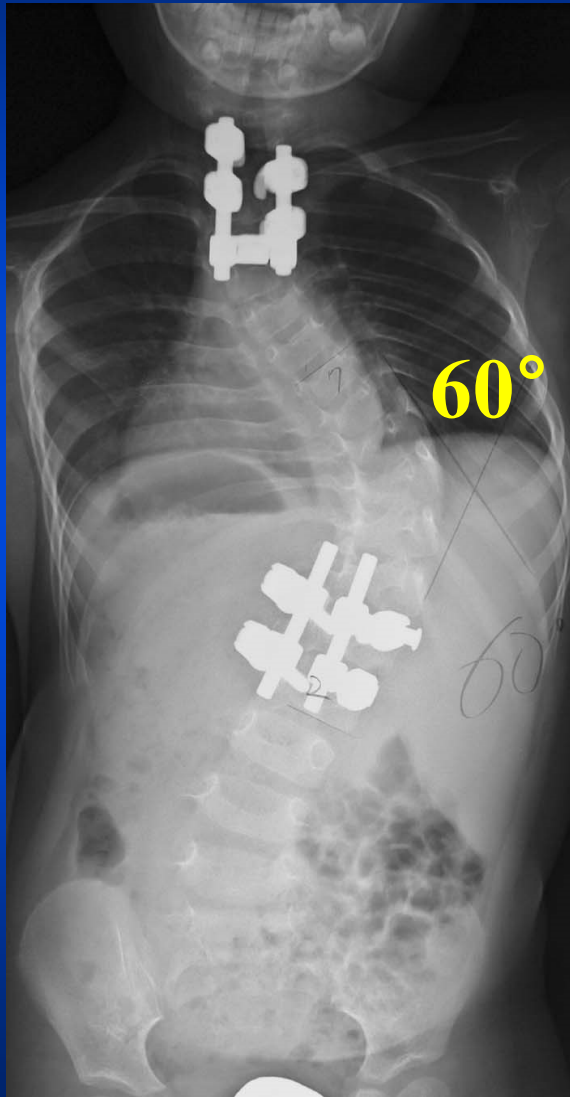
10/2007



2y9m

10/2007

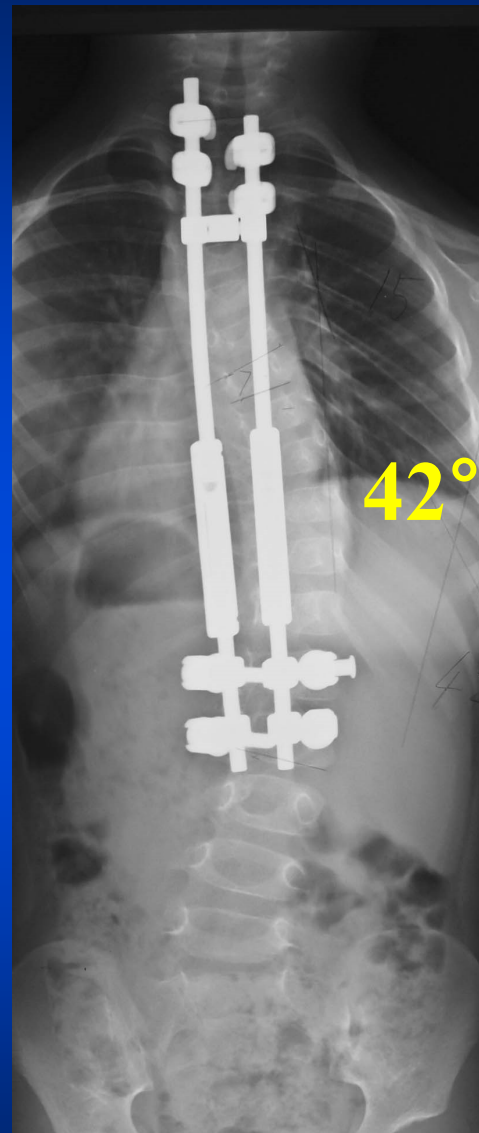
# Starting Growing Rod Tx



Op. #1 : Foundation

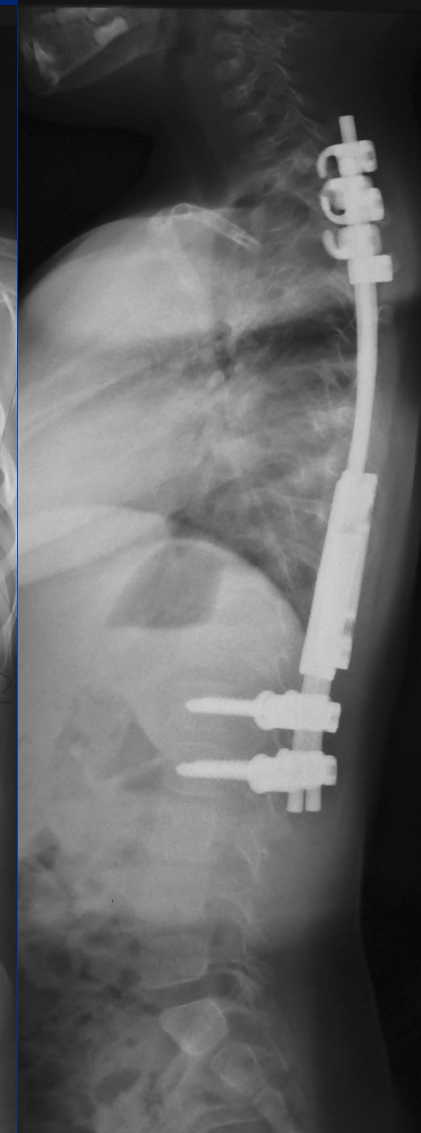
3y2m

2/2008



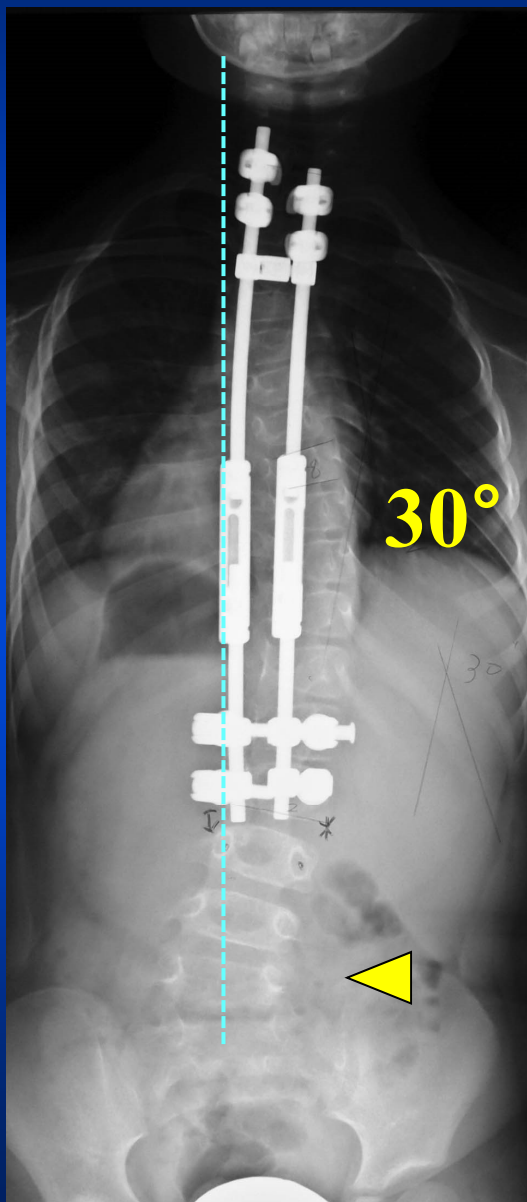
Op. #1 post 4m

Op. #2 : Growing Rod Insertion



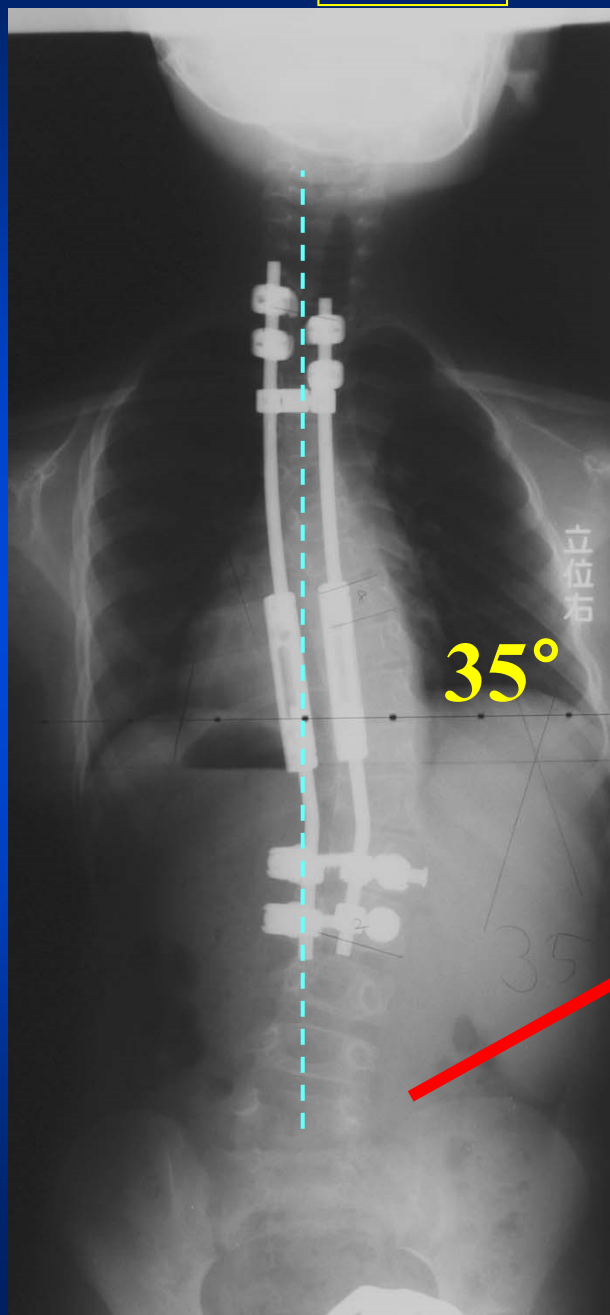
4y7m

7/2009

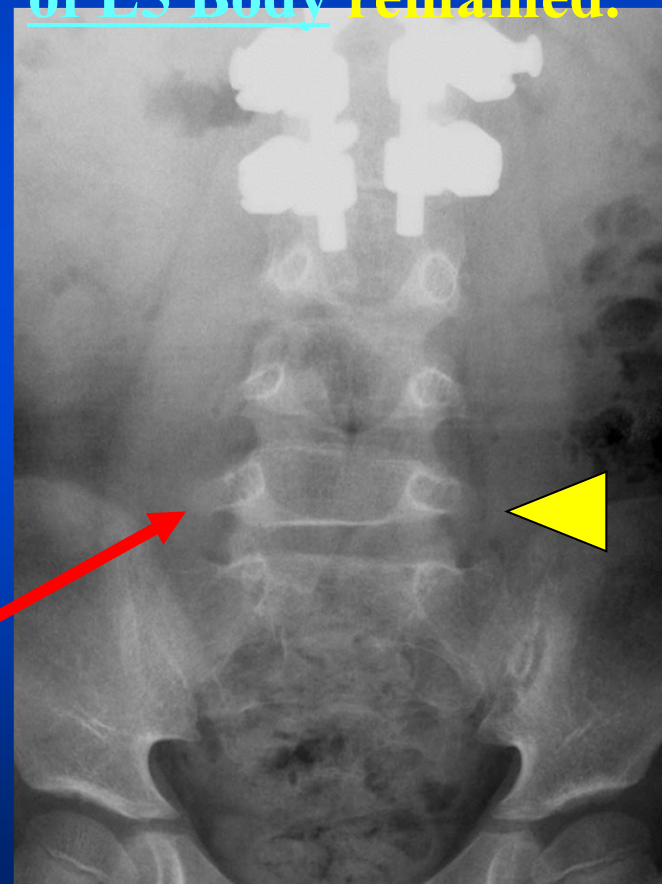


5y3m

4/2010

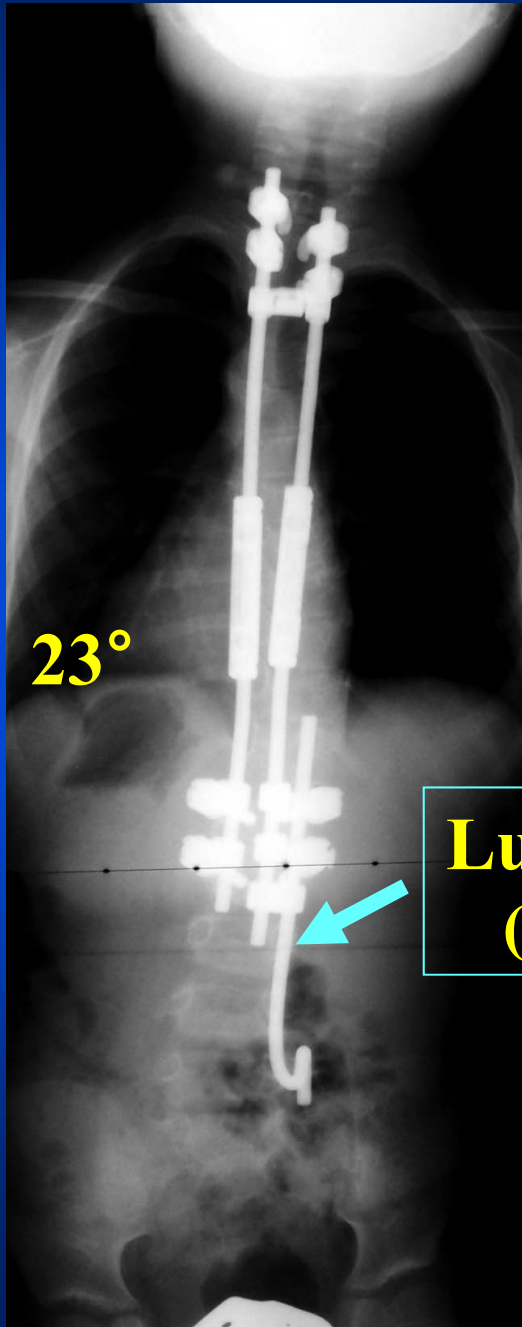


Coronal Off Balance was corrected by rod bending, but Wedge Deformity of L5 Body remained.



5y3m

4/2010



23°

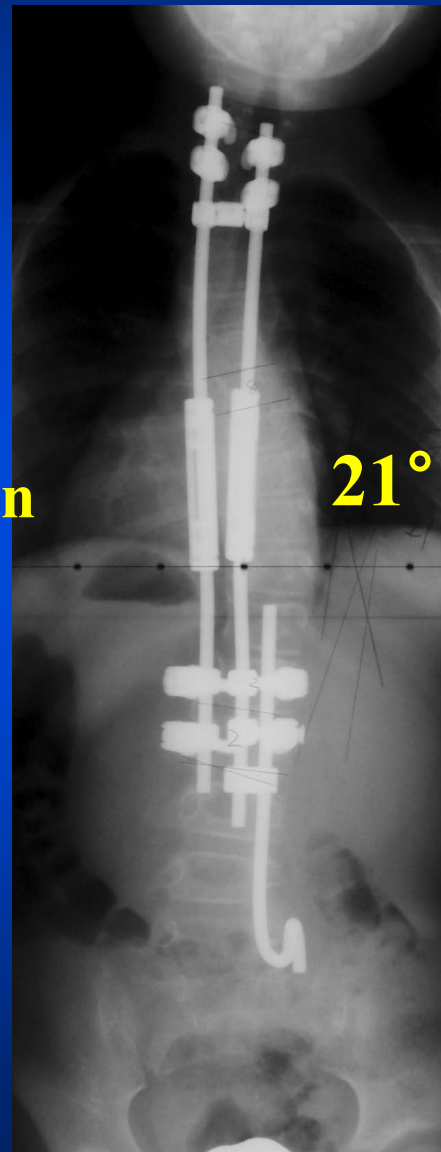
Op. #6

Distraction Force  
was applied between  
L2 and S1.

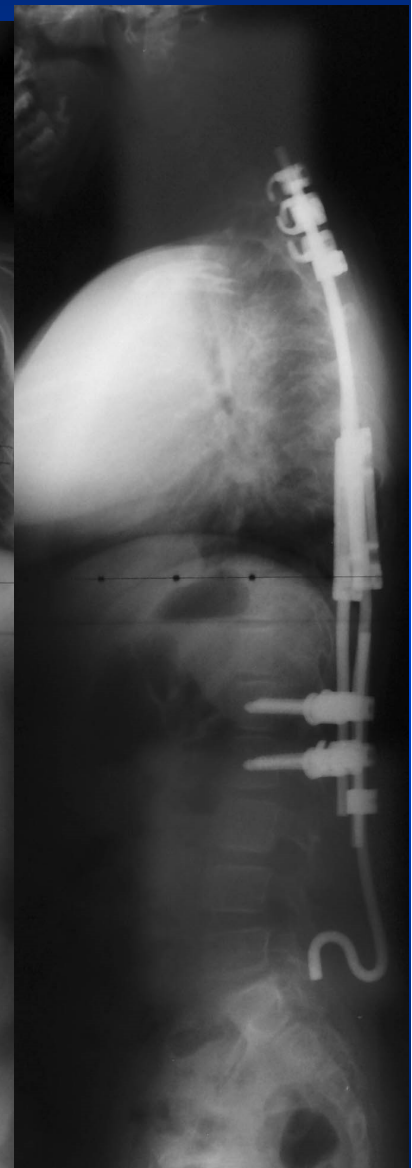
Lumbosacral Rod  
(McCarthy type)

6y1m

1/2011

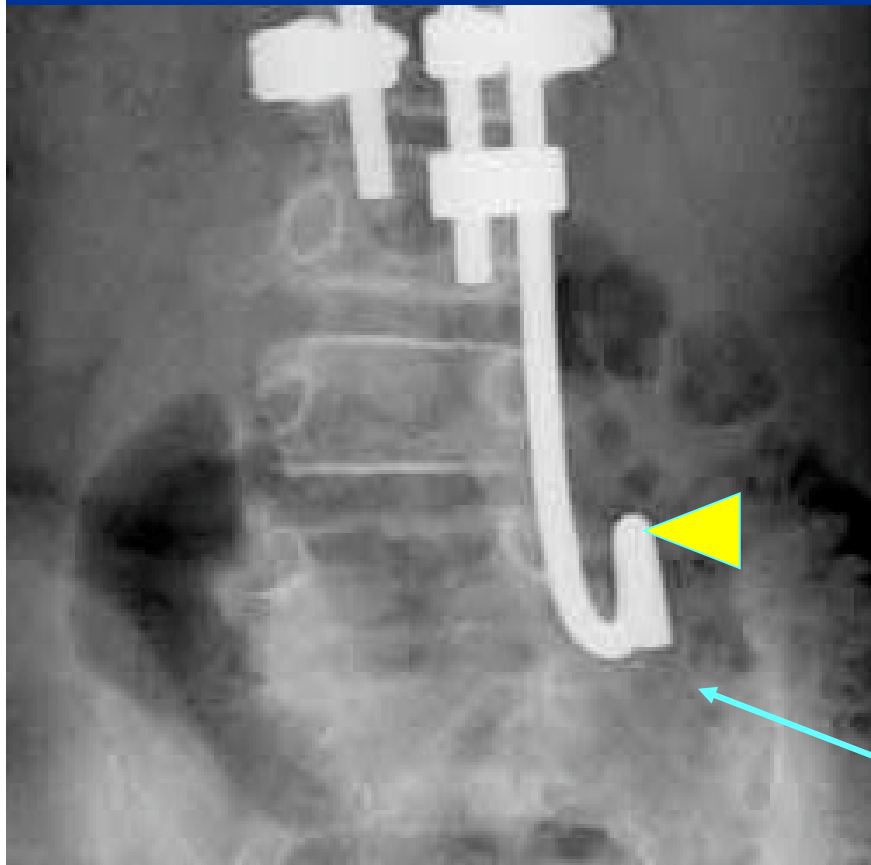


21°

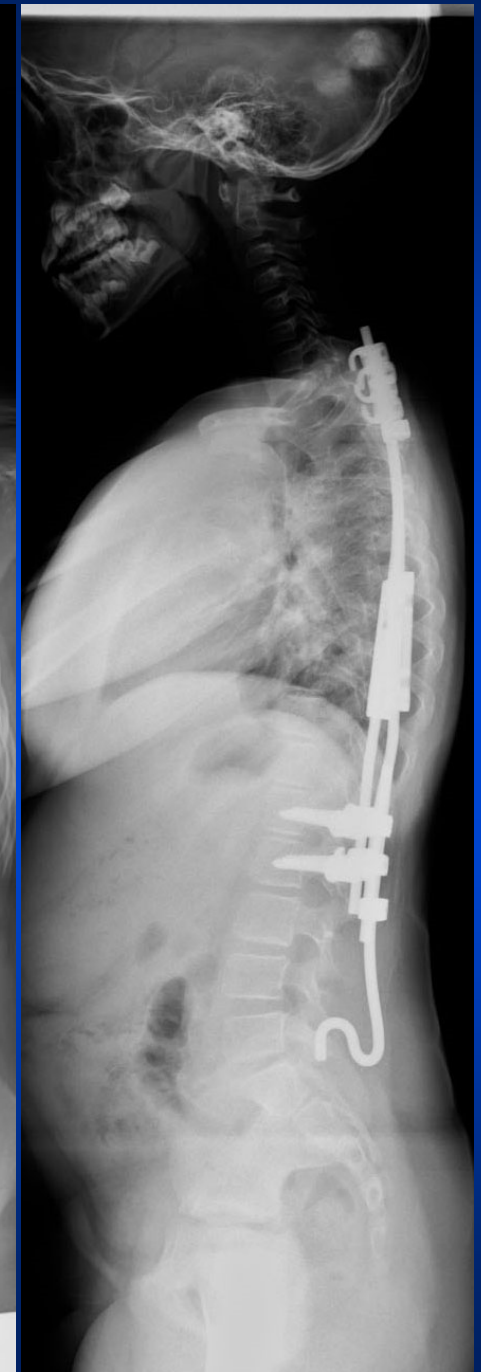
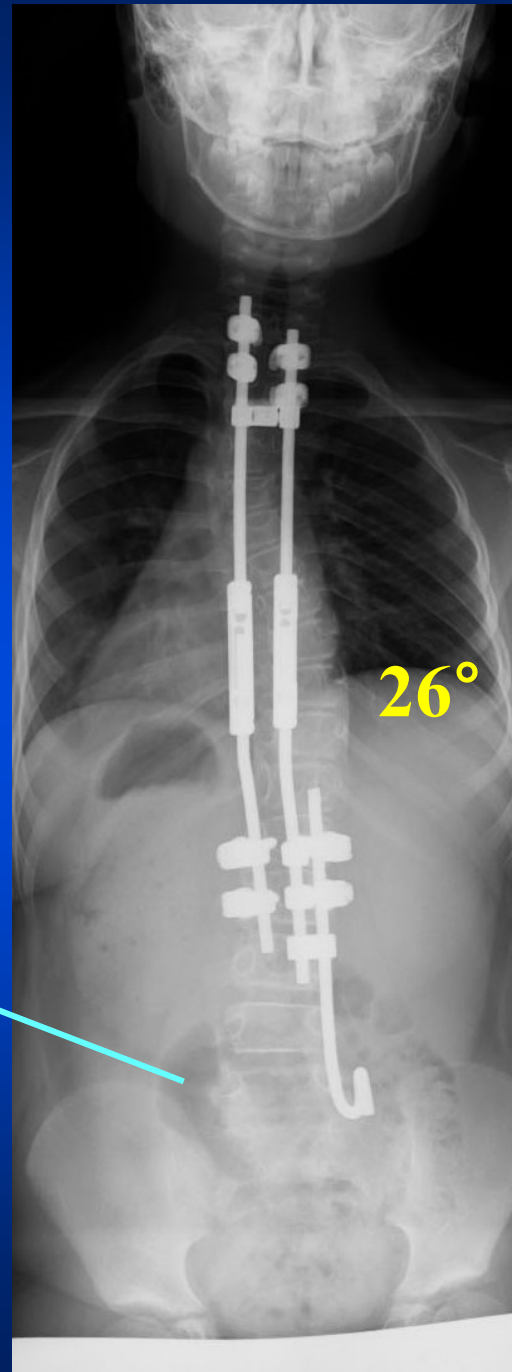


7y7m

7/2012



**Remodeling of L5 Body  
had occurred.**

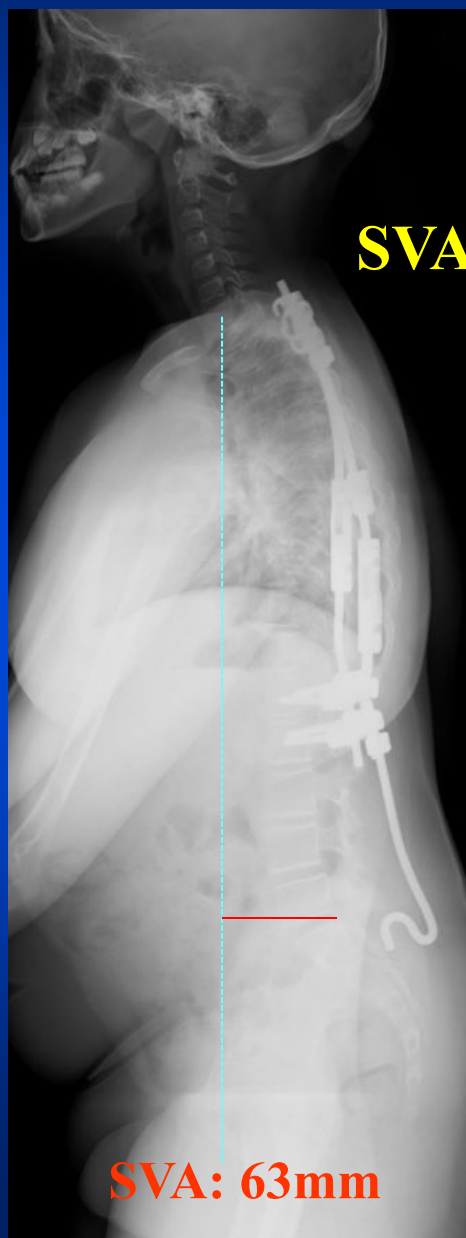


9y1m

1/2014

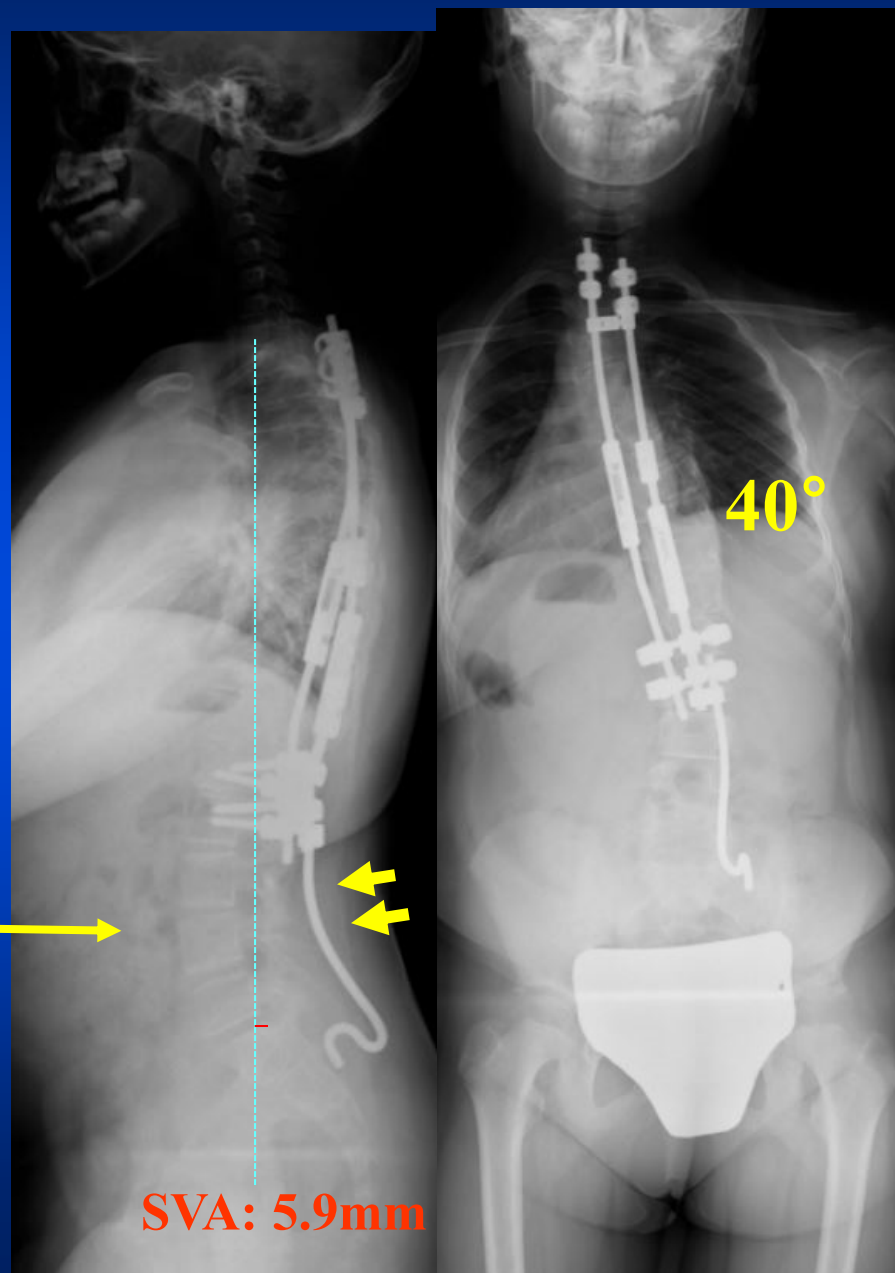
9y6m

6/2014



**SVA moved forward.**

**The lumbosacral rod was bent into a more lordotic contour**

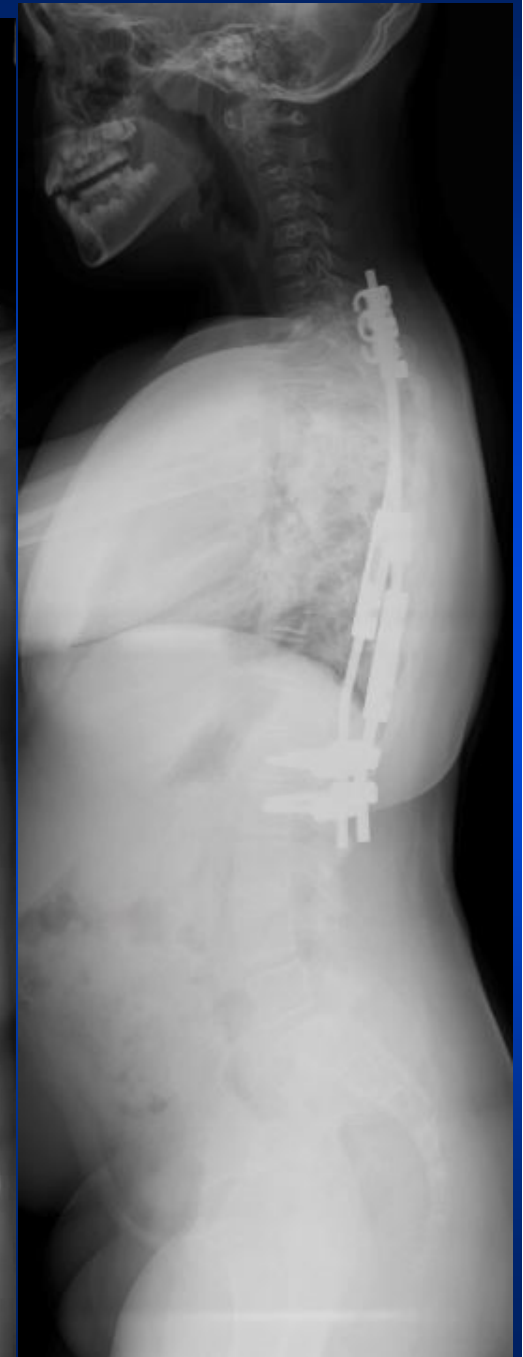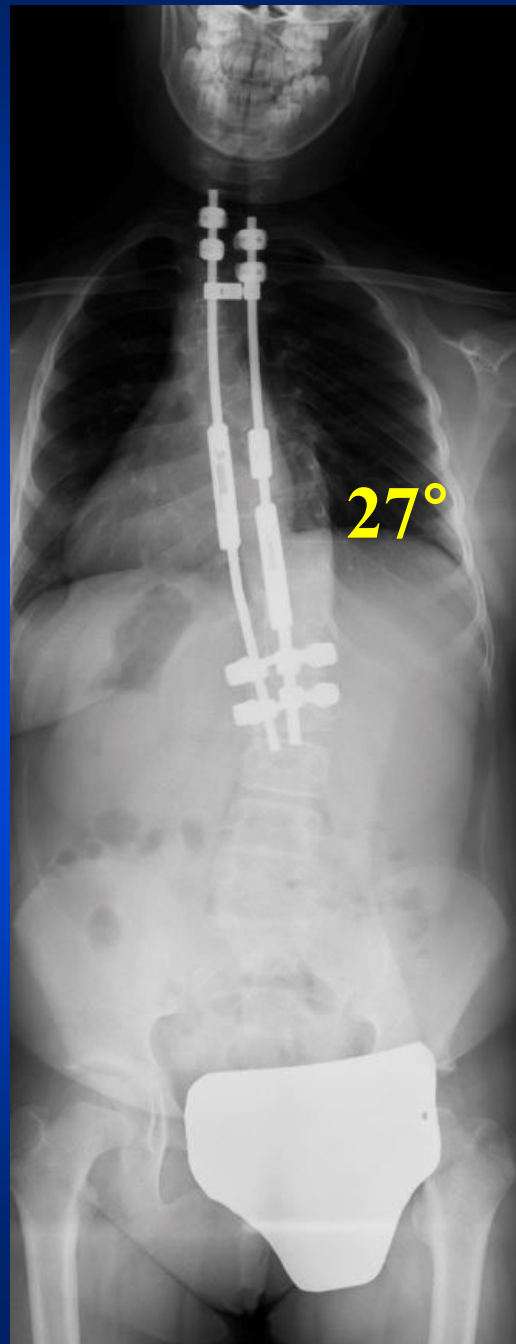
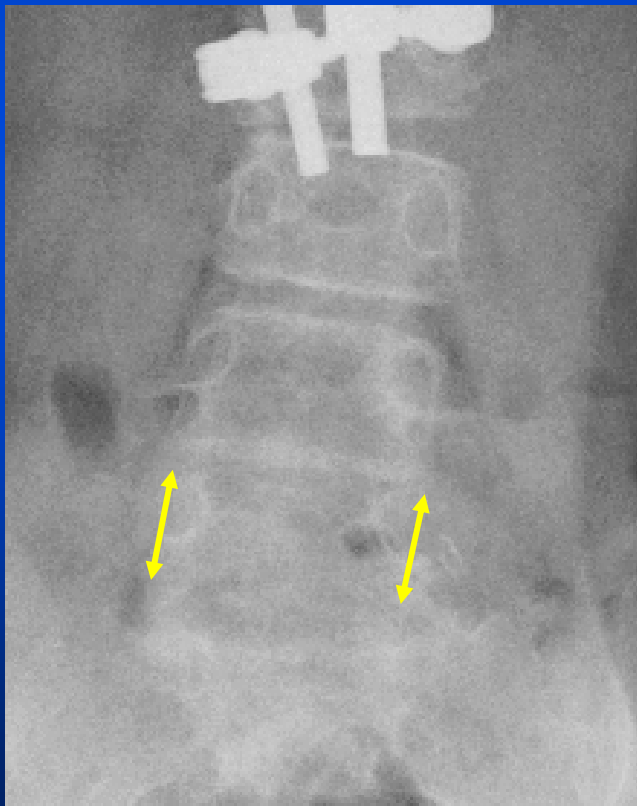




8/2014

Age: 9y8m

Op. #12:  
Removal of Lumbosacral Rod.  
Post-op 1m.



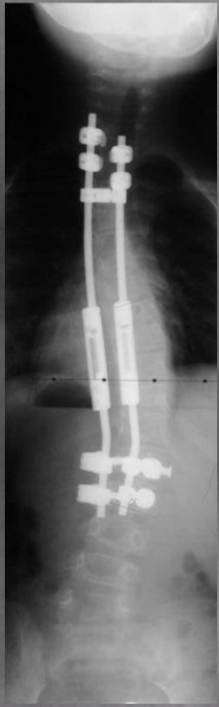
# Discussion

Vertebral wedging deformity of the lumbar spine is the most resistive factor against correction of lumbar scoliosis, independent of whether it is a compensatory or a primary curve. It is, therefore, the authors' opinion that every effort must be taken to avoid such deformity.

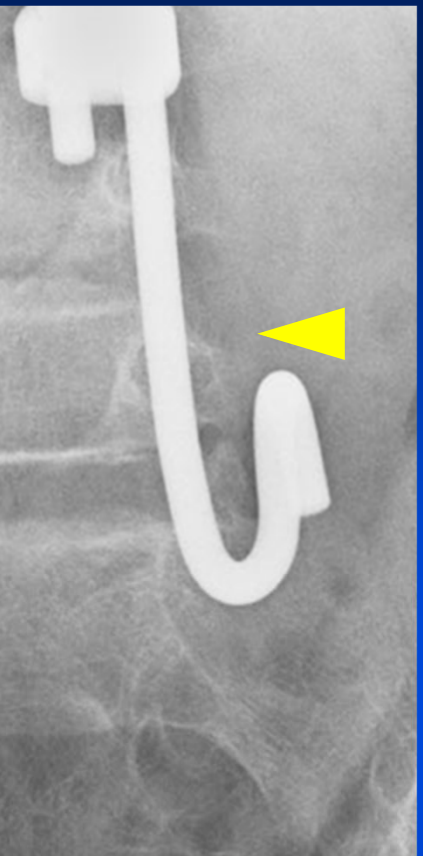
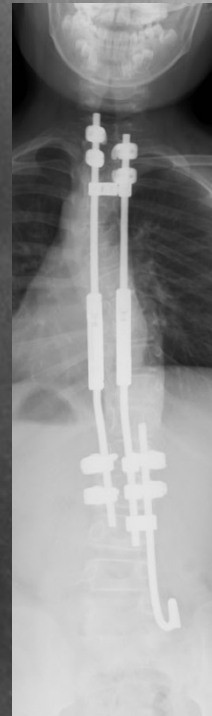
The case presented here still has a significant body list towards the left due to L2-L3 disc wedging after removal of the lumbosacral rod. We believe this can be managed by extending the instrumentation without fusion to L3.

Her VC and %VC are 1.94l and 99.5%, respectively, at this stage.

5y3m



7y9m



- **This case showed a possibility of normalizing vertebral body wedging treated by application of distraction force inducing bone remodeling.**
- **Intervention should be done while there remains large growth potential.**

# Conclusion

- **We experienced wedged deformity of L5 body which had occurred during Growing Rod Treatment.**
- **By applying a distraction force to deformed vertebra, remodeling to normal shape occurred.**
- **We should give closer observation on lumbar body wedging to prevent or correct it in the treatment of growing children.**