

Case Presentation

ICEOS Pre-course

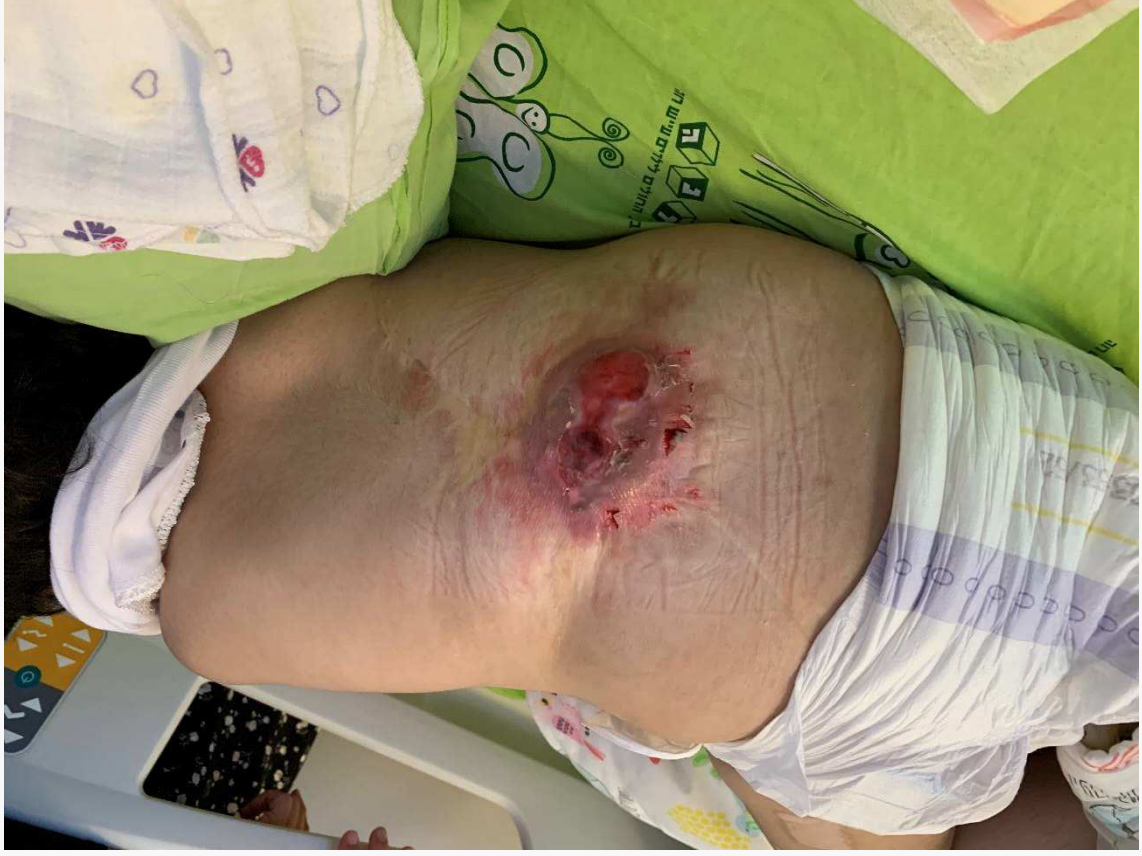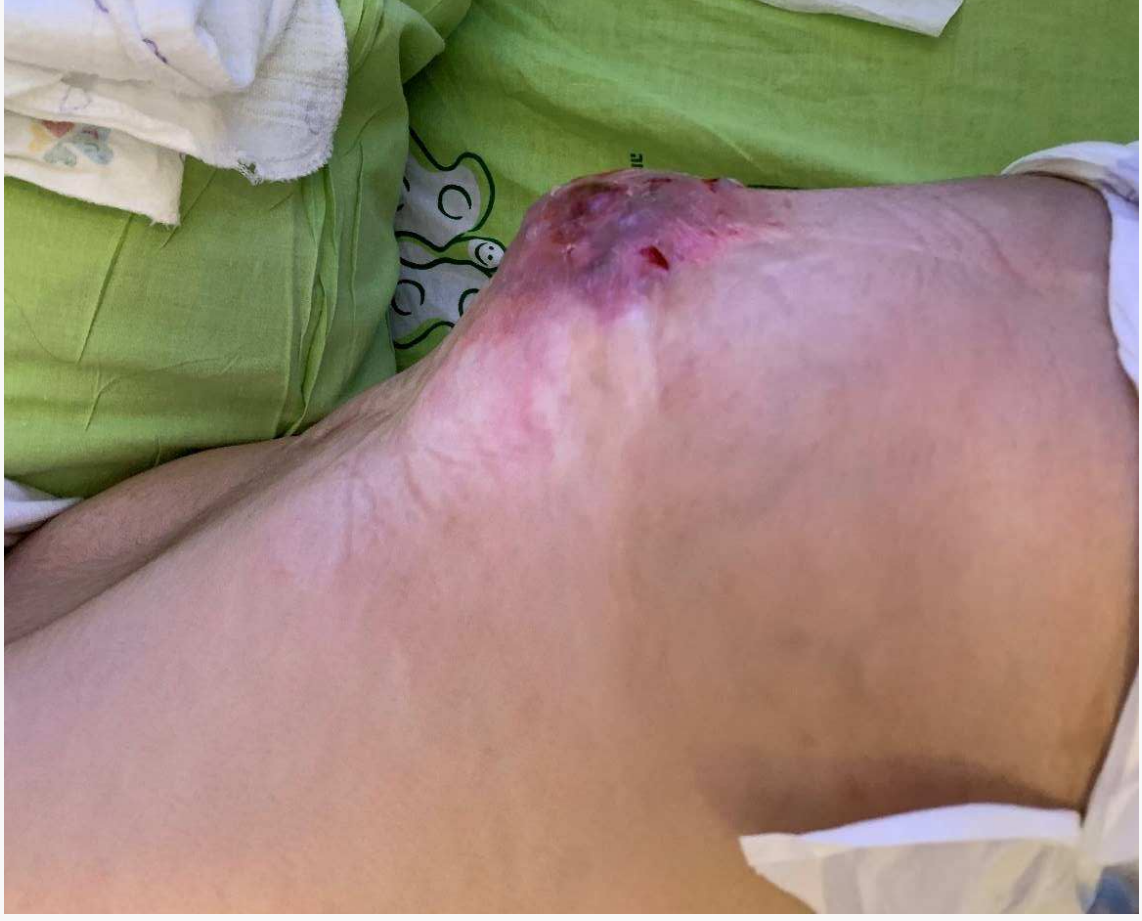Atlanta 2019

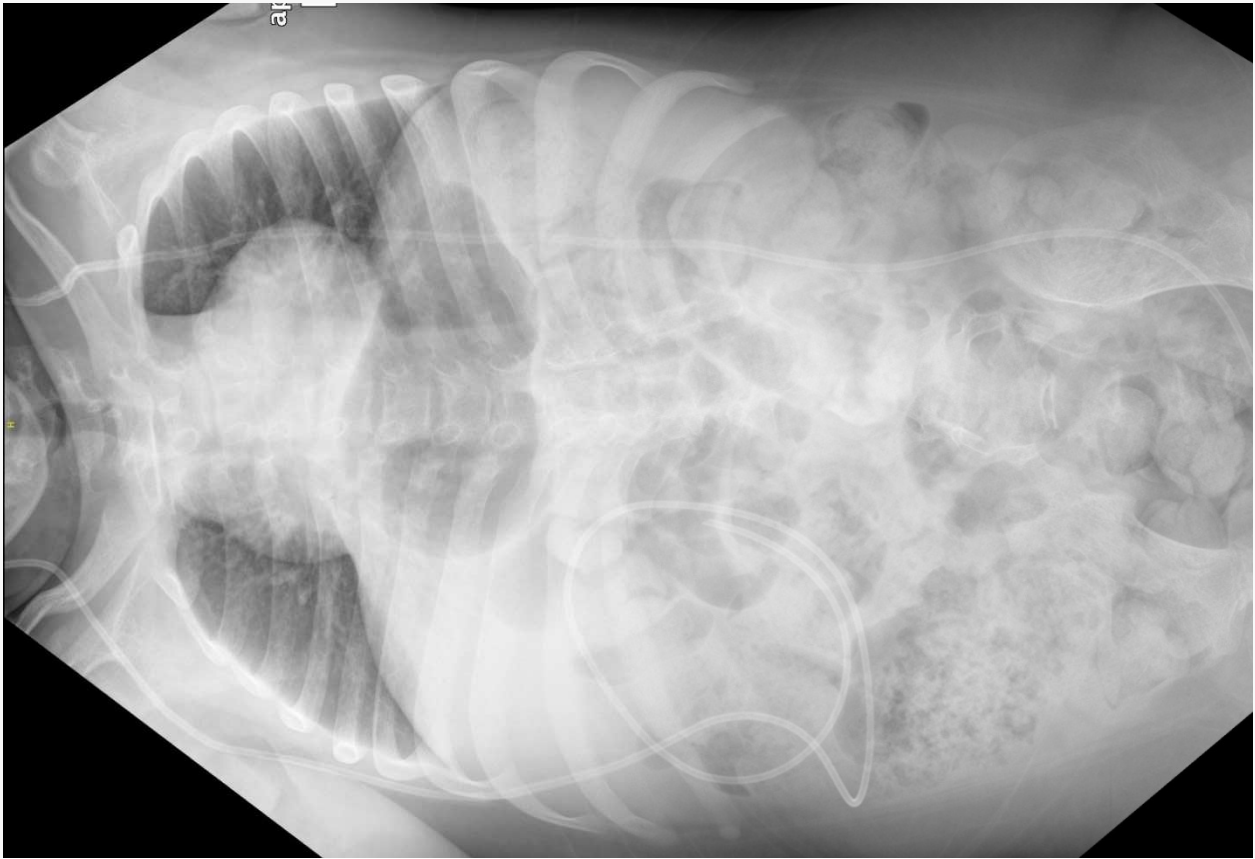
Dror Ovadia, M.D.
Department of Pediatric Orthopaedics
Dana Children's Hospital
Tel-Aviv Sourasky Medical Center
Tel-Aviv, Israel

Disclosures

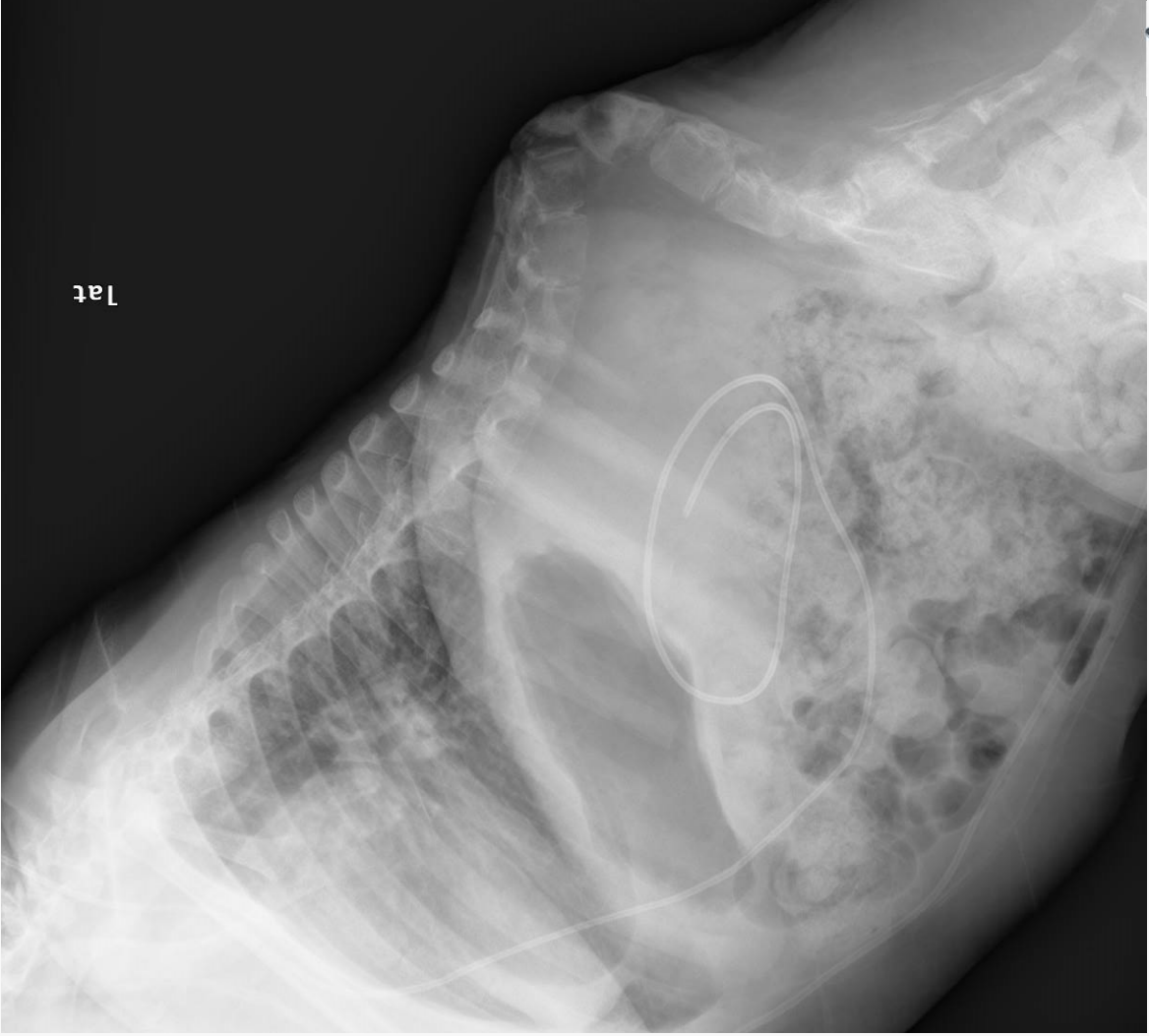
- None

- M.R, 7y , girl
- MMC
- Paraplegia from D8
- V-P shunt
- Closure of MMC by Neurosurgeon as newborn left many scars at the lumbar region
- Severe and **rigid** Lumbar Kyphosis already causing pressure sores





ap

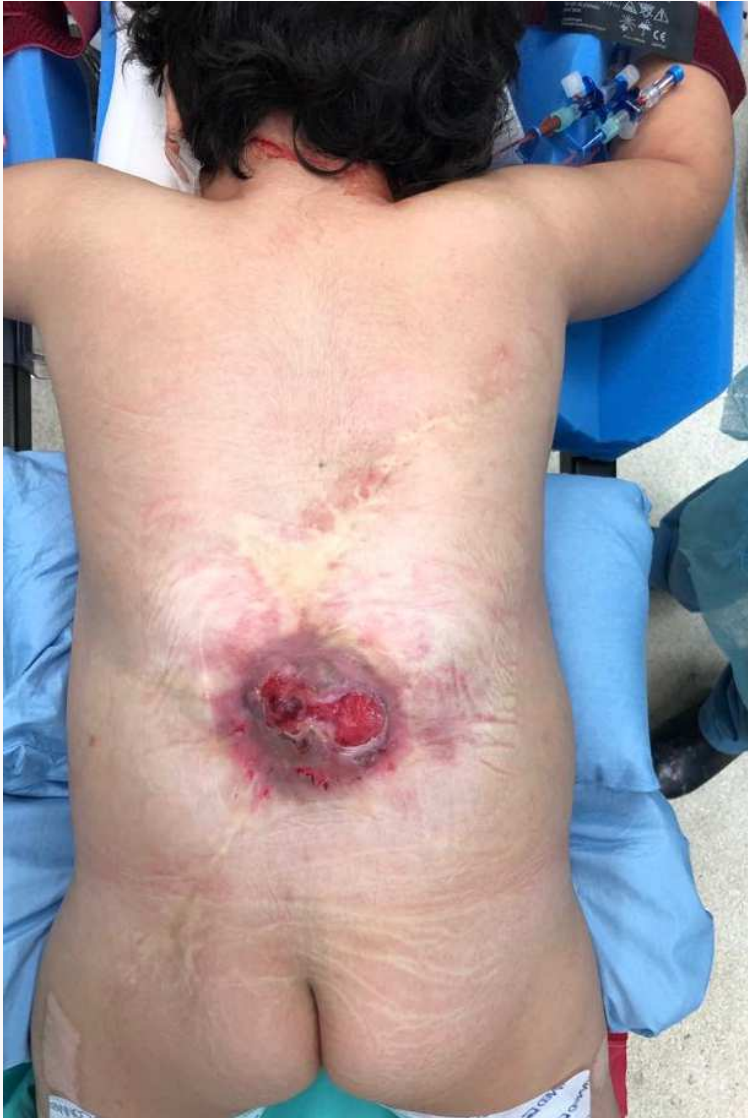

lat

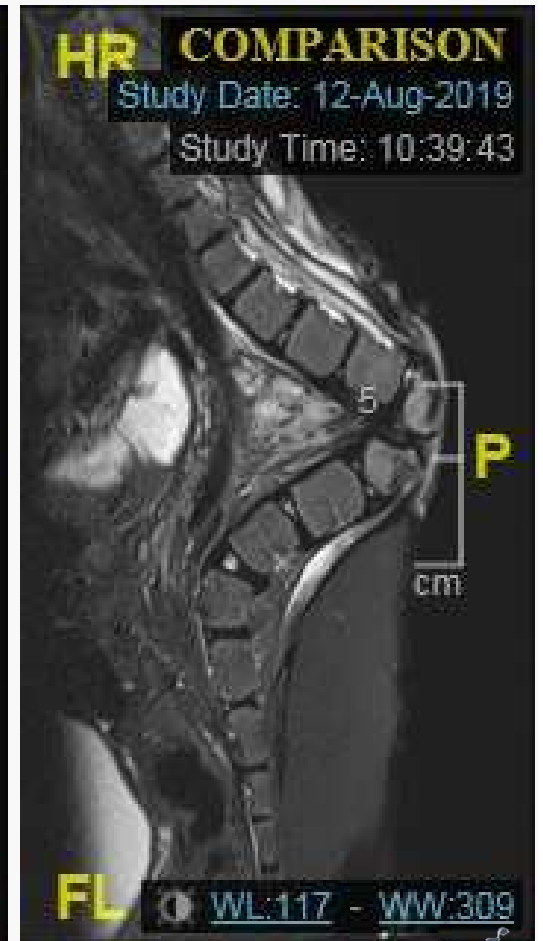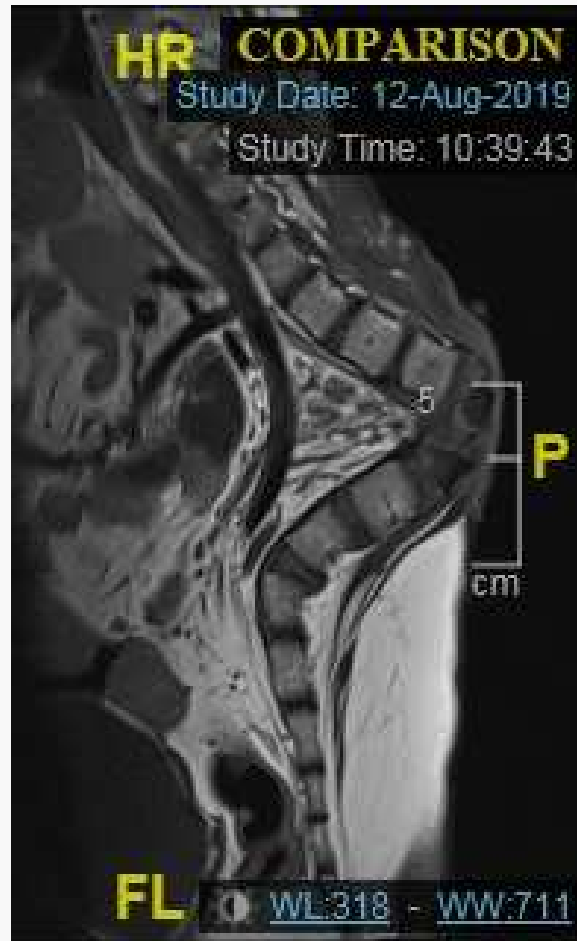
What to do?

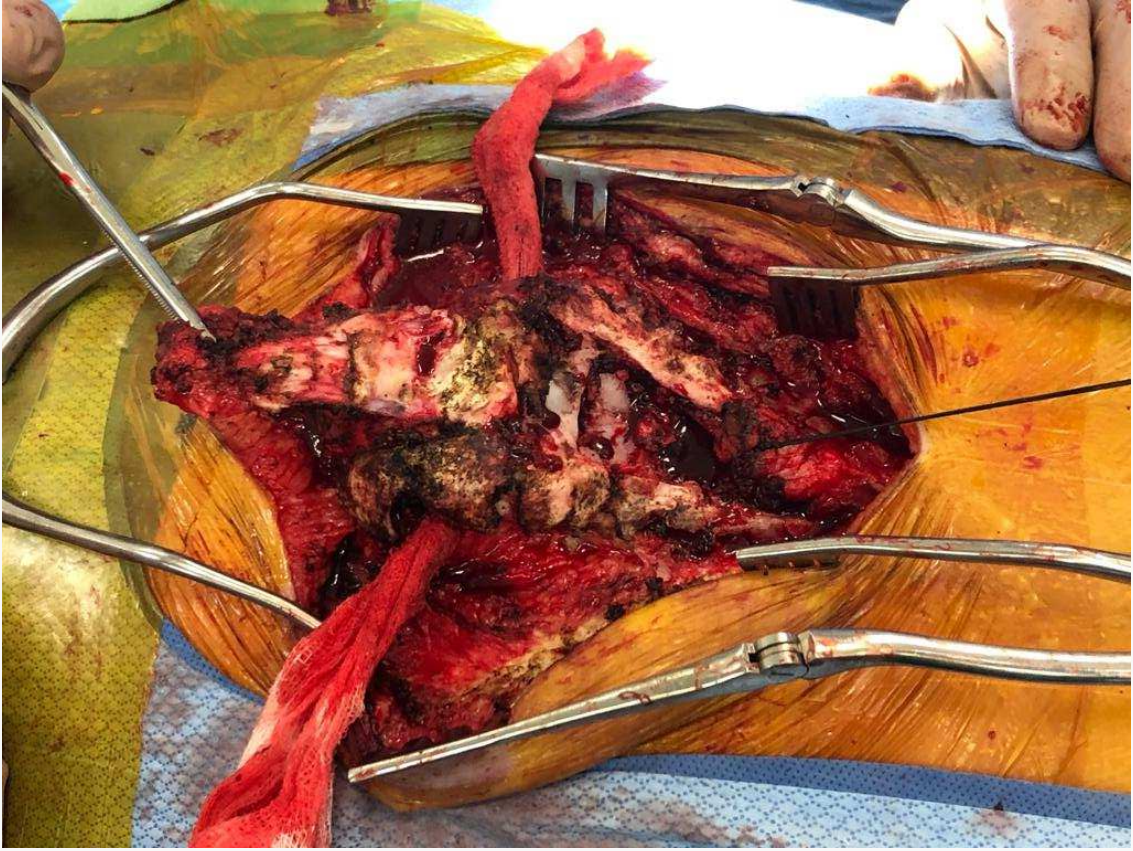
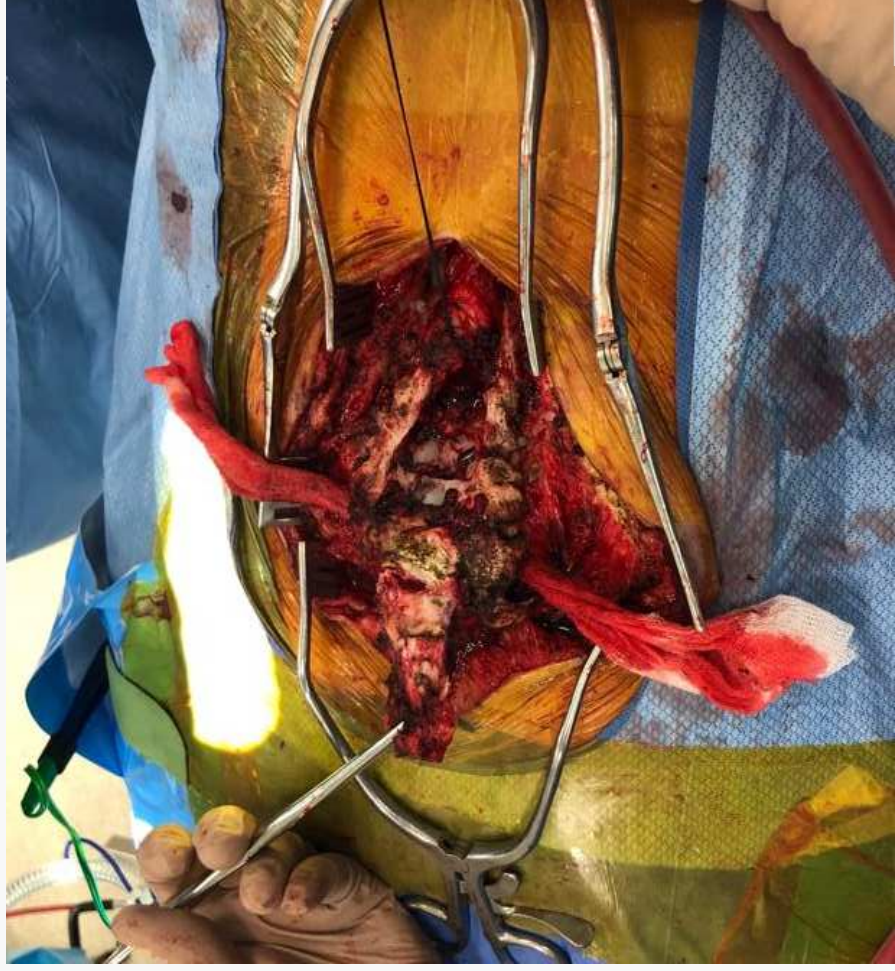- Dual rib to pelvis VEPTR device?
- Growing rods to sacrum/pelvis?
- Primary resection of apical vertebrae with short fusion?
- Insert skin expansions prior to surgery?

Skin closure failed after 3 attempts

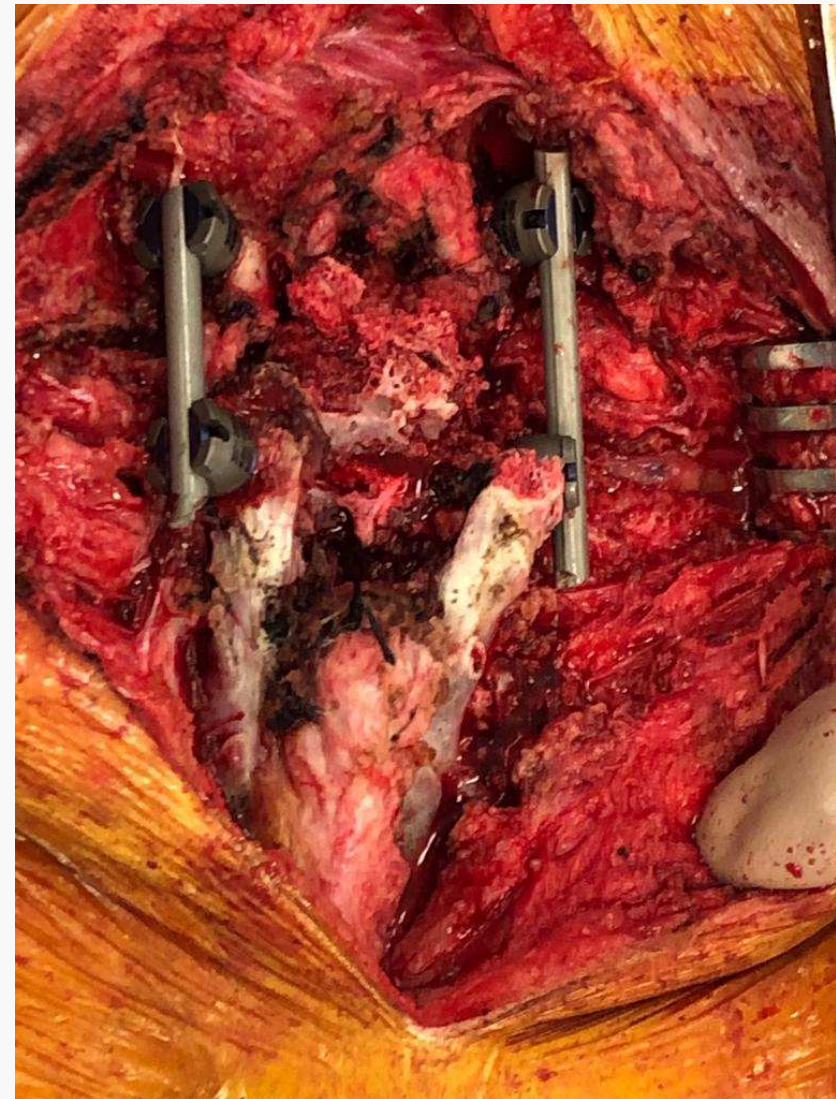
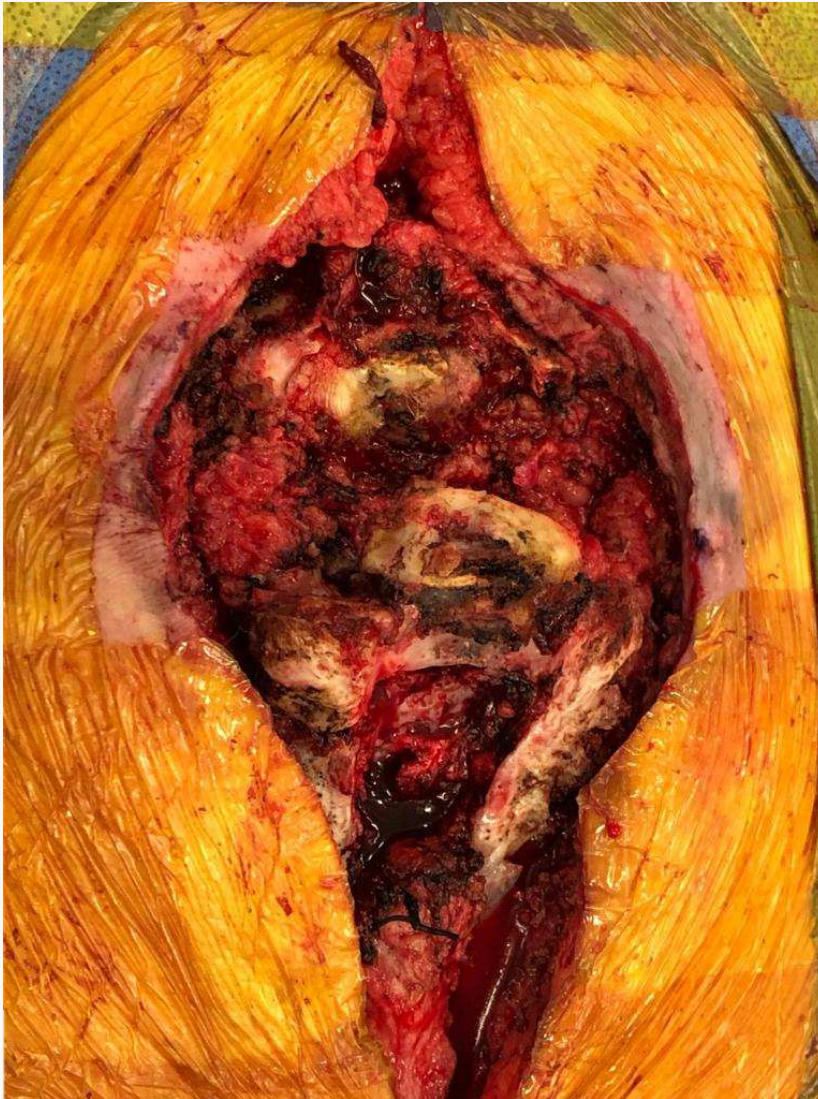

Clear signs of Chronic Osteomyelitis

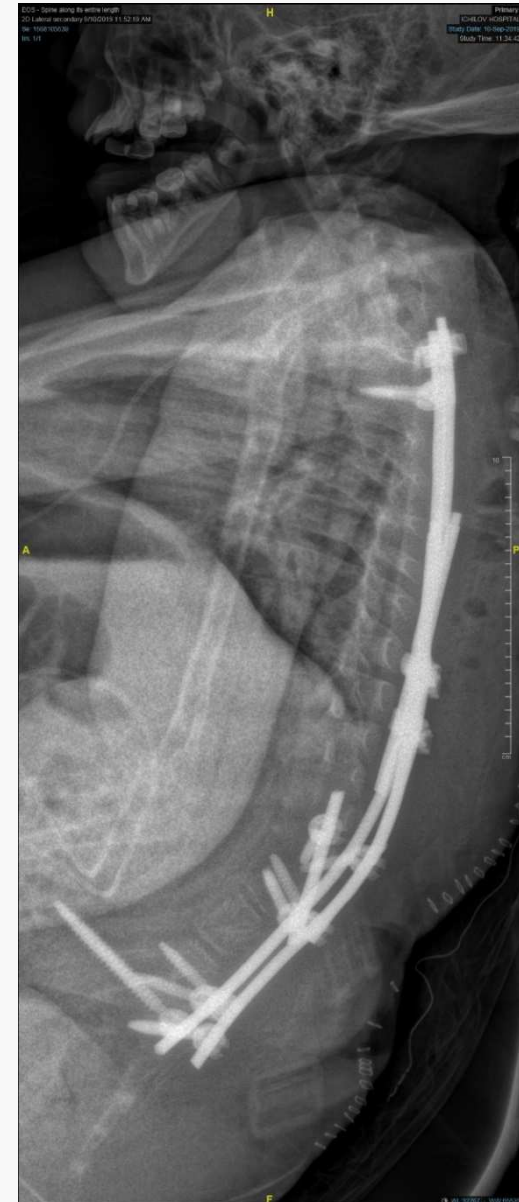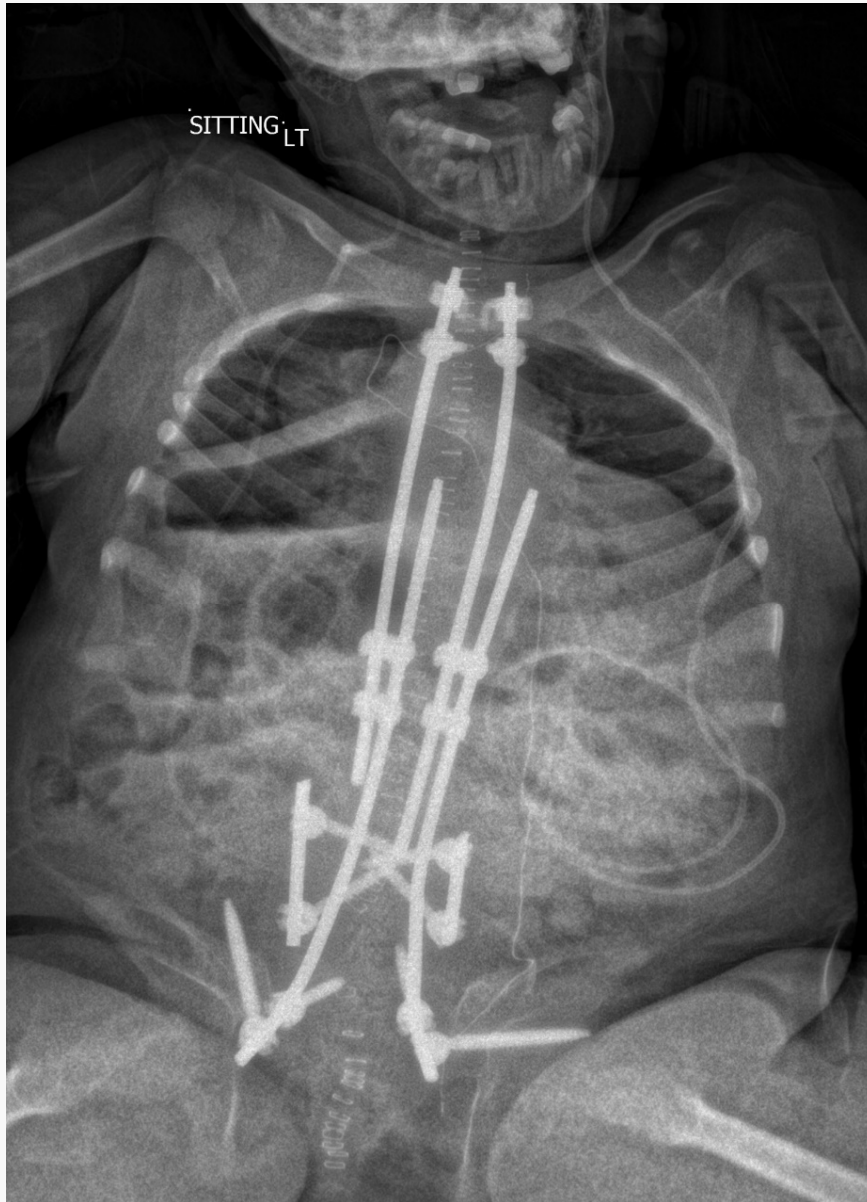




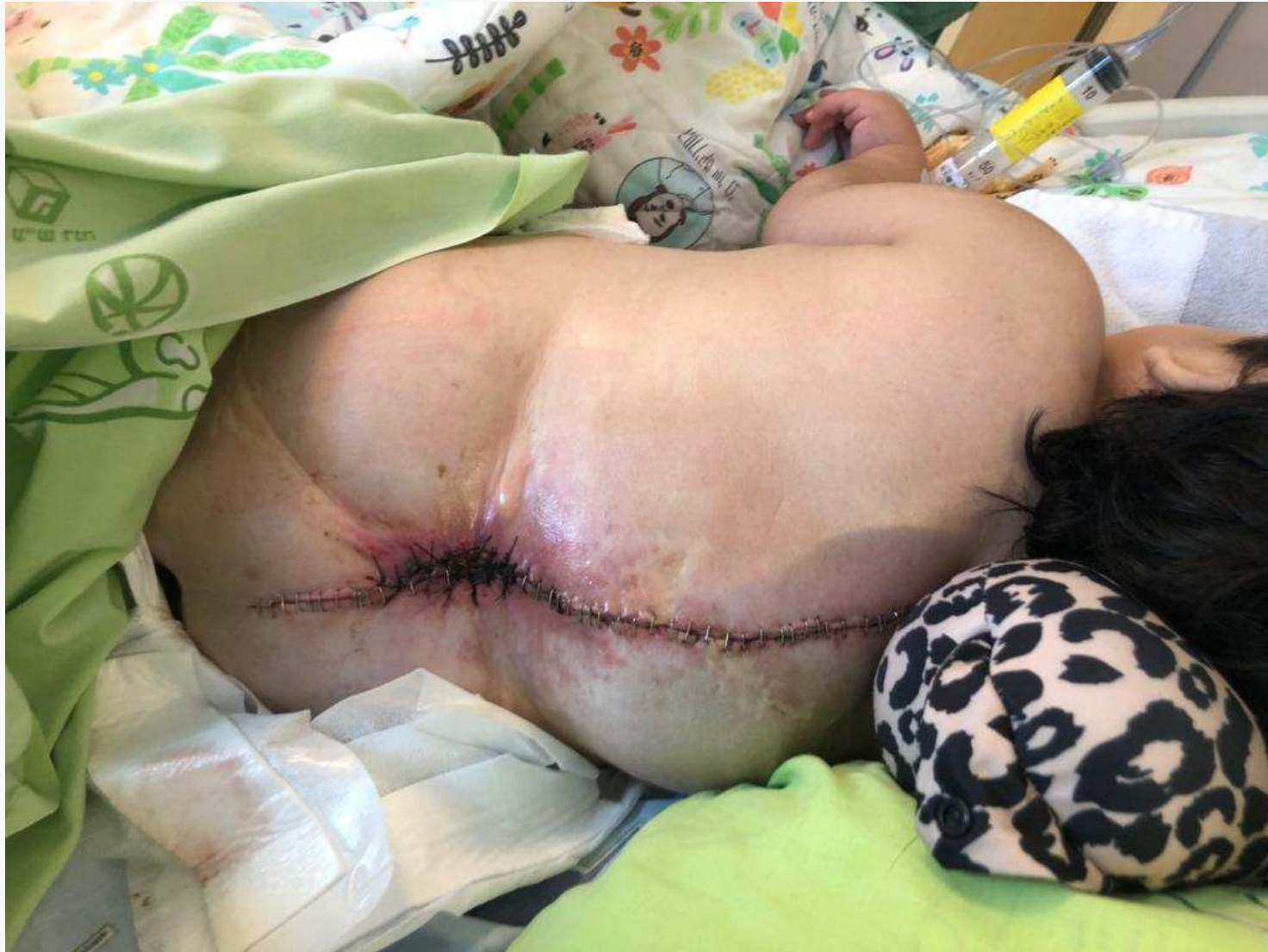Resection of 2.5 vertebrae (OM) short fusion



TGR – T1\2 to Pelvis



Primary skin closure



Thank you

