



**Revision surgeries after posterior hemivertebra resection
with short segmental fusion for congenital scoliosis in
young children--More than 10 years follow-up**

Jianguo Zhang Shengru Wang
Peking Union Medical College Hospital
Beijing China



No disclosures



Background

Posterior hemivertebra resection in younger age

➔ Removal of the pathology

Correction of the local and compensatory deformities

➔ Short fusion

Limited influences on the growth of spine

Saving mobile segments

Lack of long-term results!

Ruf M. Spine 2009

Zhang JG. Euro Spine J 2011

Wang SR. Euro Spine J 2012



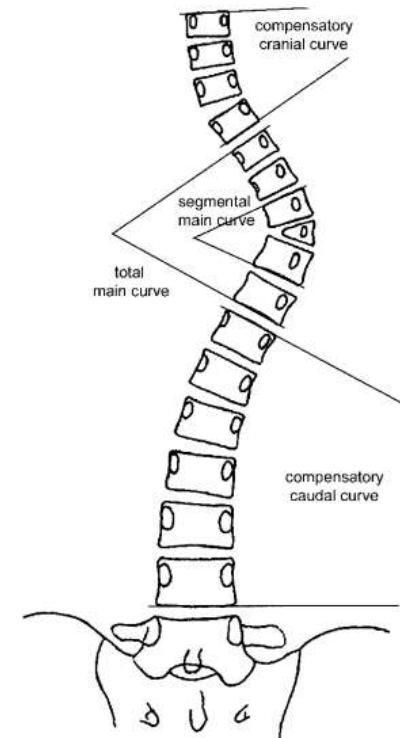
Purpose and Methods

➤ Retrospective study

Long-term results of posterior hemivertebra resection with short fusion

➤ Radiographic measurements

- ✧ Segmental scoliosis; Whole scoliosis
- ✧ Segmental kyphosis; Whole kyphosis
- ✧ Compensatory scoliosis
- ✧ Trunk shift
- ✧ SVA
- ✧ T1-S1 length



Clinical data

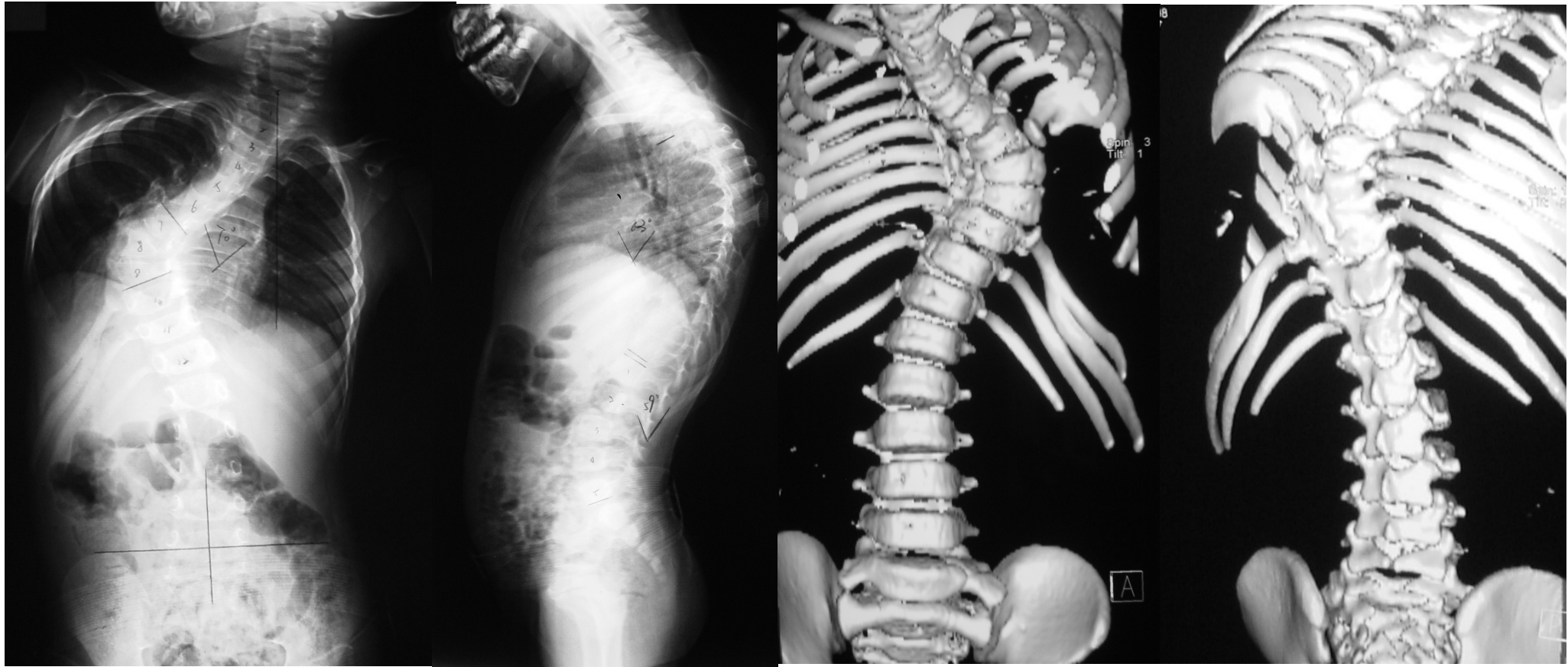Total number	57
M	35
F	22
Age at surgery (yrs)	5.2(3-9)
Age at the latest Follow-up	13.5(12-17)
Follow-up(yrs)	11.1(10-13)
Fused segments (levels)	2.6(2-4)



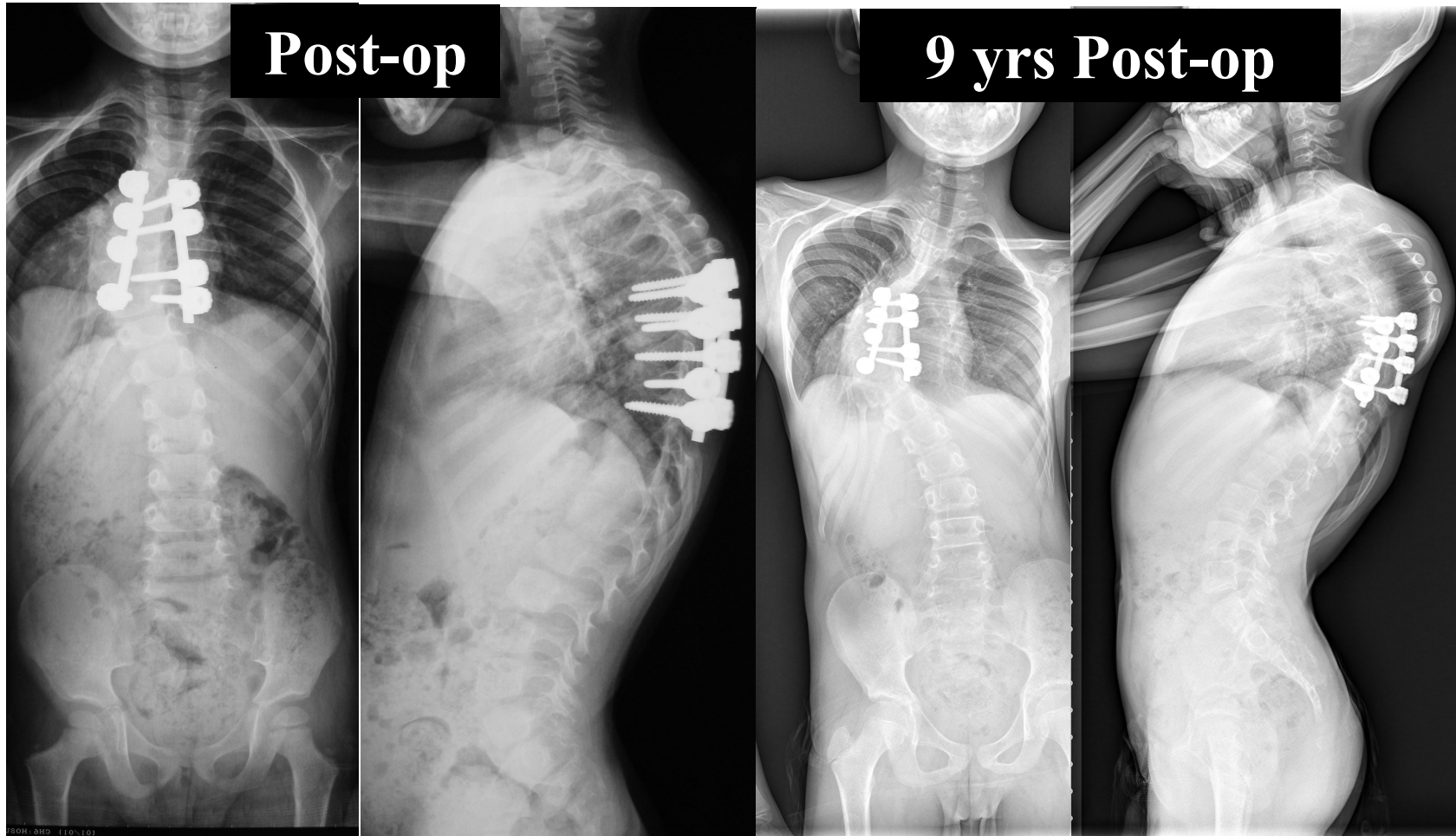
Results

	Pre-op	Post-op	Follo w-up	Correction rate(%)	Correction Loss
Segmental scoliosis (°)	36.9	7.2	11.8	80.4	4.6
Whole scoliosis(°)	38.1	6.7	18.3	82.4	11.6
Segmental kyphosis (°)	19.6	6.2	7.6	69.1	0.4
Whole kyphosis (°)	22.9	8.2	10.9	64.1	2.7
Cranial compensatory curve (°)	13.4	6.6	11.4	-	
Caudal compensatory curve (°)	15.5	4.1	9.1	-	
Trunk shift (mm)	15.3	8.8	5.9		
SVA(mm)	-14.8	-14.2	-12.1		
T1-S1 length (cm)	23.7	24.8	38.5		

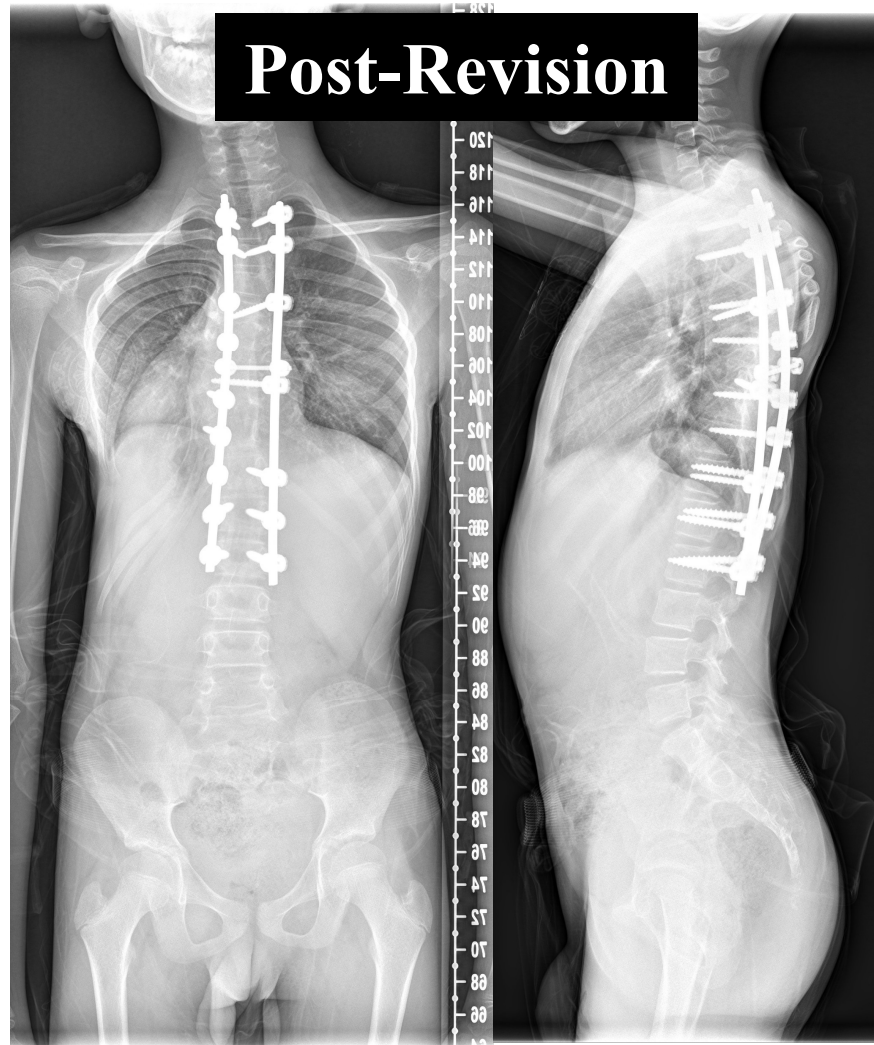
#4 M/3Y T9 HV



#4 M/3Y T9 HV



#4 M/3Y T9 HV



Risks for post-op decompensation

- **Uncomplete removal of the HV**

Complete removal of the HV and endplate

- **Under-correction of the local deformity**

Circumferential release

Anterior structural reconstruction

- **Too short fusion----whole scoliosis > segmental scoliosis**

EV to EV OR Hybrid technique

- **Unbalanced Multiple HV**

Staged skipping HV resection and short fusion



Summary

Posterior HV resection with short fusion

- Correct the deformity
- Avoid long fusion or fusionless technique
- Save mobile segments
- Allow for the growth of the spine
- Implants failures in young children
- Decomensation may occur in the 2nd growth peak



Thanks

