

Posterior Vertebral Column Resection in Two Myelopathic Children Under 6 years of Age with Tuberculous Kyphosis

Anthony Rinella, MD

Matt Geck, MD

Juan Uribe, MD

Mario German Gonzalez, MD

Steve Mardjetko, MD

Two Children in Cali, Colombia

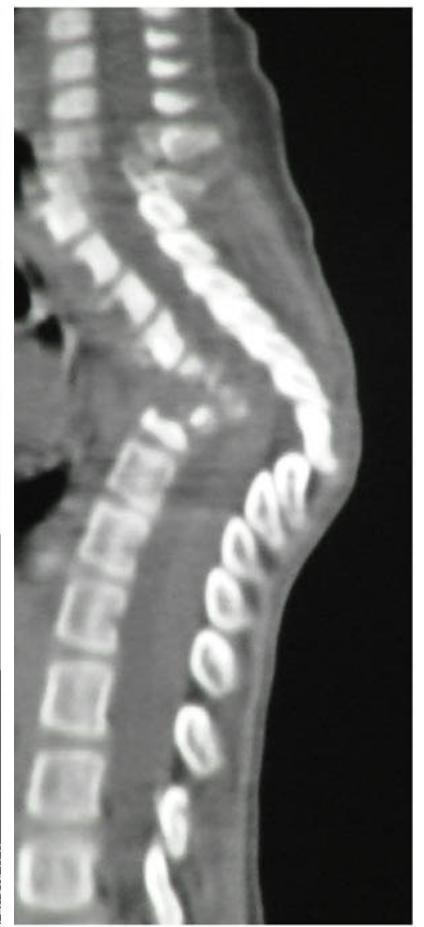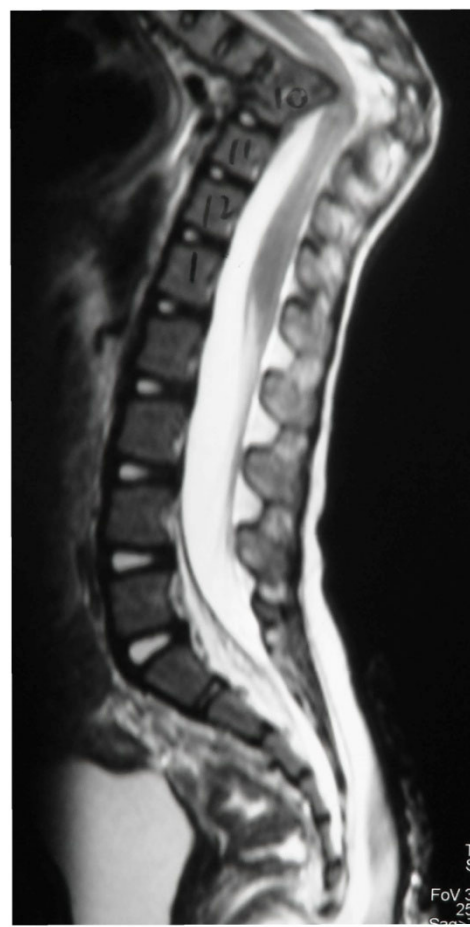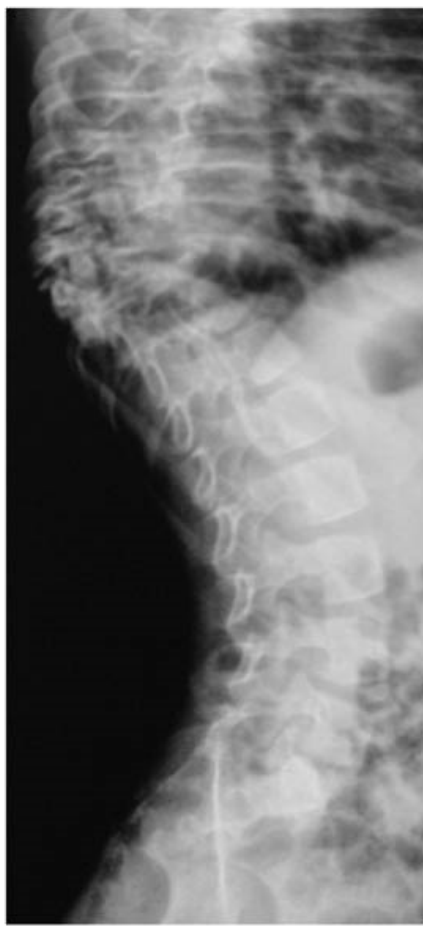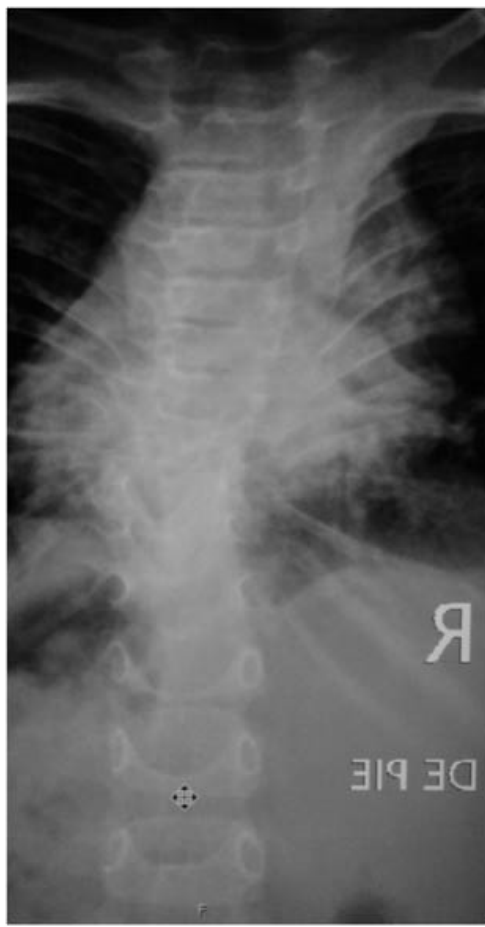Case 1

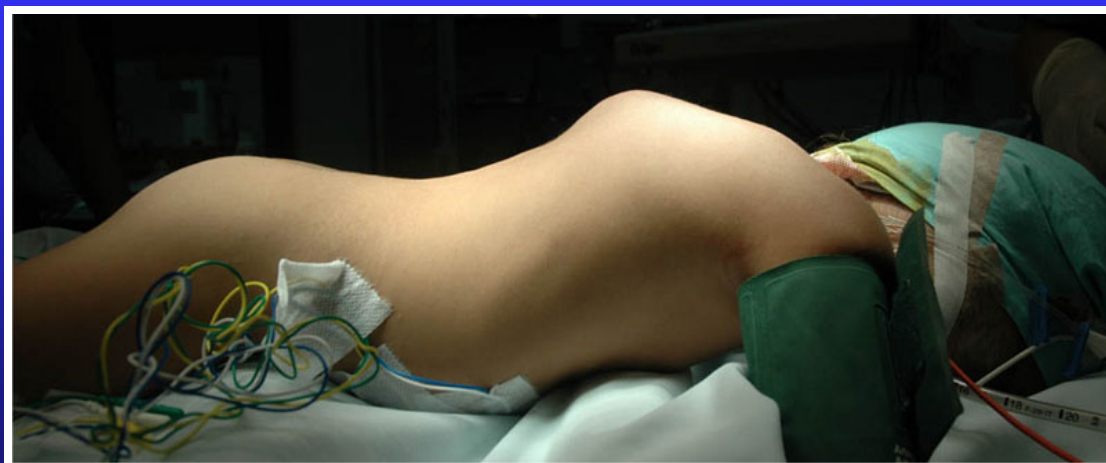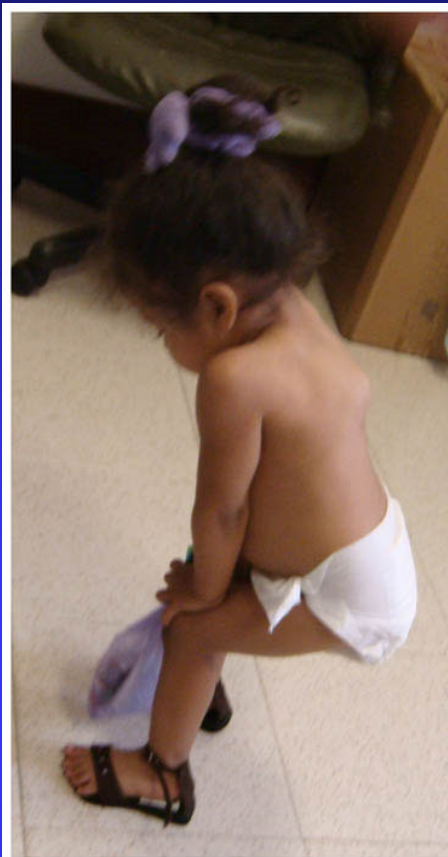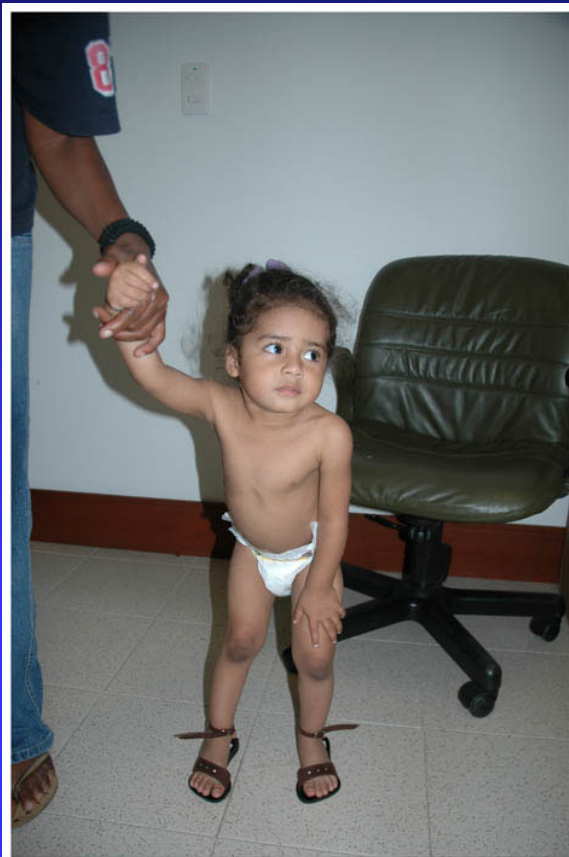- 2+10 year old girl with spinal TB soon after birth inadequately treated with antibiotics
- 85° kyphosis and progressive myelopathy at first visit
- Normal labs

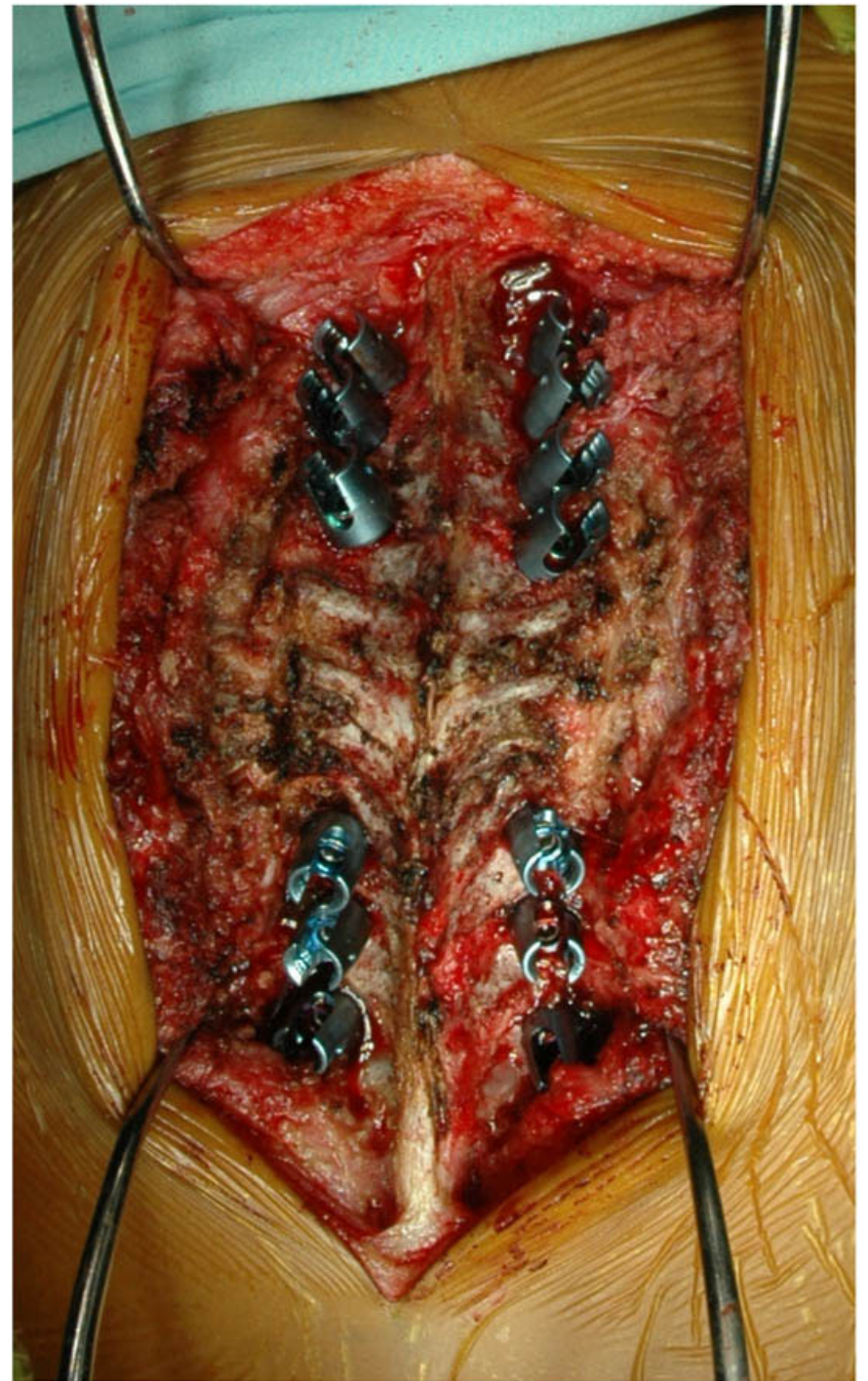
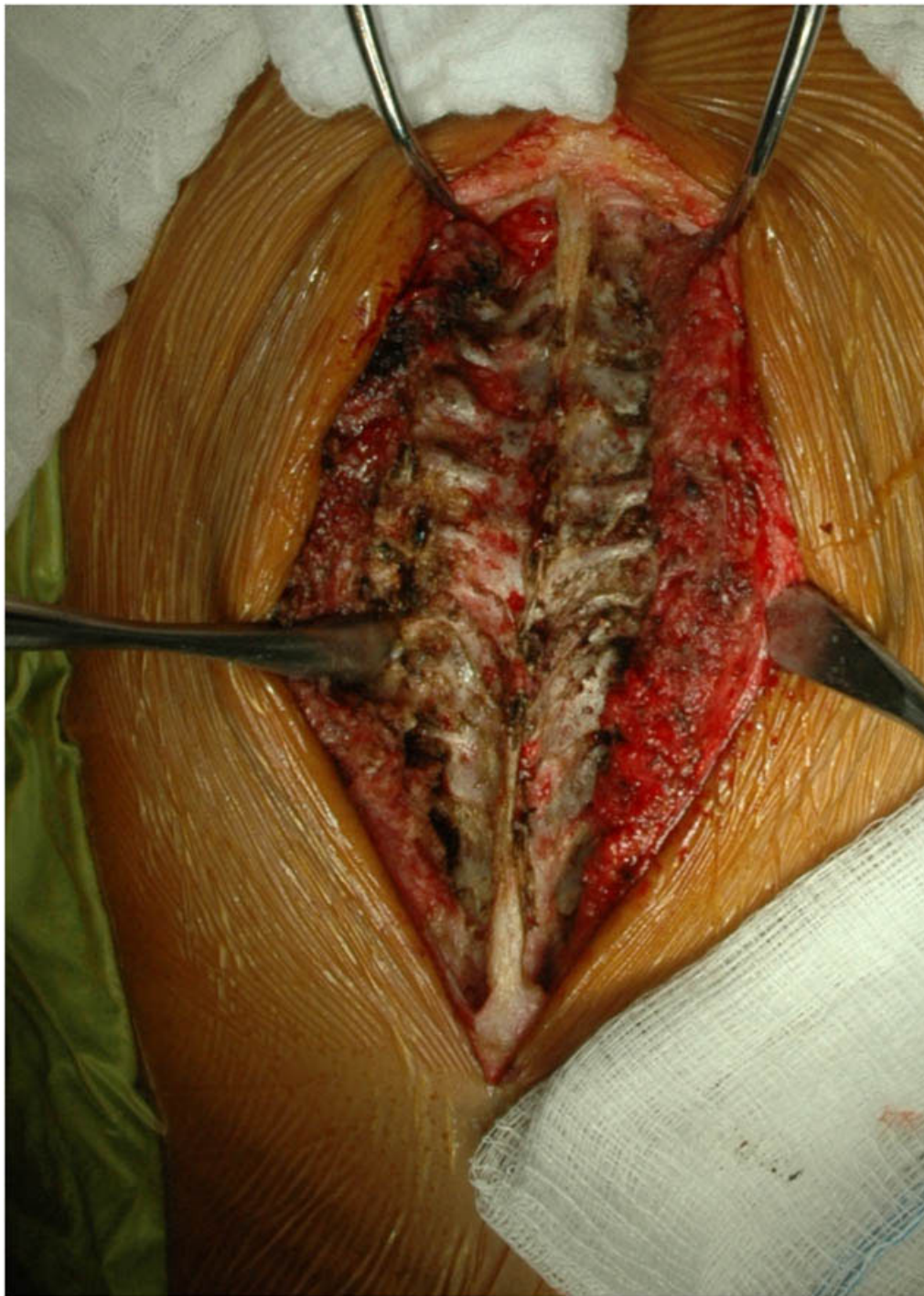Case 2

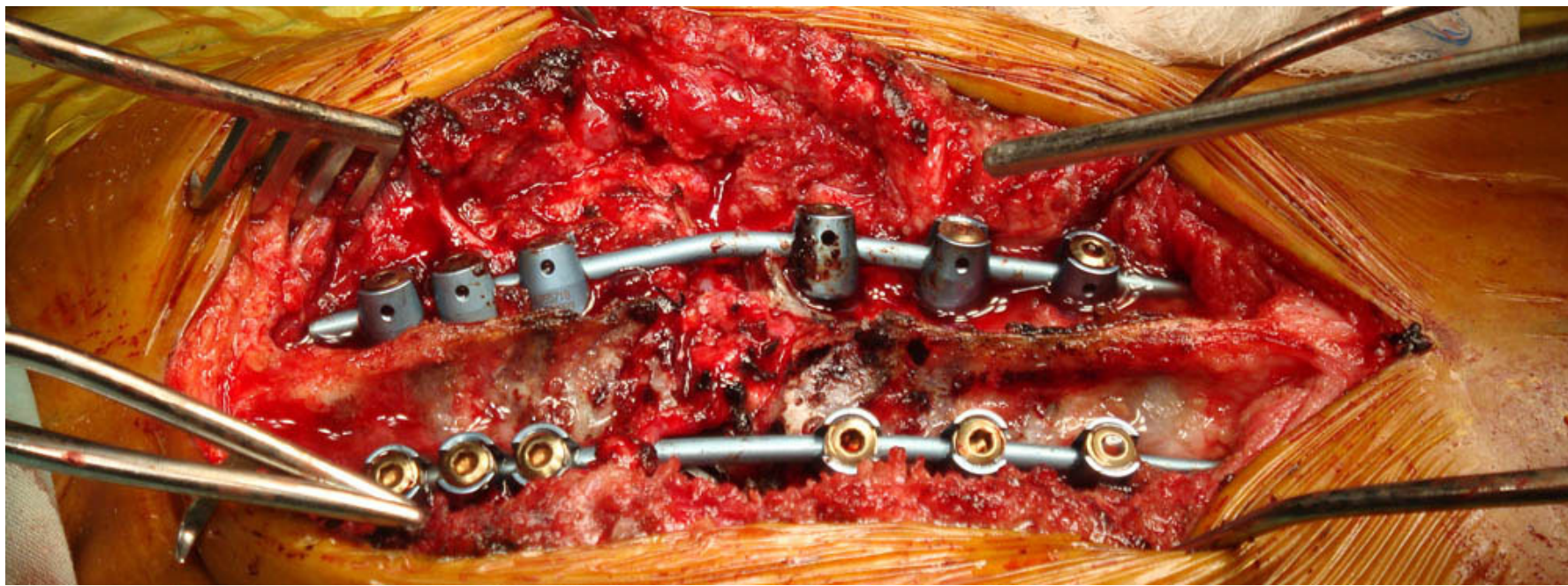
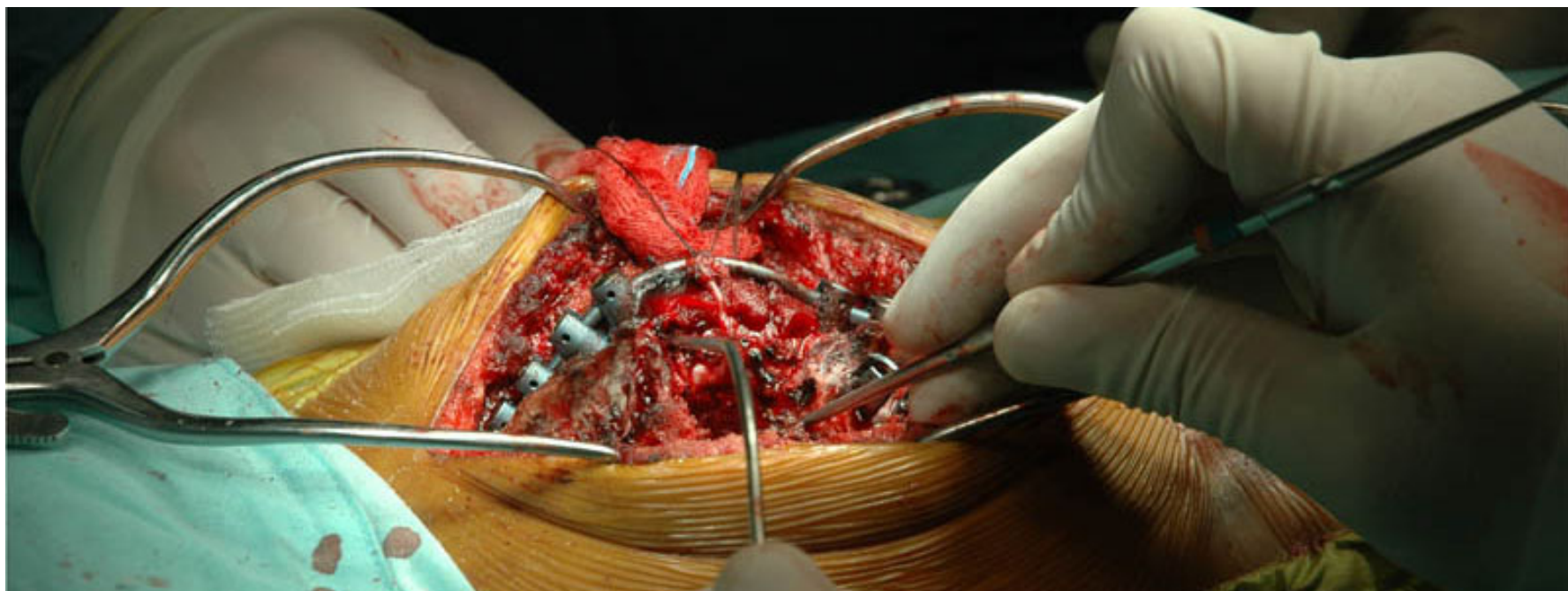- 5 +11 year old boy with spinal TB soon after birth inadequately treated with antibiotics
- Slowly progressive kyphosis (90°) and myelopathy

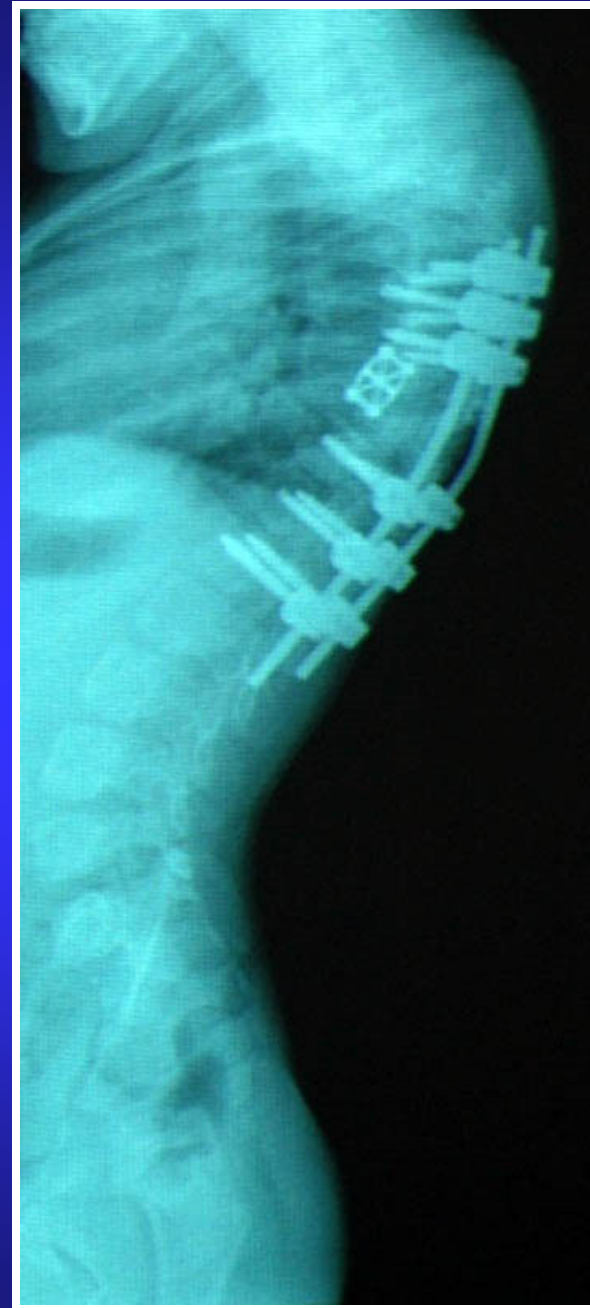
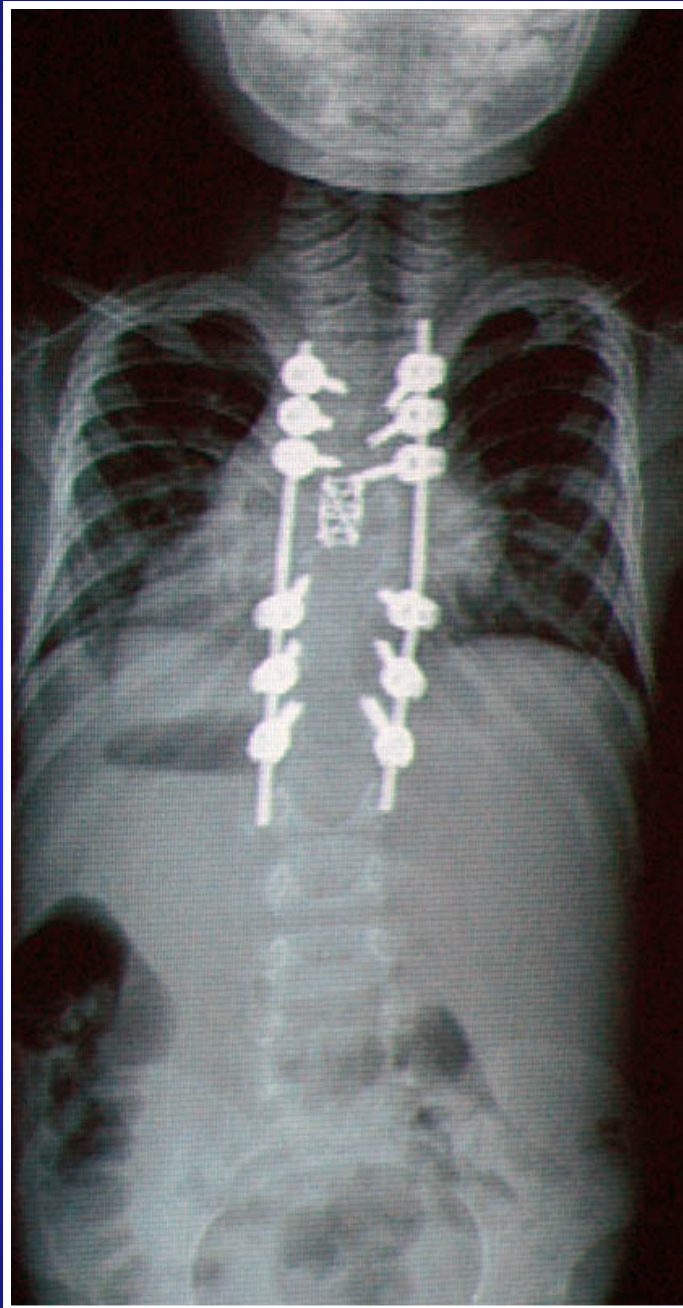
Case 1



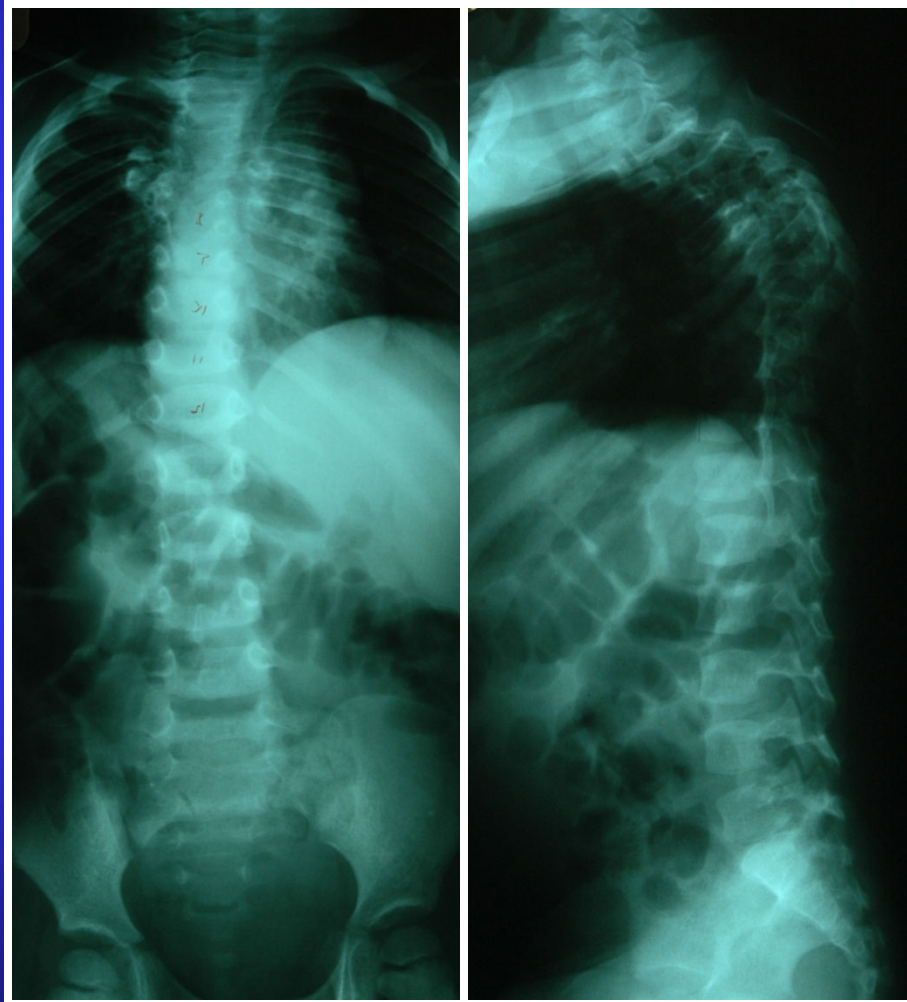




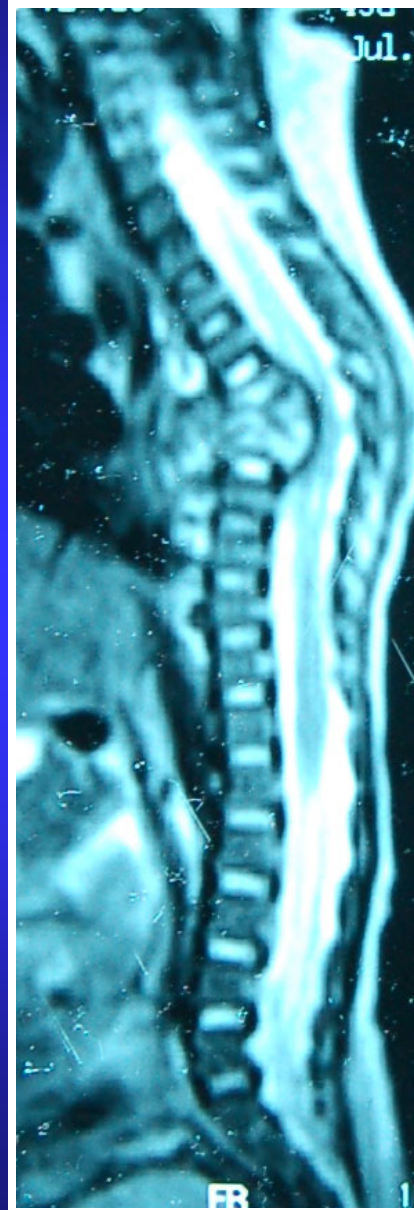




Case 2



45 days old



5 years later

