

November 7-8, 2008 | Montréal, Québec

2nd International Congress on

Early Onset Scoliosis & Growing Spine

ICEOS

Debate:

Correction by traction followed by cast or
brace is the treatment of choice for syndromic
deformity under the age of 6 years

Against

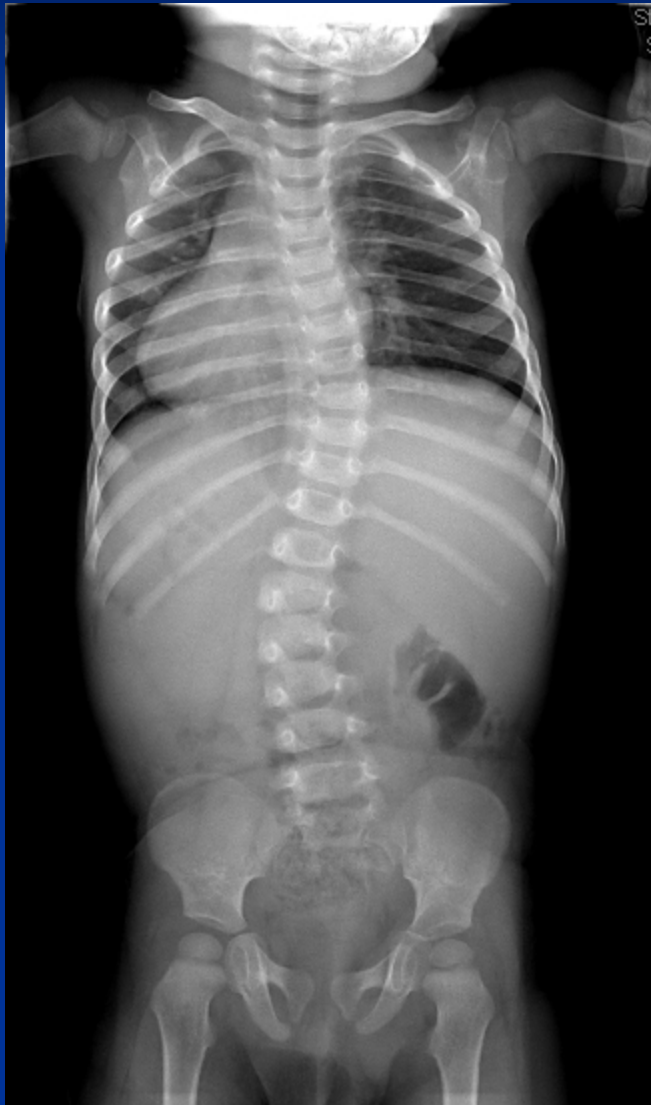- Gerard Bollini MD PhD
Marseille, France
- George Thompson MD
Cleveland, OH, USA

For

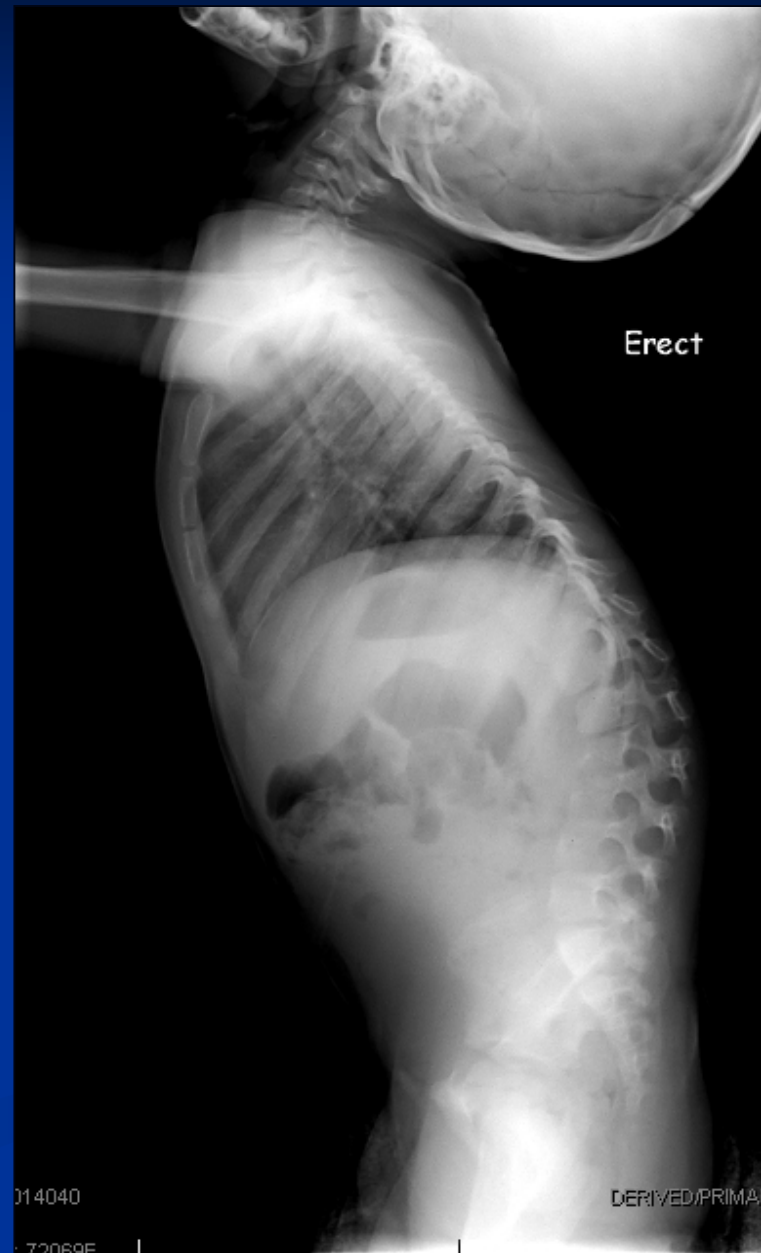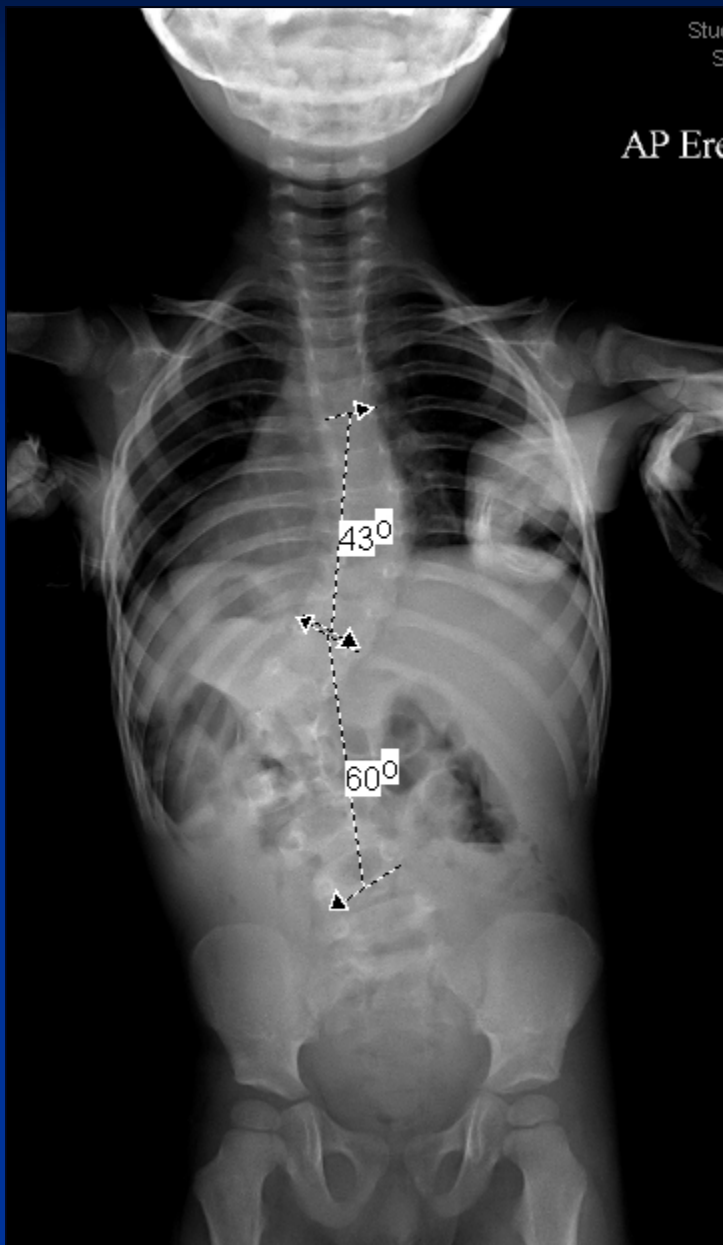
- Charles Johnston II MD
Dallas, TX, USA
- Reinhard Zeller MD
Toronto, Canada

Moderator: Suken A. Shah MD Wilmington, DE, USA

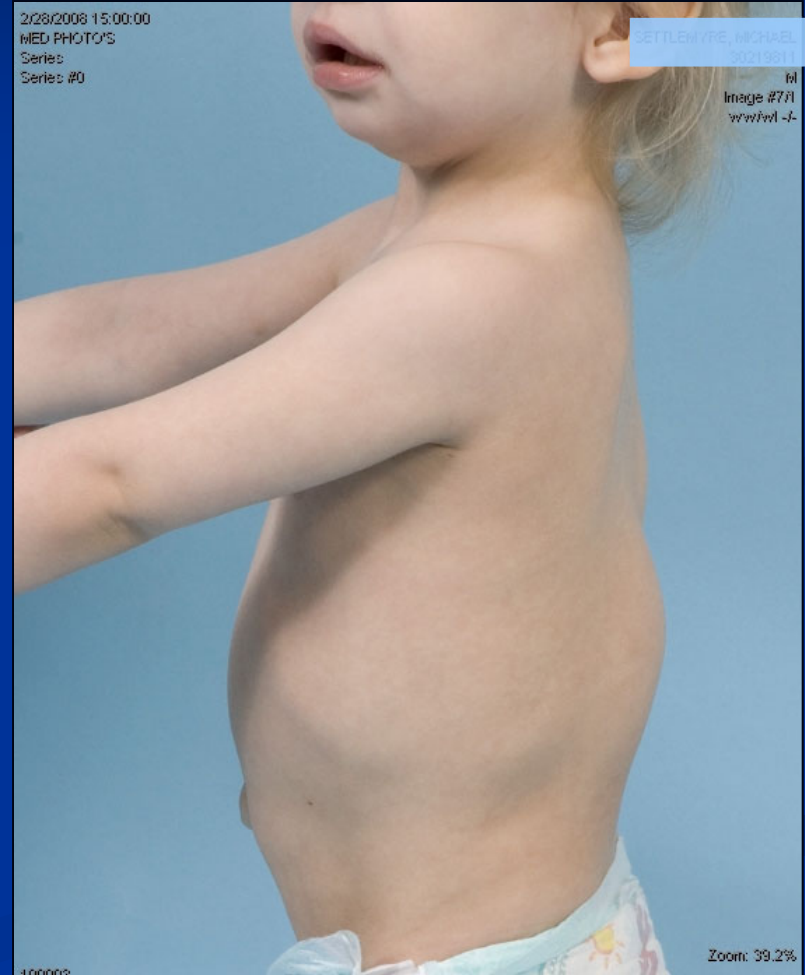
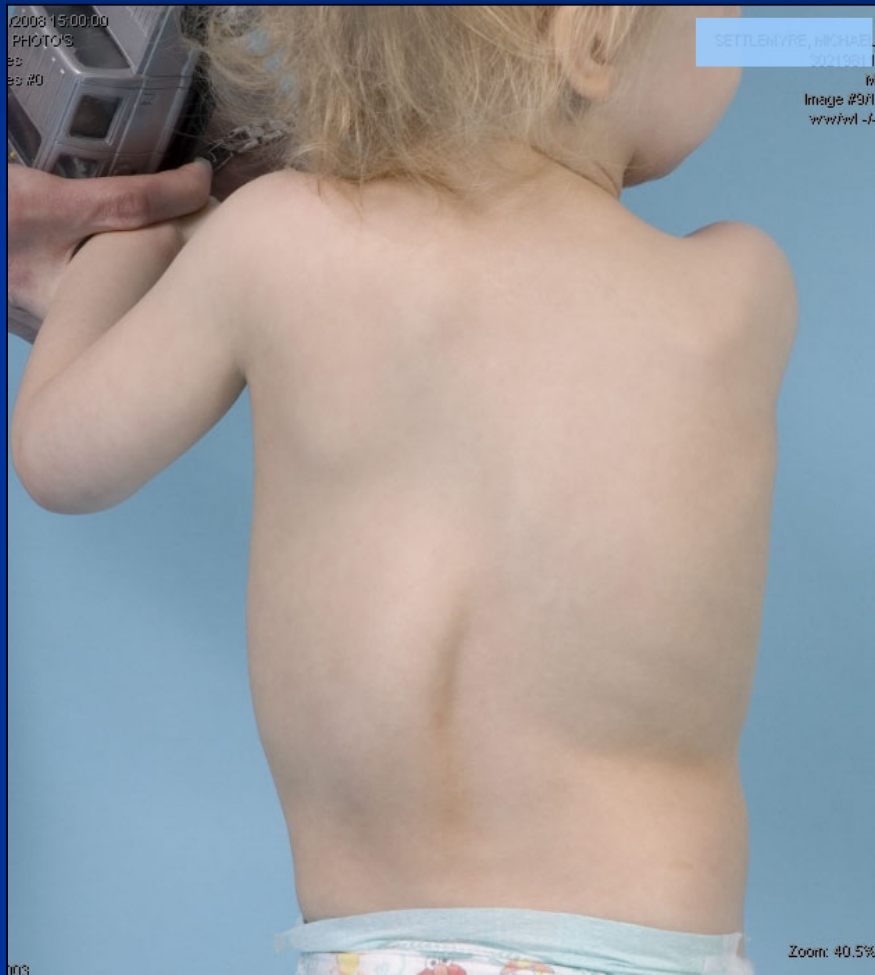Case 1: Age 12 months



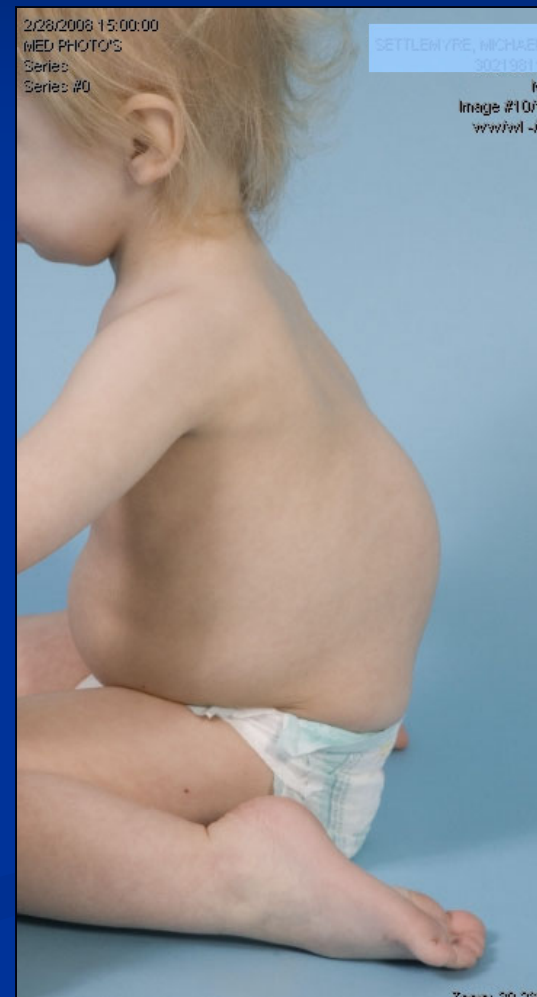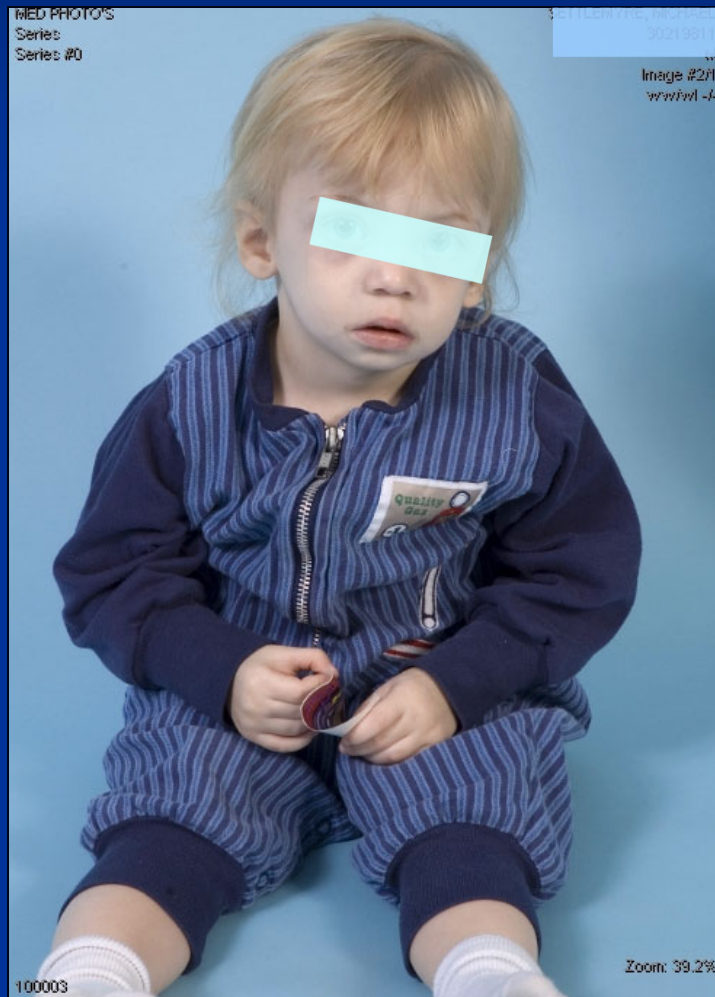Age 23 months



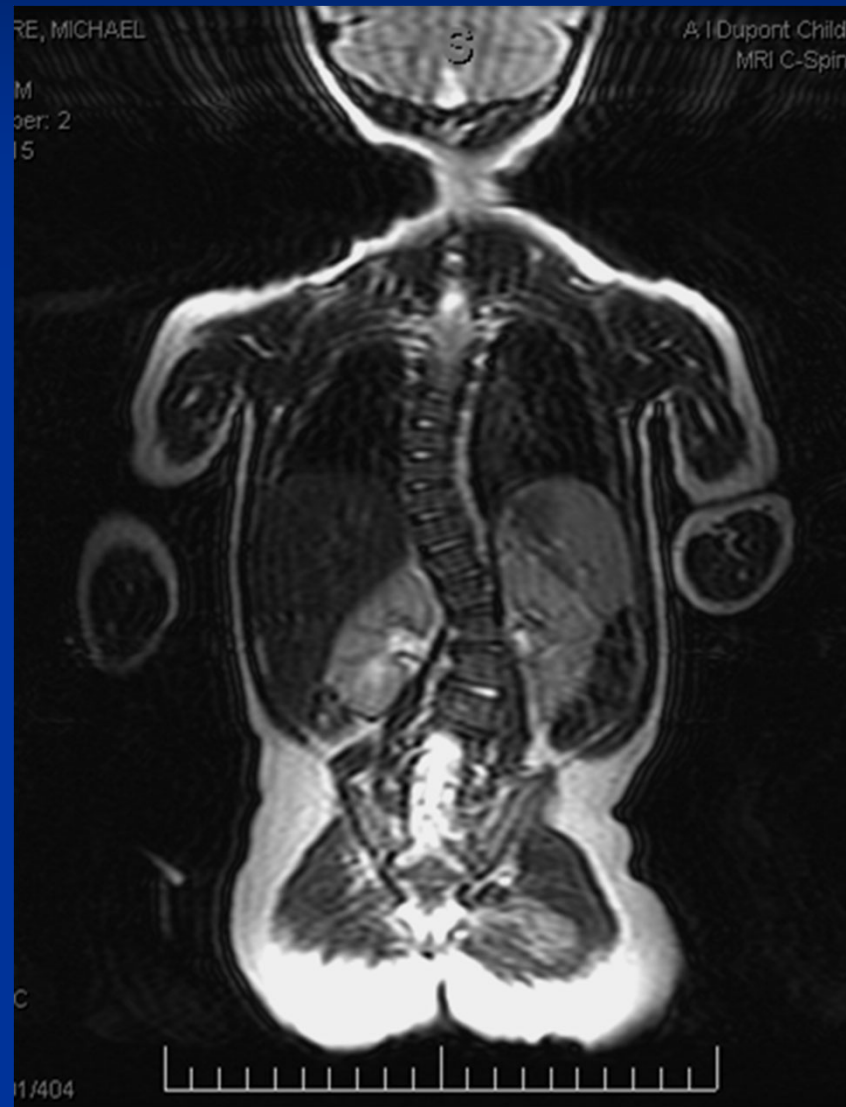Clinical Photos



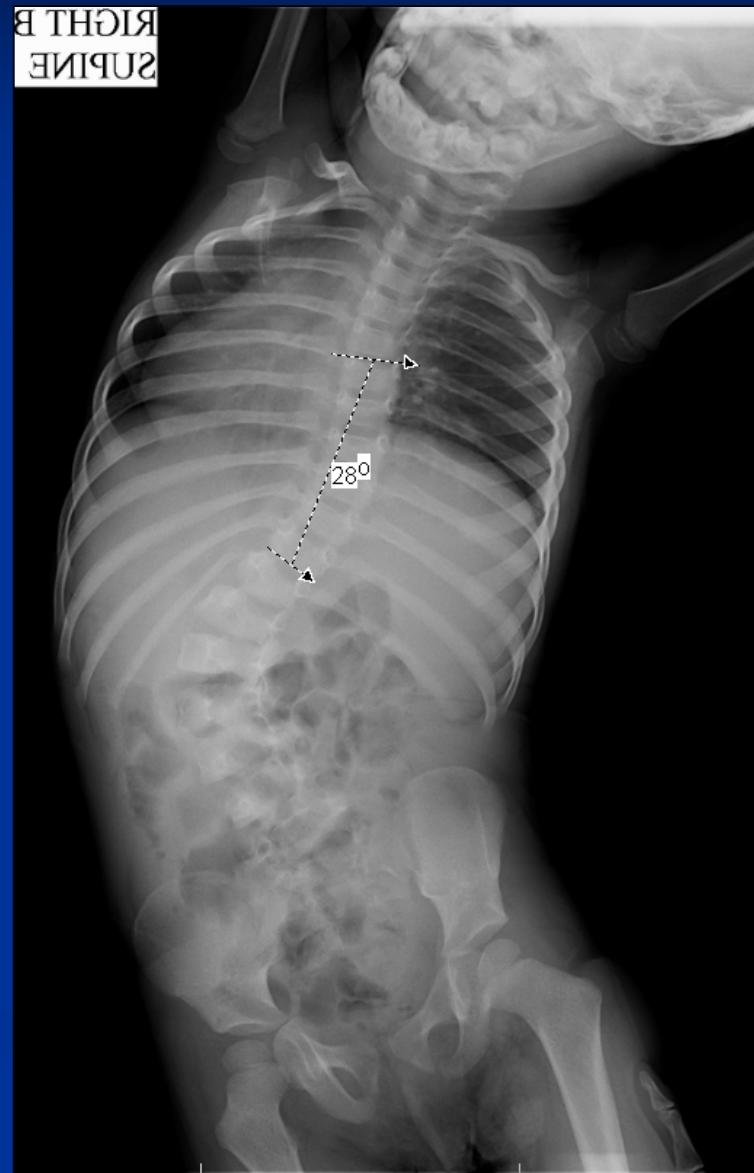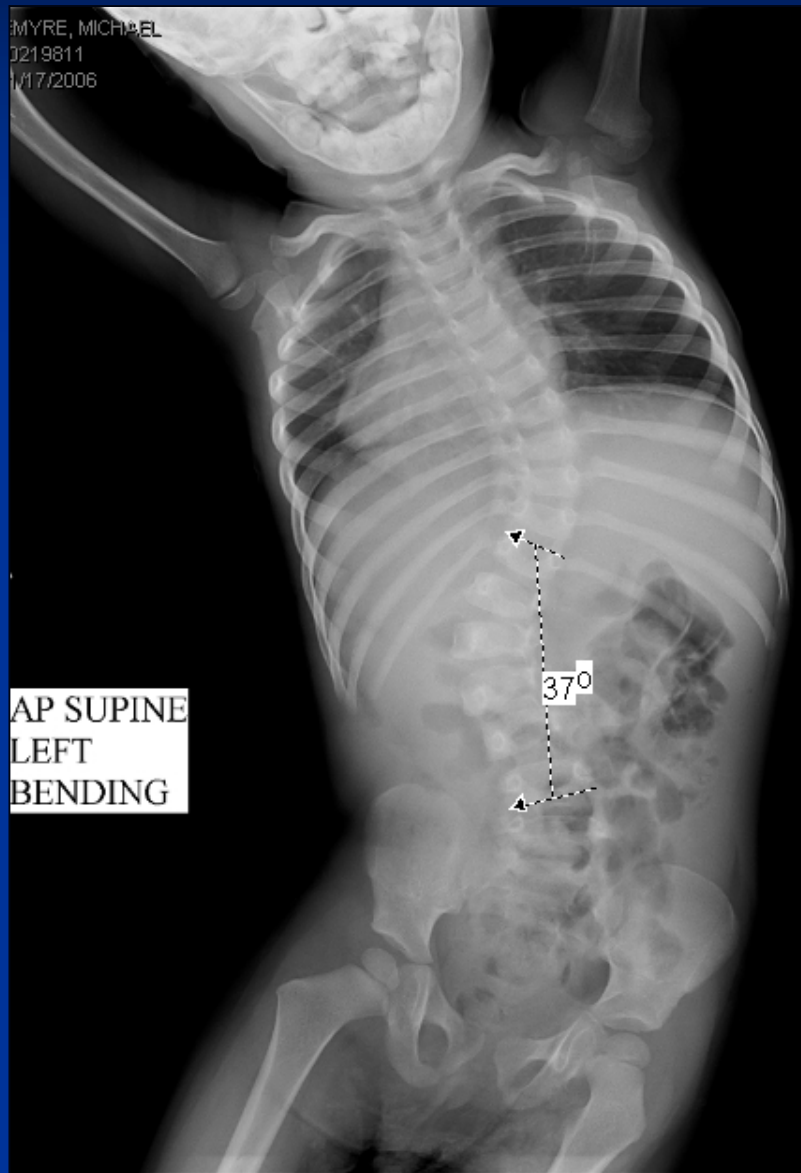
Clinical Photos



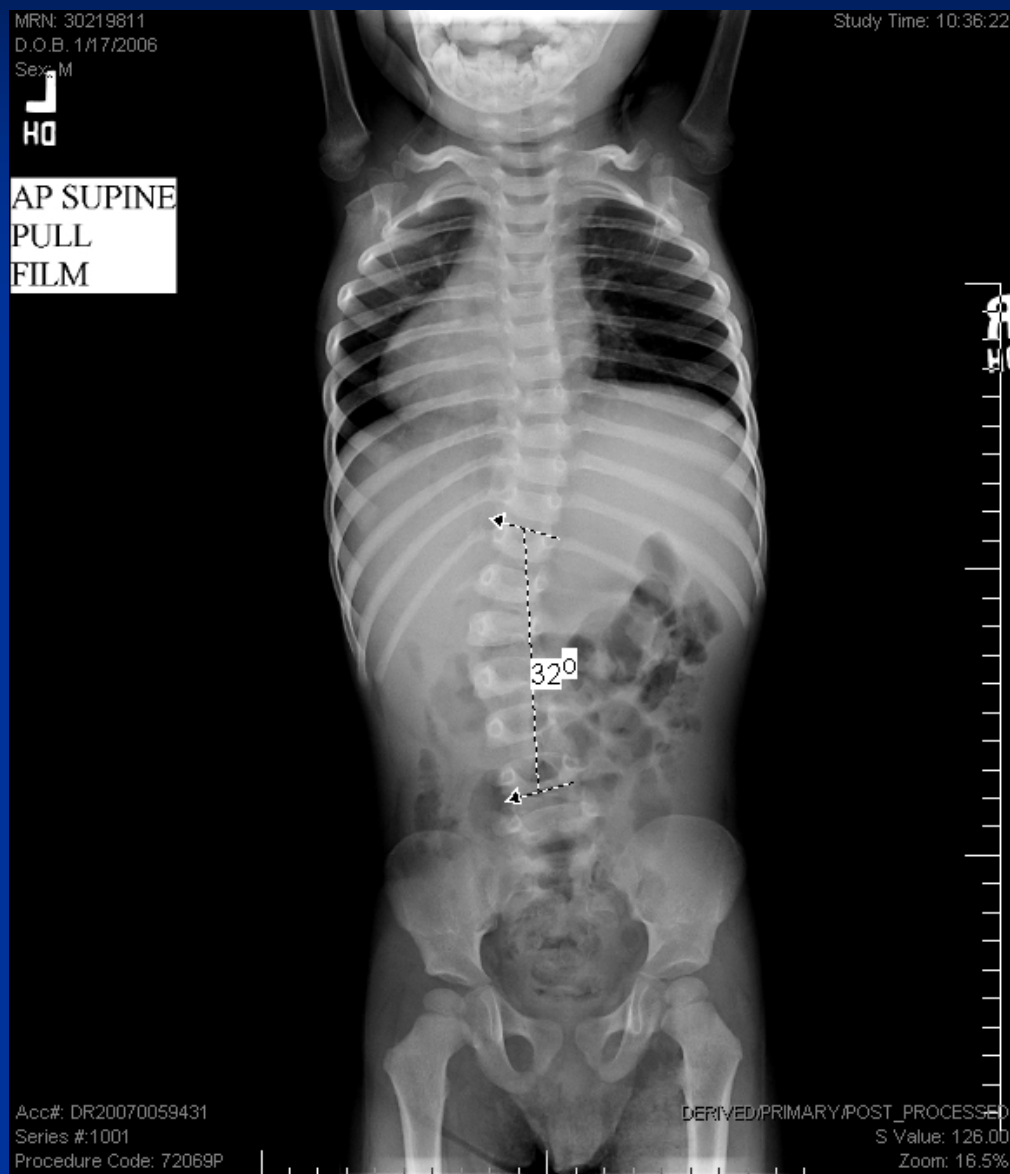Normal MRI



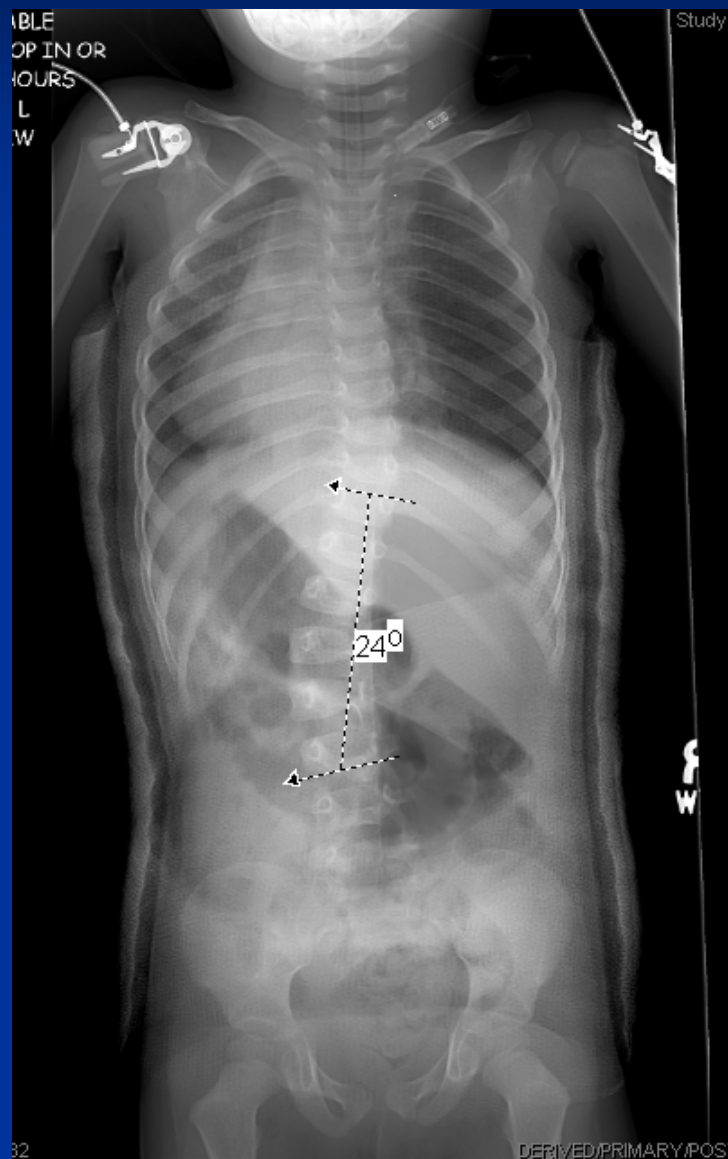
Bending X-rays



Traction film



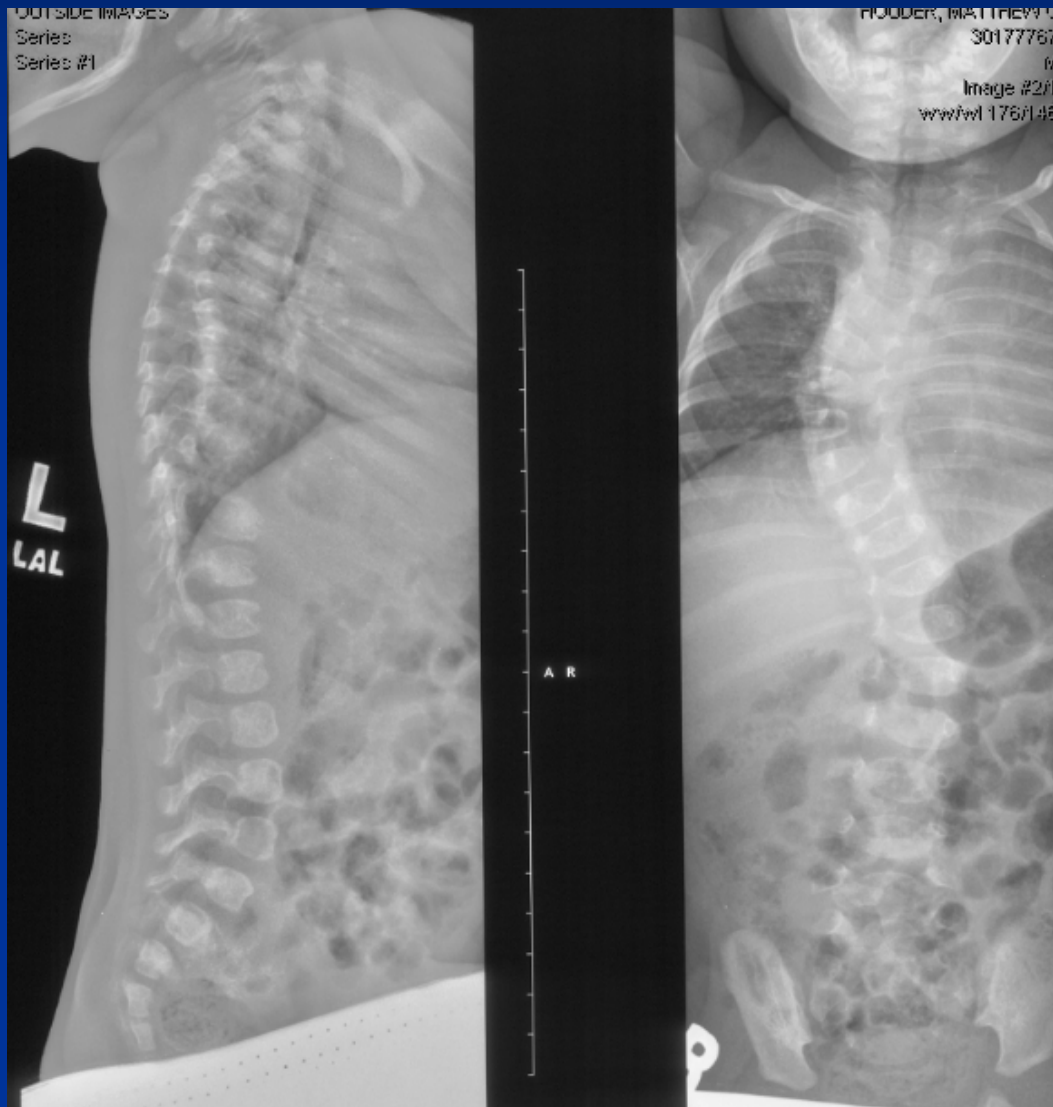Post – cast X-ray



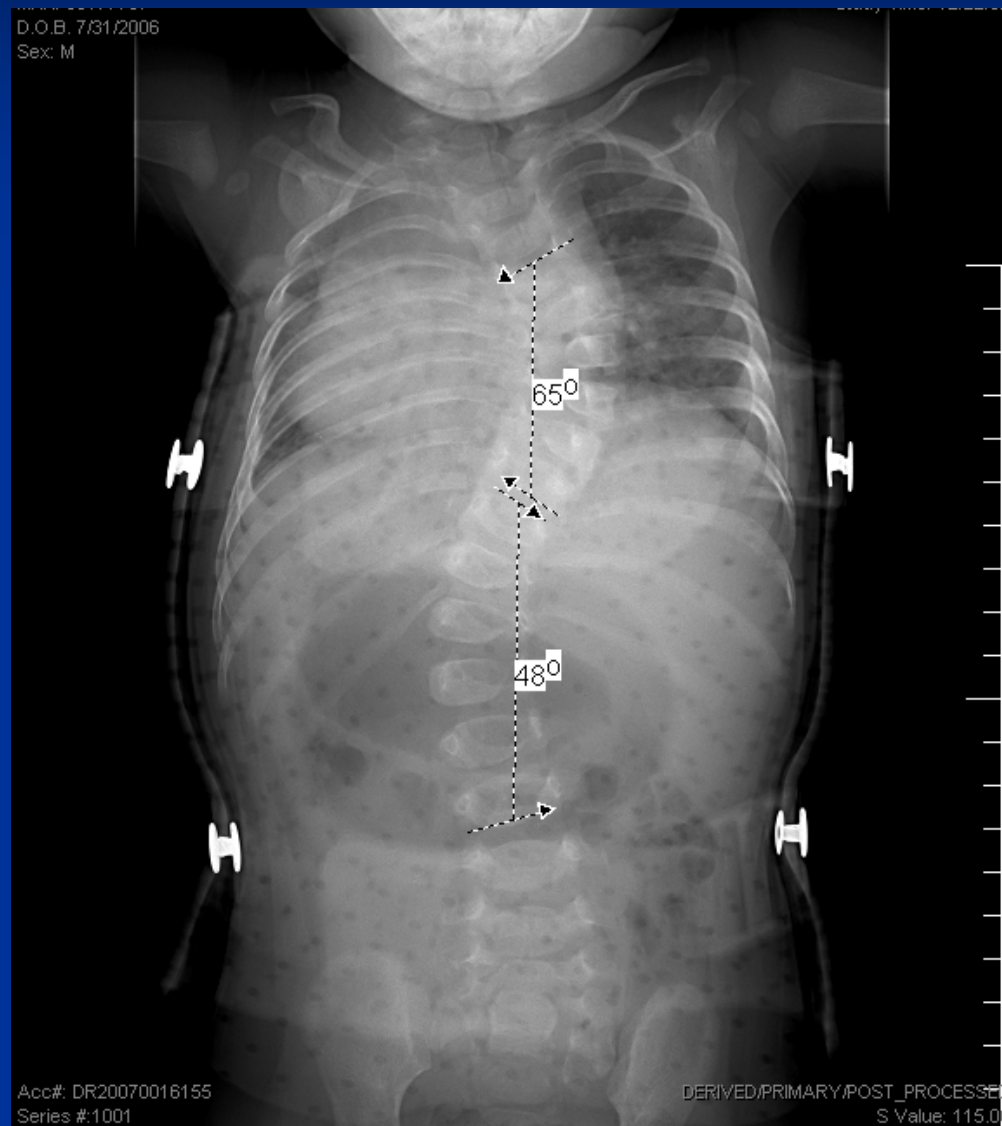
Case 2

- Child presents at 6 months
- Significant curve, detected by pediatrician
- Pierre-Robin syndrome
- Failure to thrive
- Geneticist doesn't know what else he has

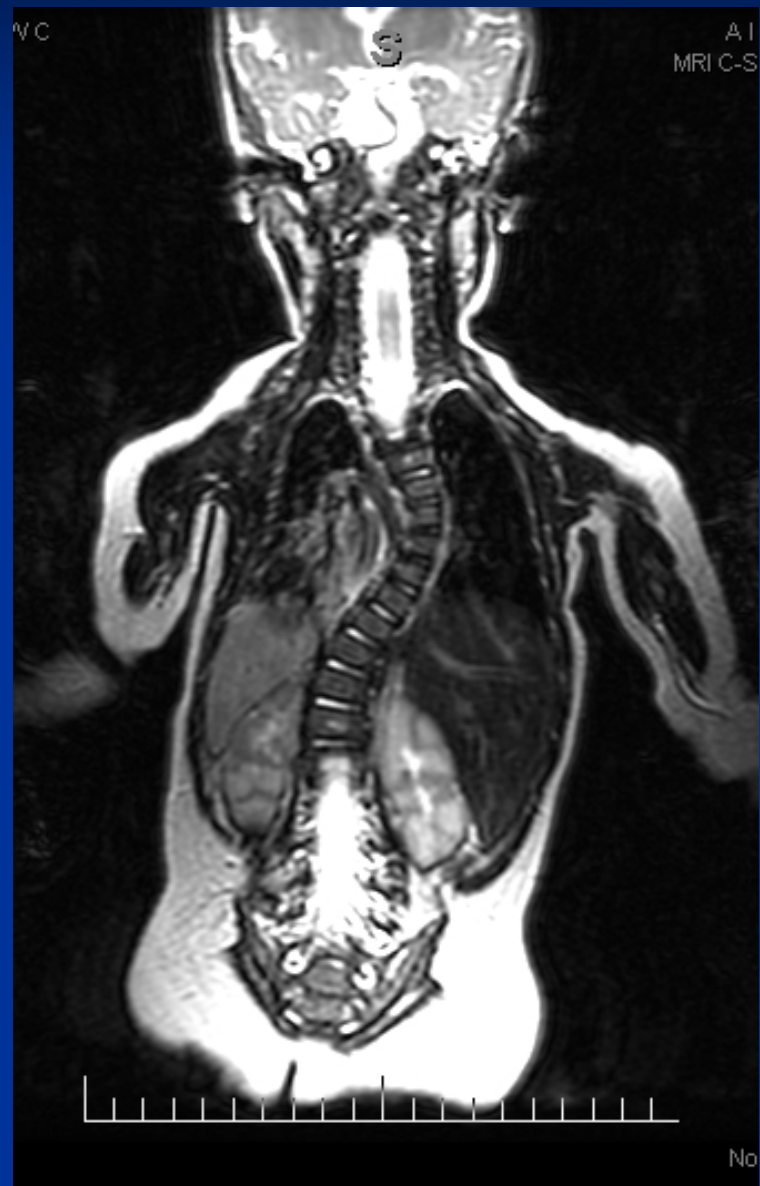Initial Xrays – 6 months



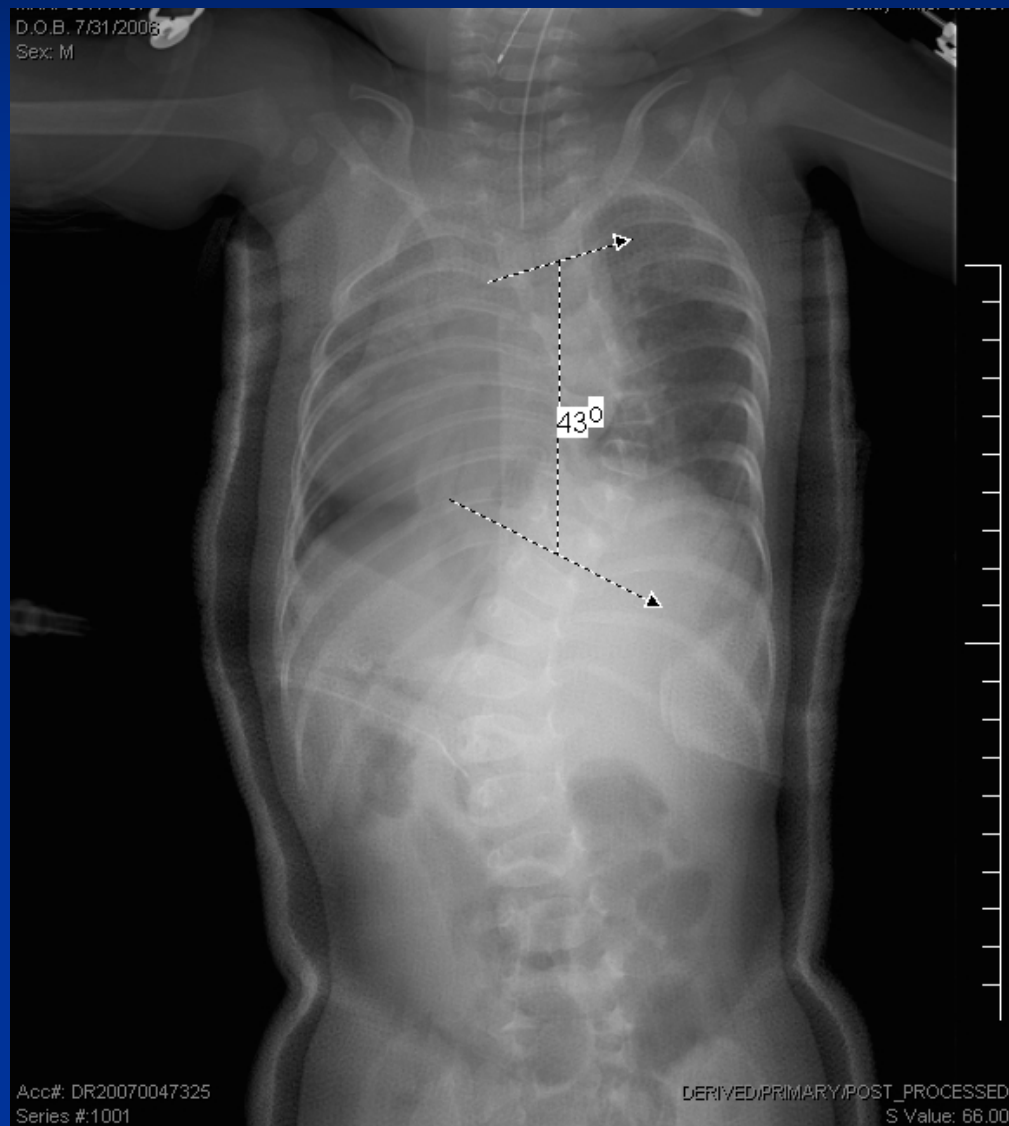
In brace X-ray at 10 months



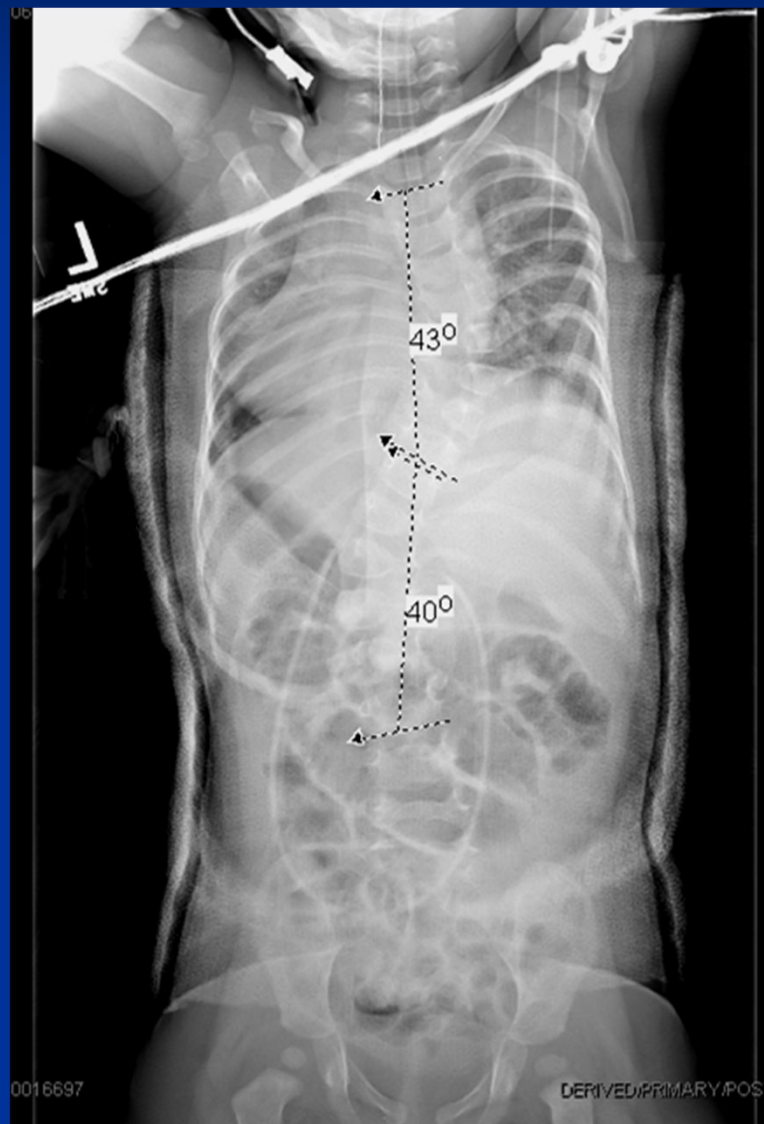
Normal MRI



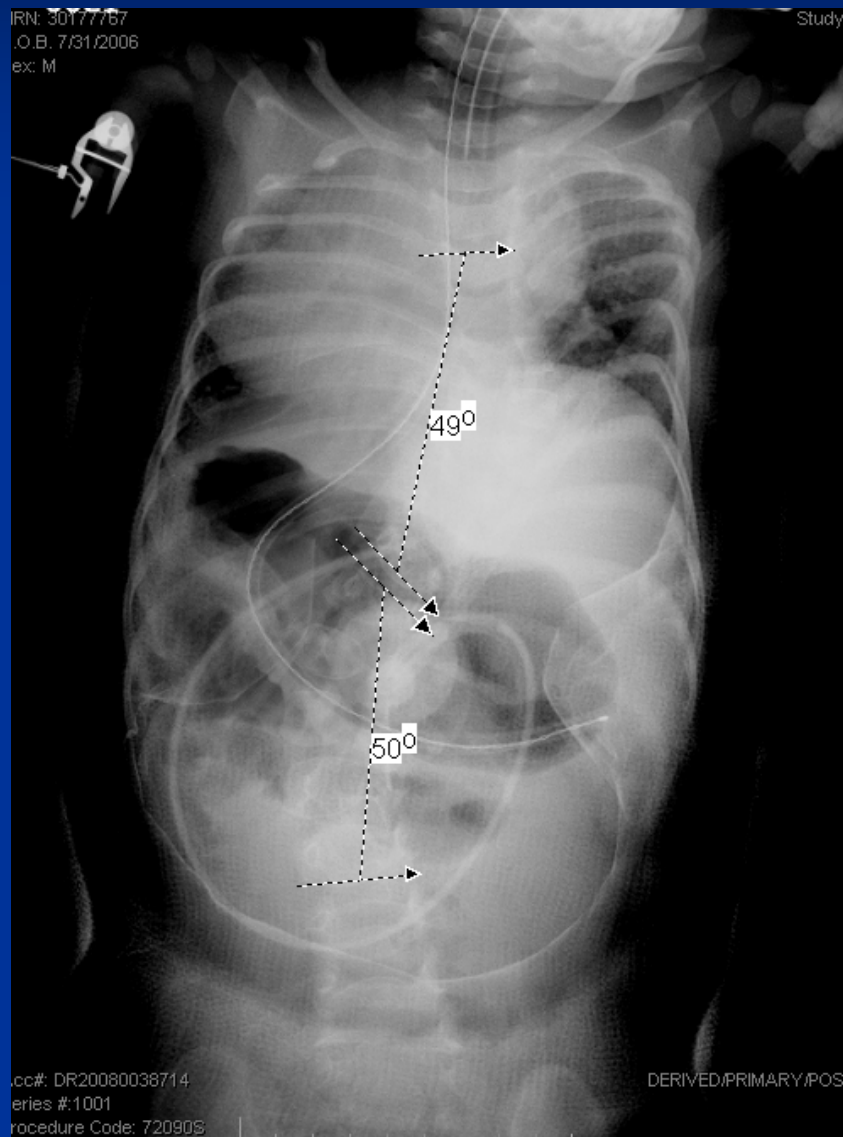
1st EDF Cast



2nd EDF cast



3rd EDF cast – 2 years old



Case 3: Severe Kyphoscoliosis

