

ICEOS 2008

Debate:

Chest Cage Based vrs. Spine Based

RM Campbell, MD

J Emans, MD


The term “scoliosis” is obsolete

- It is 2,500 years old
- Do we still use the term “consumption” for Tb ?
- In the 21st century the two dimensional concept of lateral curvature of the spine

AKA “scoliosis”


is inadequate to describe the complex deformity and biomechanical disability of the thorax in spine / chest wall disorders

Some
things
are
just
past
their
prime....





Why must we all think alike?




Martinsburg

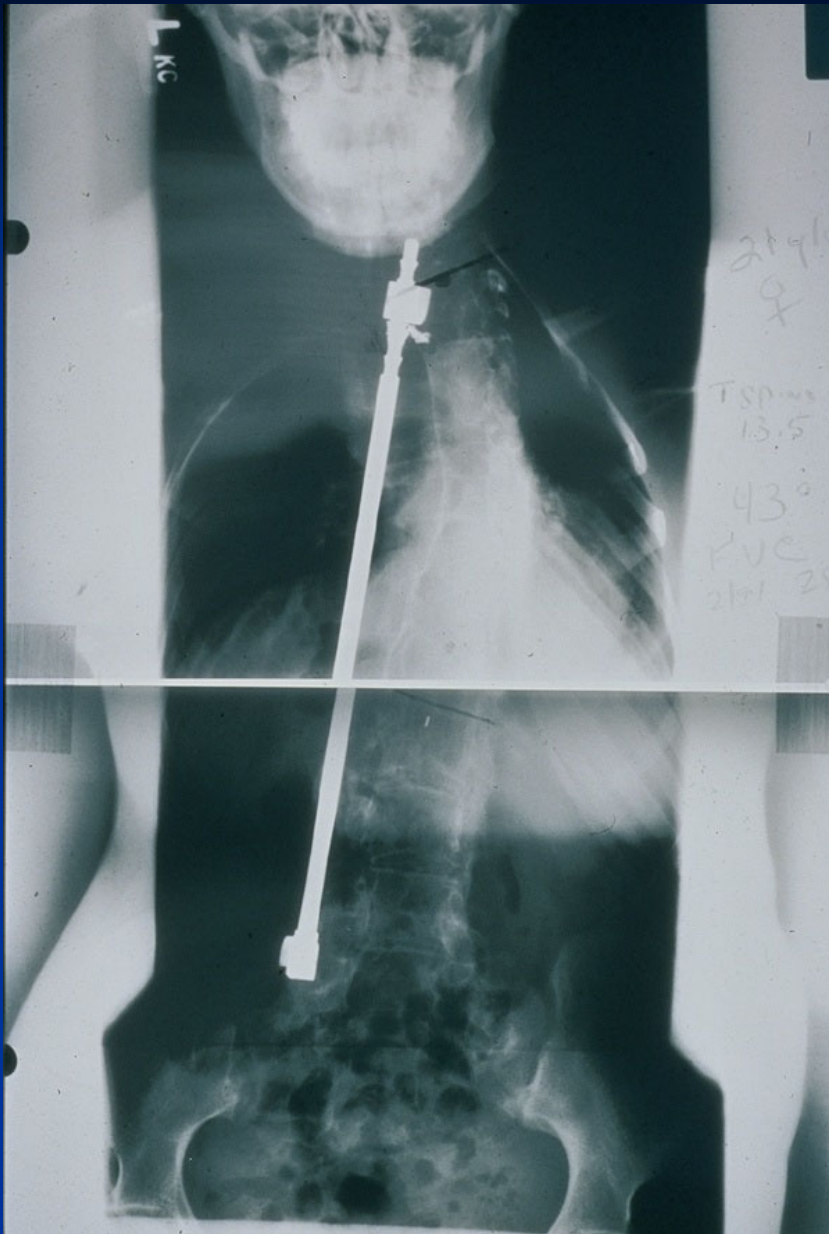
7 MAGGIO

Ragazzini e genitori
radunati per
battere uno strano
record: essere in più
di 1.437 a indossare
contemporaneamente
gli occhiali alla
Groucho Marx.



Is it time to get off the "scoliosis"
treadmill and move on?





Age 21 years

Short, straight spine

VC 28 % normal

T spine 13.5 cm (new born)

Respiratory Insufficiency

Lethal

Thoracic Insufficiency Syndrome

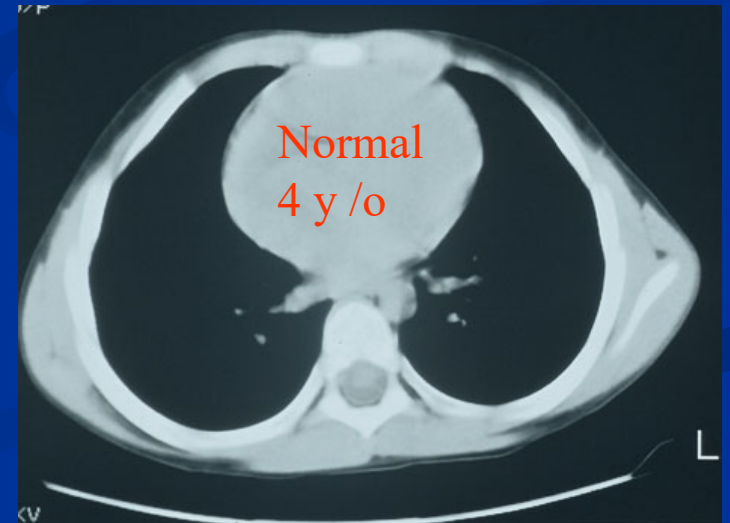
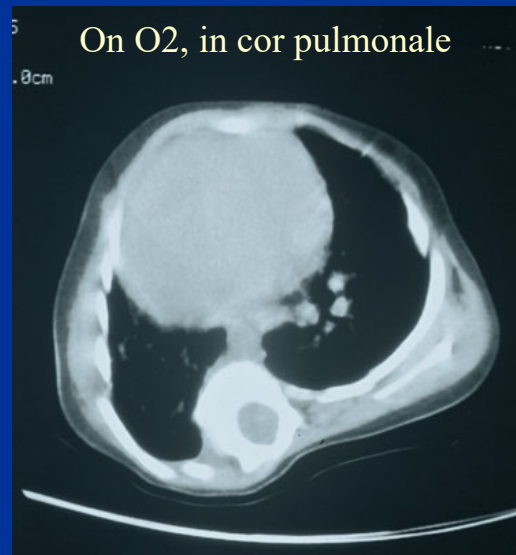
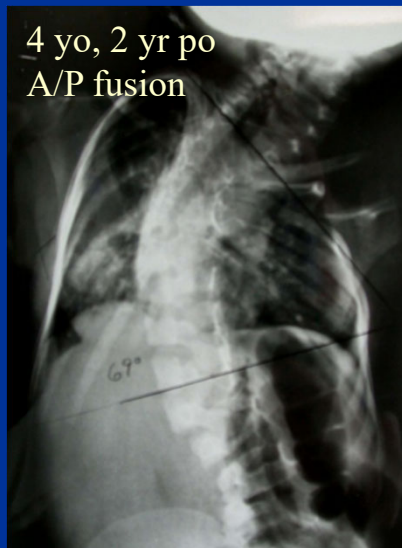
Age 25 years

Death from pneumonia


- Campbell, Smith et al
- J Bone Joint Surg, 2003

The Growing Thorax

- Must enlarge for lung growth
 - Rib cage provides width and depth
 - Thoracic spine provides height
- Failure to grow (thoracic failure to thrive) causes extrinsic, restrictive lung disease



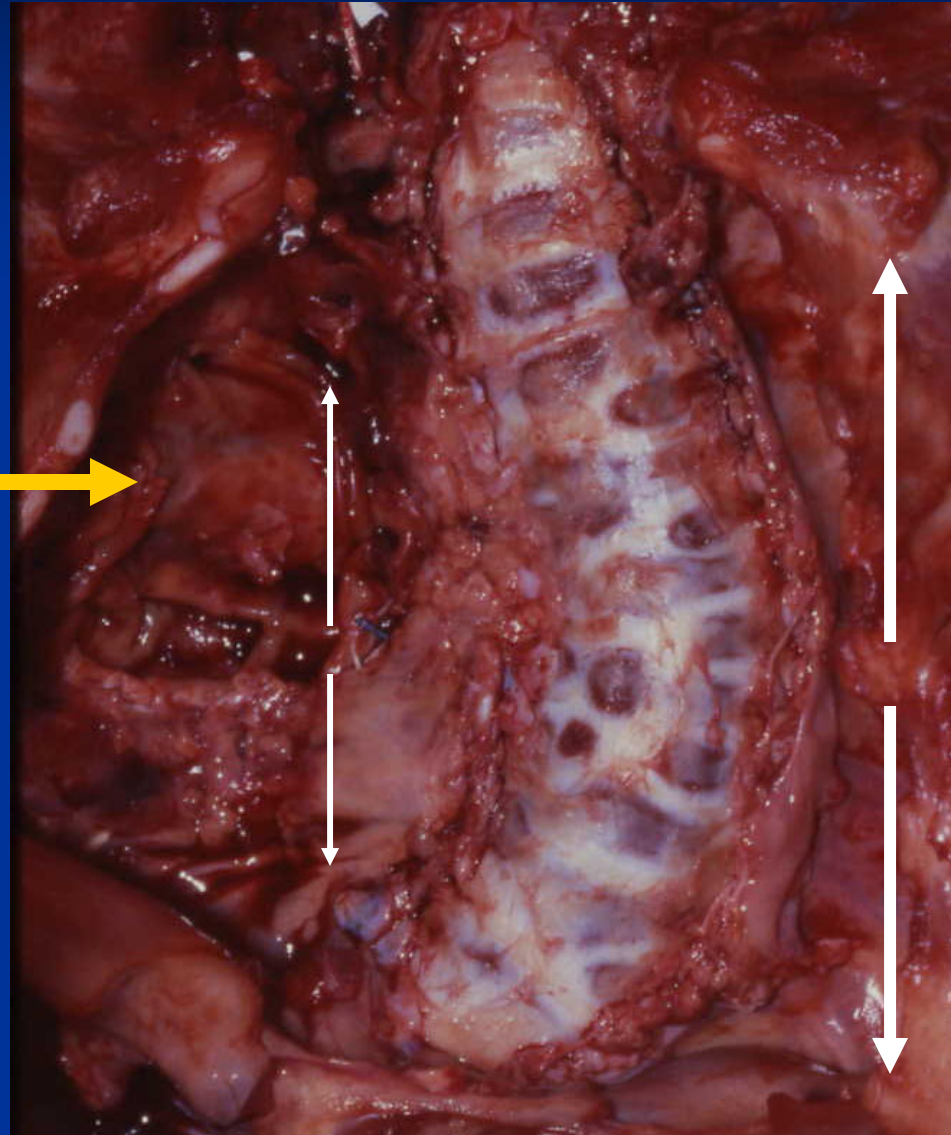
Extrinsic,
restrictive
disease



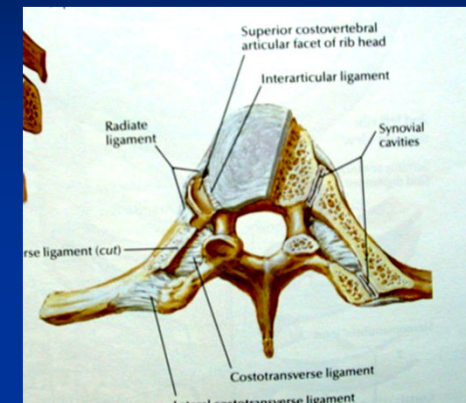
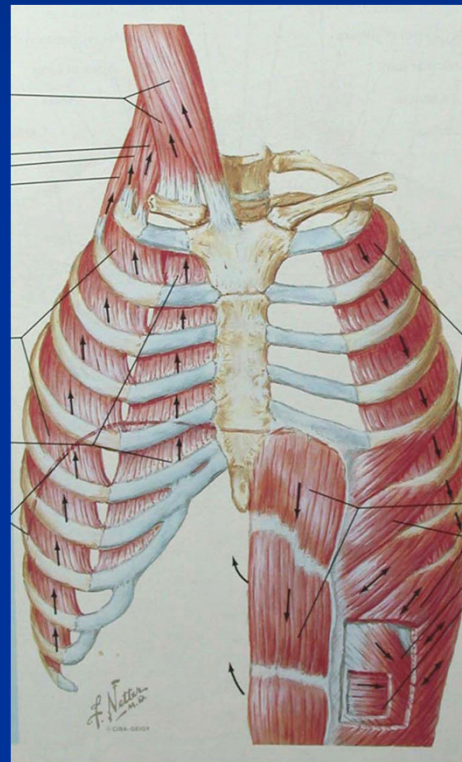
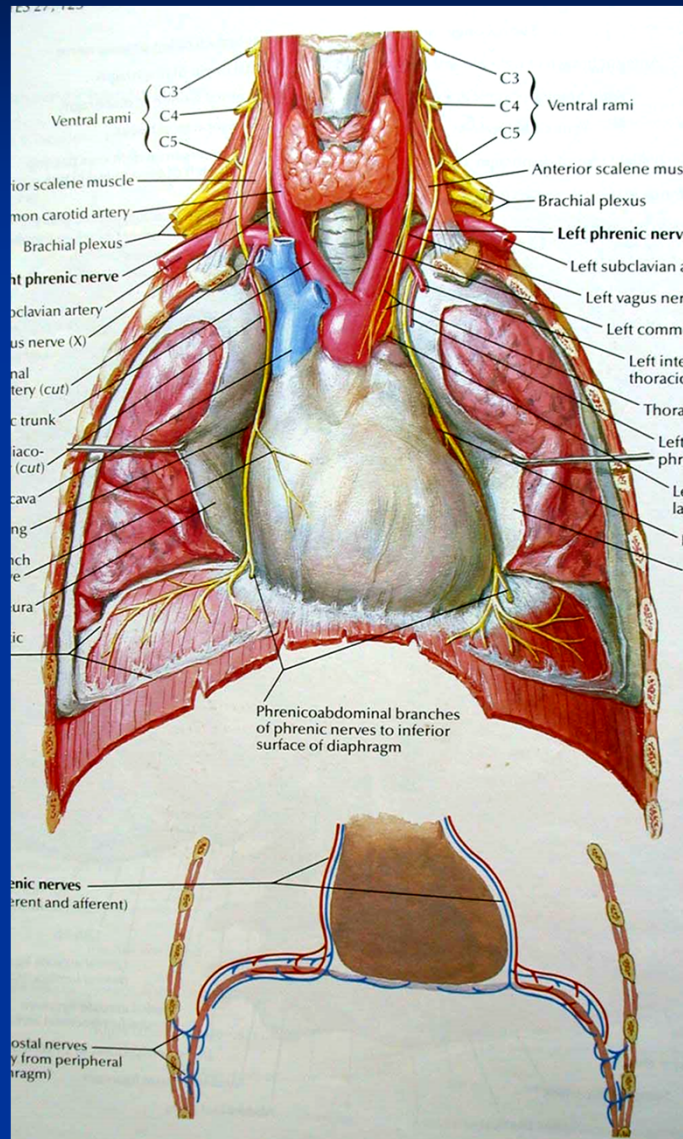
It's time to look at things
differently



Congenital Scoliosis: An Intrinsic Lateral Column Growth Imbalance



Functional Thoracic Anatomy

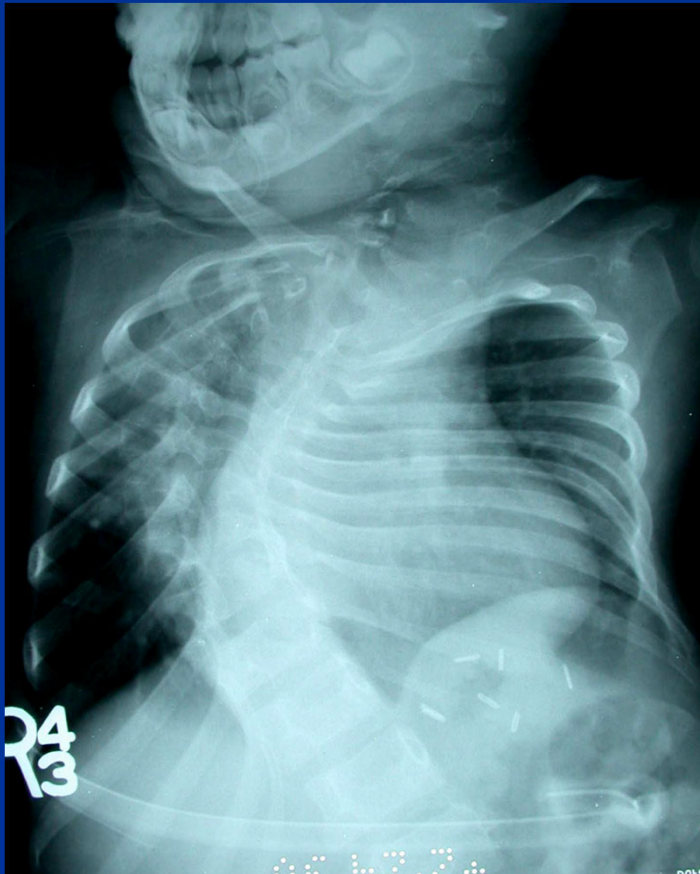

- Protection
- Support
- Expansion

Three Dimensional Thoracic Deformity

Spine Deformity

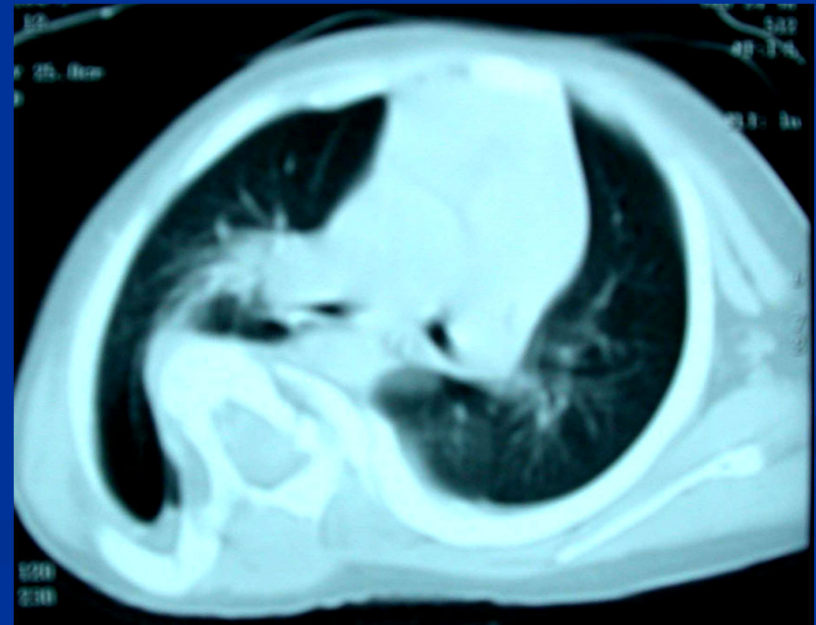
- Scoliosis/ Rotation



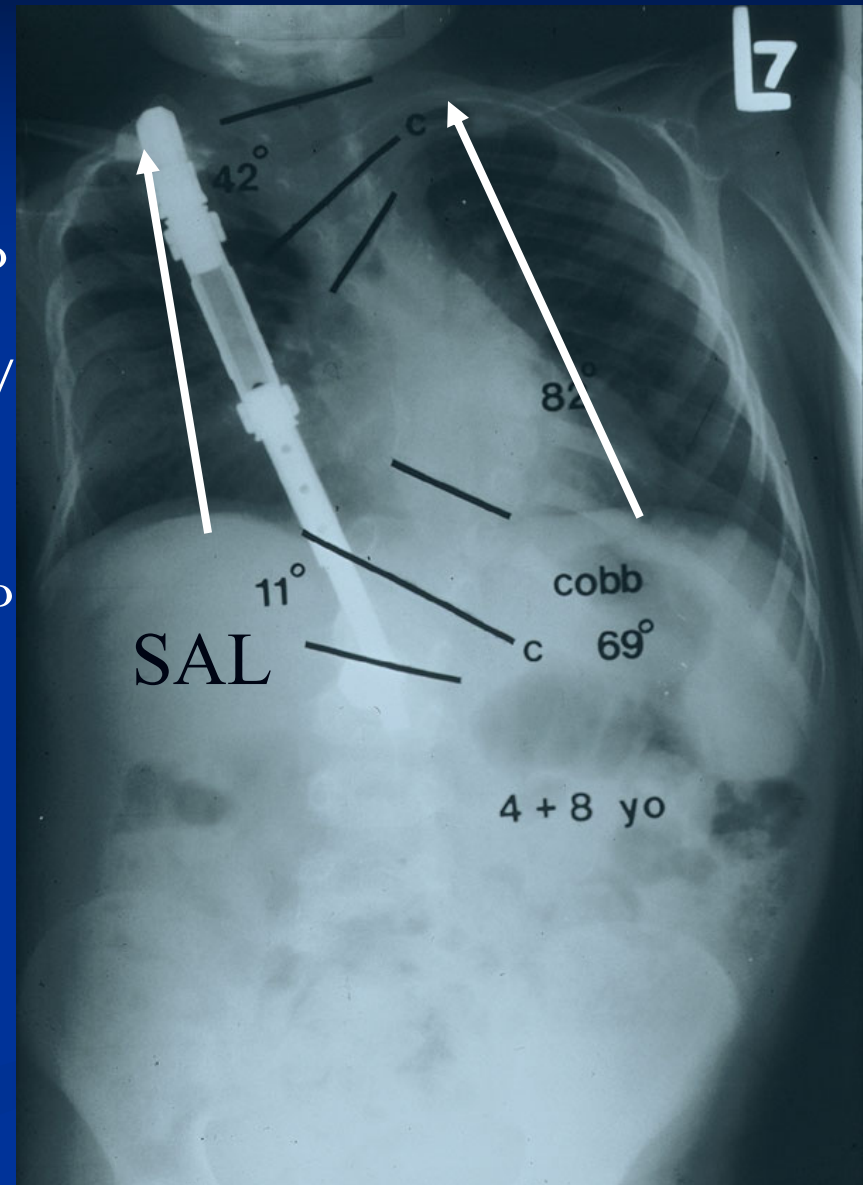
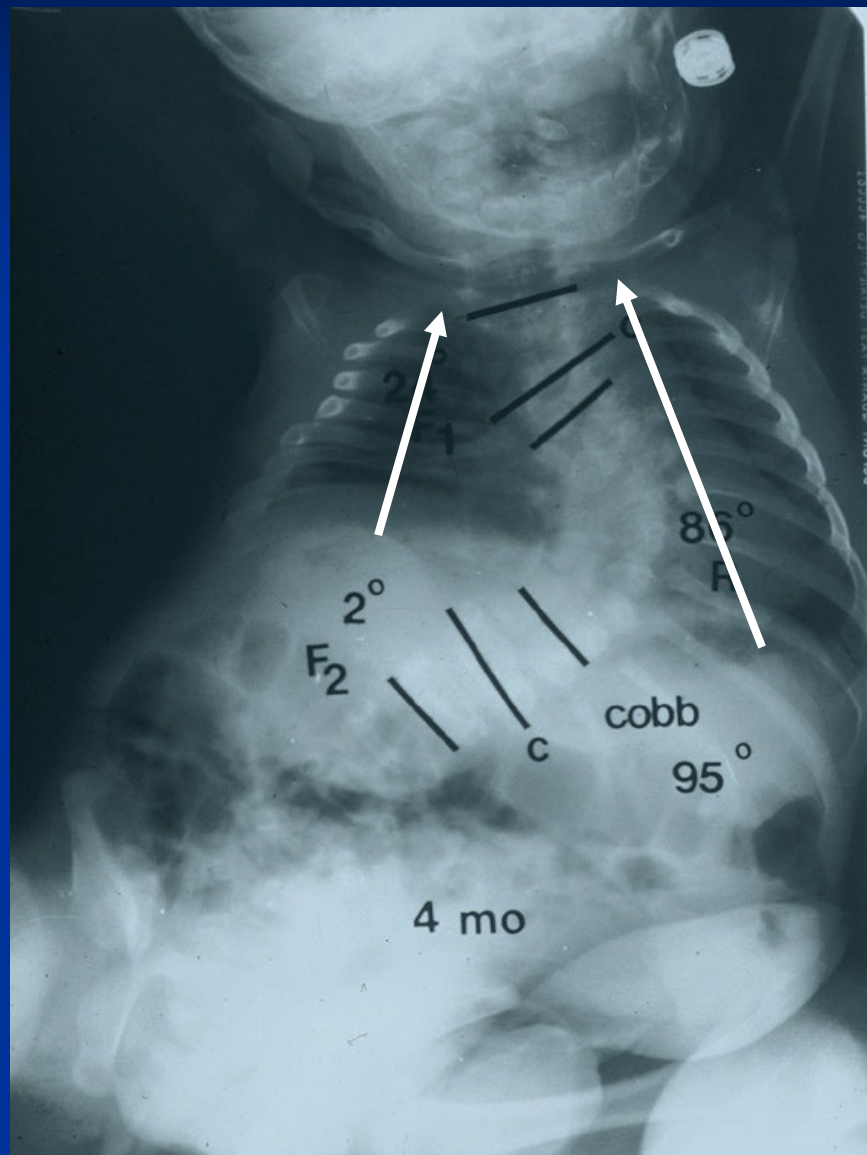
Effect on Rib Cage

“Wind Swept Thorax”

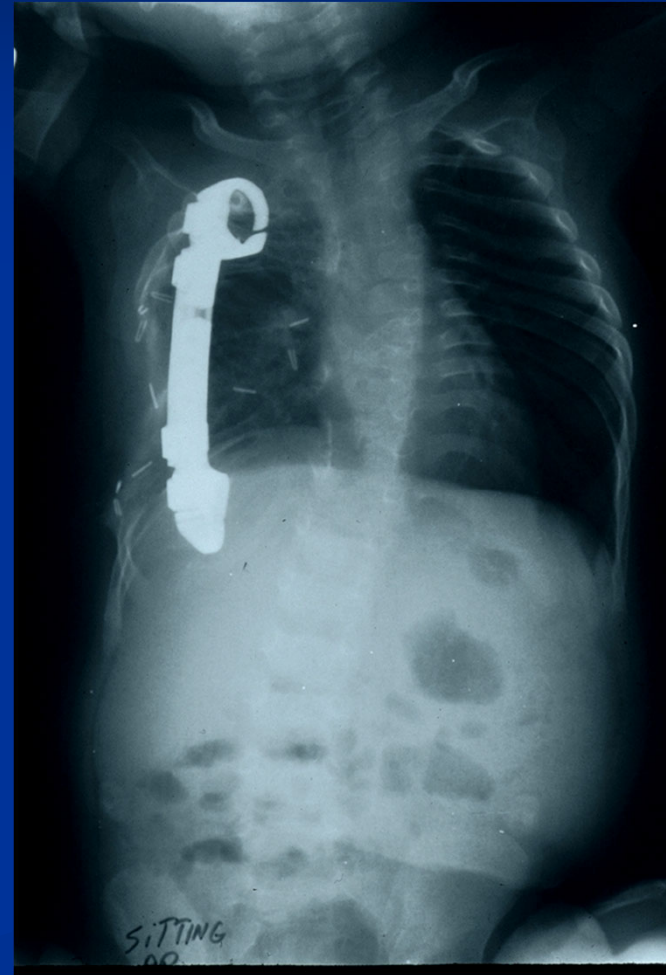
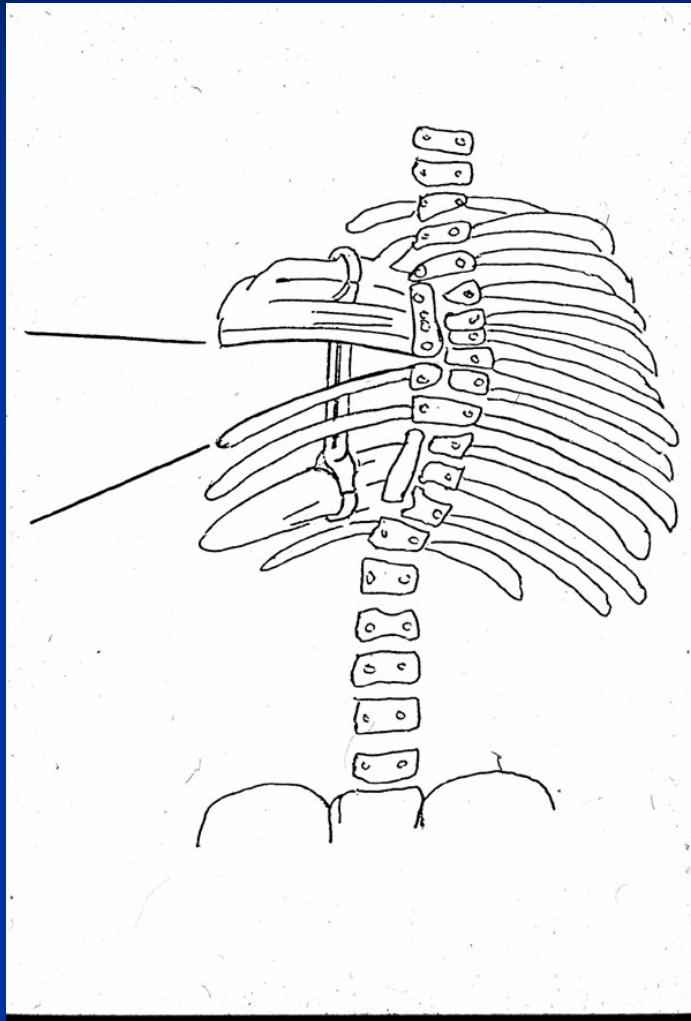
- Volume Reduction of Lung
- Motion Restriction of Ribs



“Chest Based” Treatment



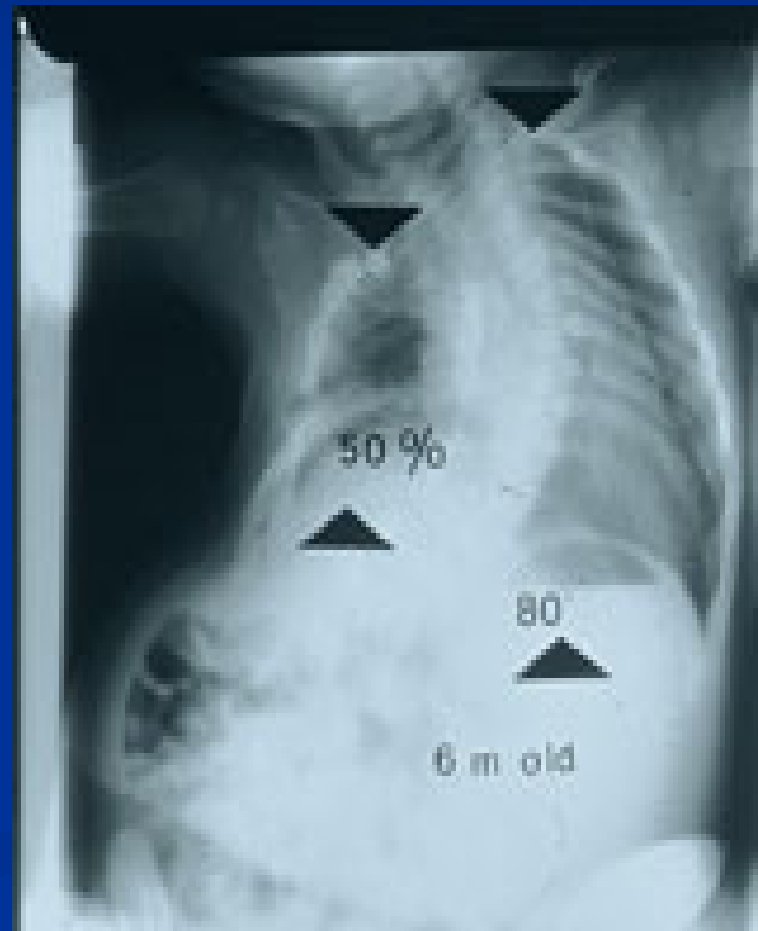
Opening Wedge Thoracostomy



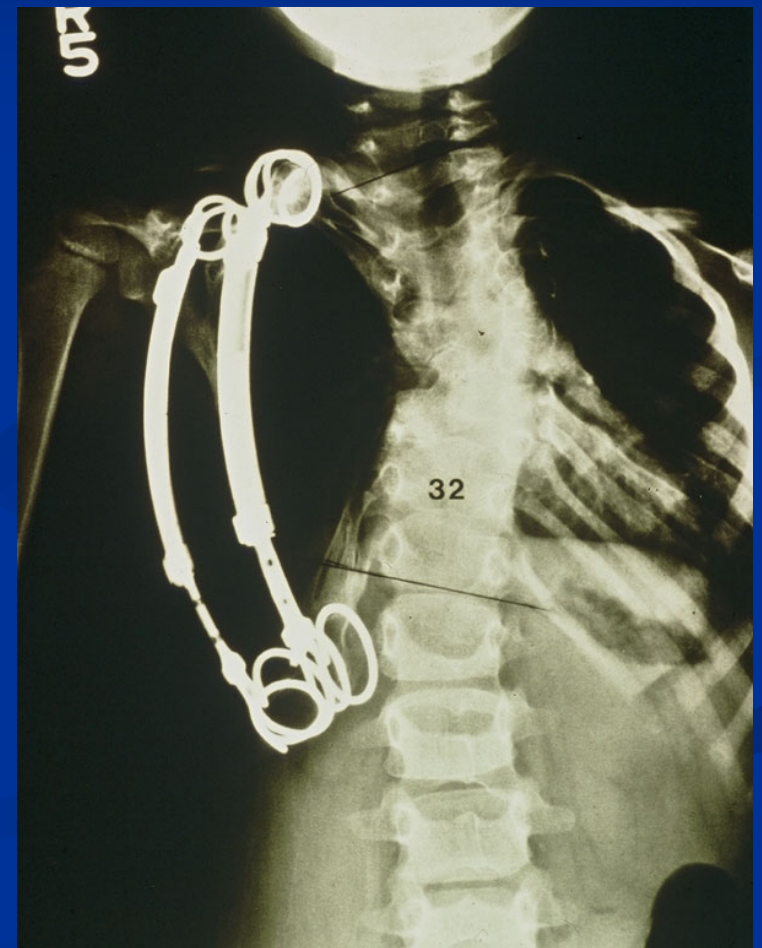
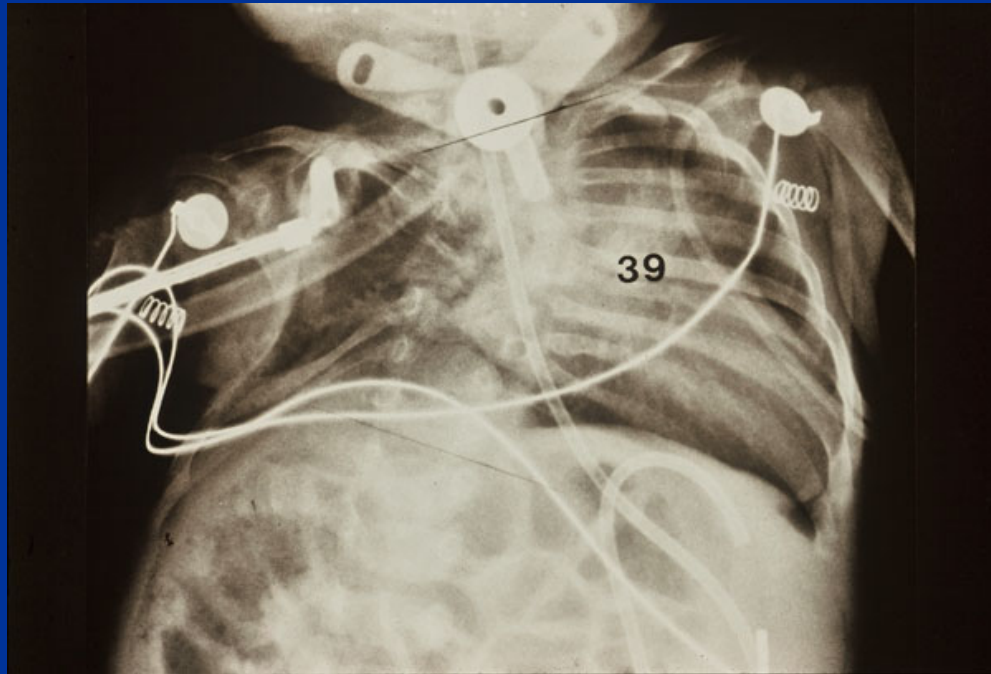
We all want the same thing



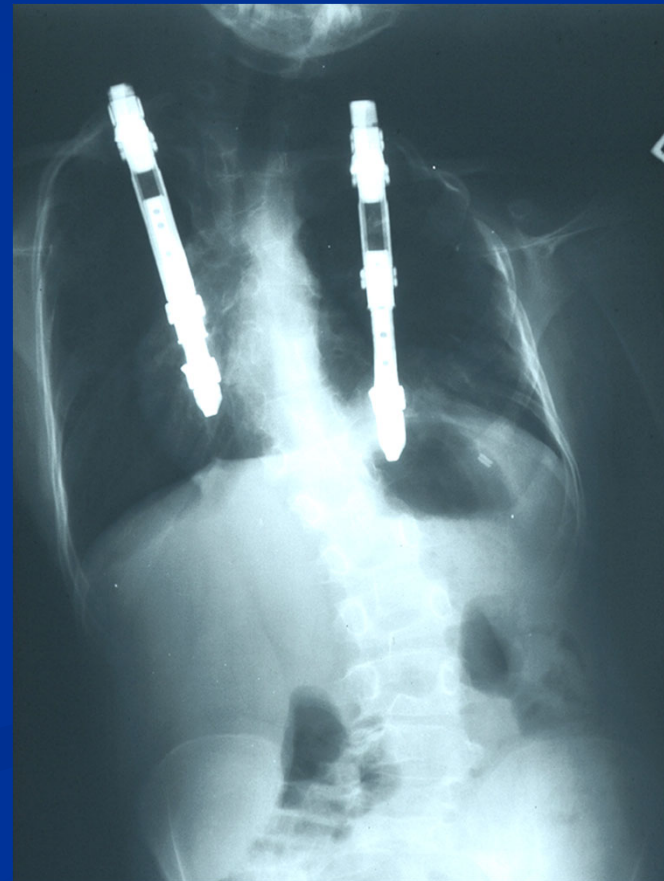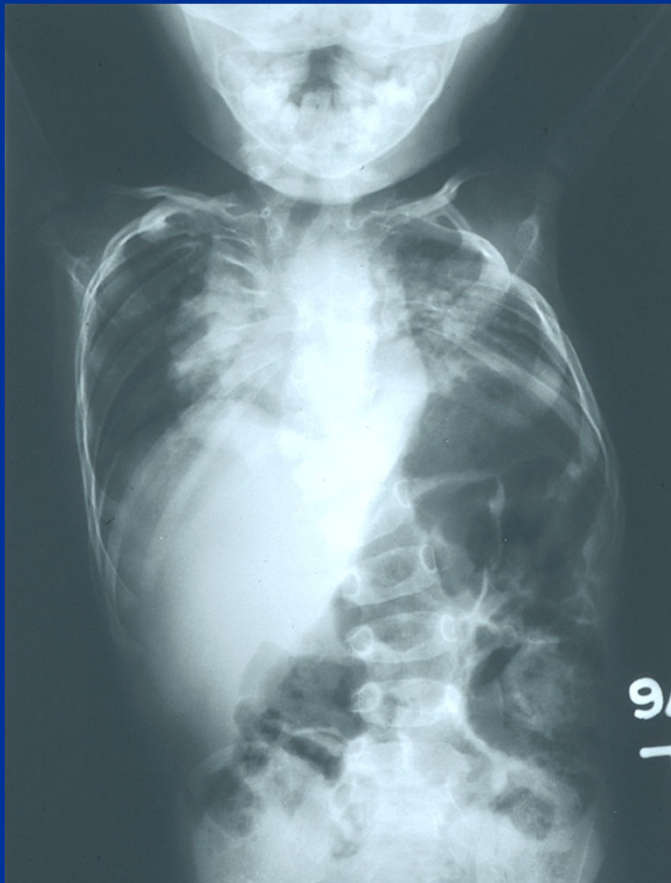
How do we best treat the ”train wrecks”?



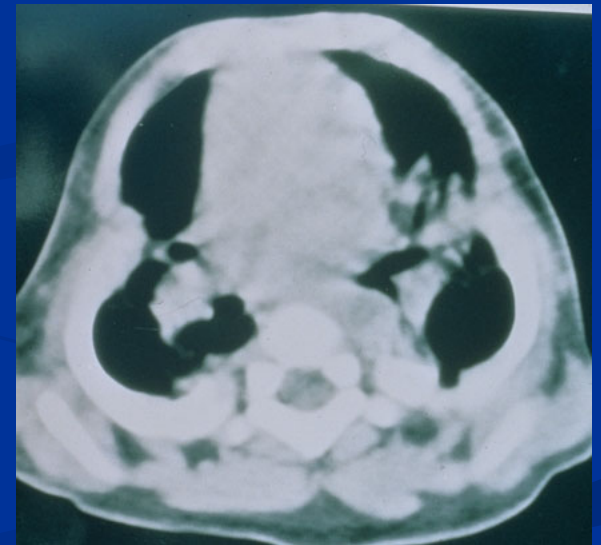
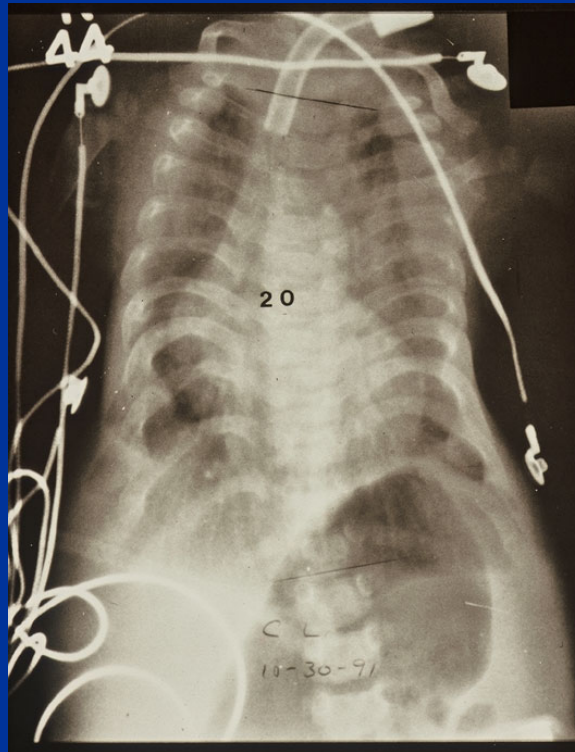
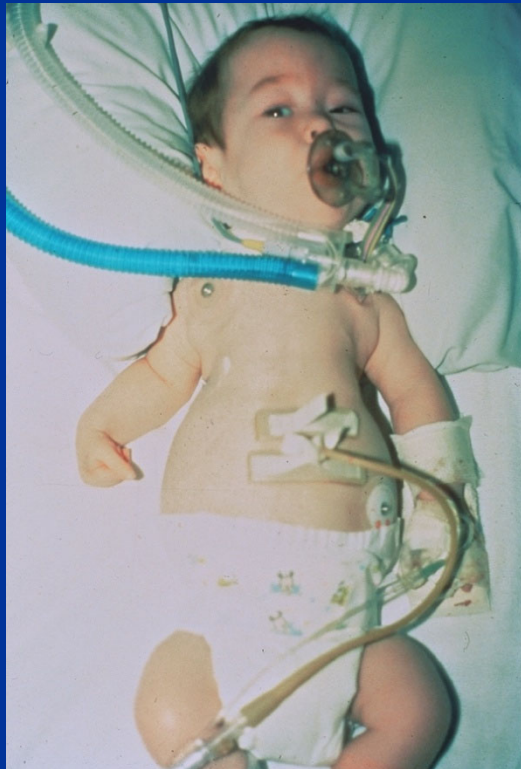Absent Ribs: Expansion Thoracoplasty by Multiple Devices



Fore-Shortened Thorax (Jarcho- Levin Syndrome): Bilateral Opening Wedge Thoracostomies



Hypoplastic Thorax(Jeune's Syndrome): Staged Bilateral Expansion Thoracoplasty



We are no way near our goal for morbidity-free
Chest-Based treatment



Thank you, Big John, for listening

