


# ° Growing Segmental Spinal Instrumentation: How Much Do They Grow?

Samuel Rosenfeld, M.D.

Benjamin Smith, D.O.

8<sup>th</sup> ICEOS

11/20/2014





# Disclosures

- Samuel Rosenfeld, M.D.
  - Medicrea Spine Consultant
- Benjamin Smith, D.O.
  - None



# Background

- Guided segmental spinal instrumentation in early onset scoliosis (EOS) results in growth and correction of deformity.
- The purpose is to report the long term follow up of patients with neuromuscular scoliosis including a subset with Spinal Muscular Atrophy that were treated surgically by growing posterior segmental spinal instrumentation without fusion via ONE surgical intervention

# Background

- Spinal muscular atrophy is a low tone neuromuscular group of disorders inherited in an autosomal recessive pattern, mapped via linkage studies to chromosome 5q.
- Clinical manifestations occur secondary to degeneration of the anterior horn cells of the spinal cord leading to symmetrical muscle weakness and atrophy of the trunk and proximal musculature of the shoulder and hip girdle.

Brzustowicz, L.M., et al., Genetic Mapping of Chronic Childhood-Onset Spinal Muscular Atrophy to Chromosome 5q11.2-13.3. *Nature*, 1990. 344(6266): 540-1

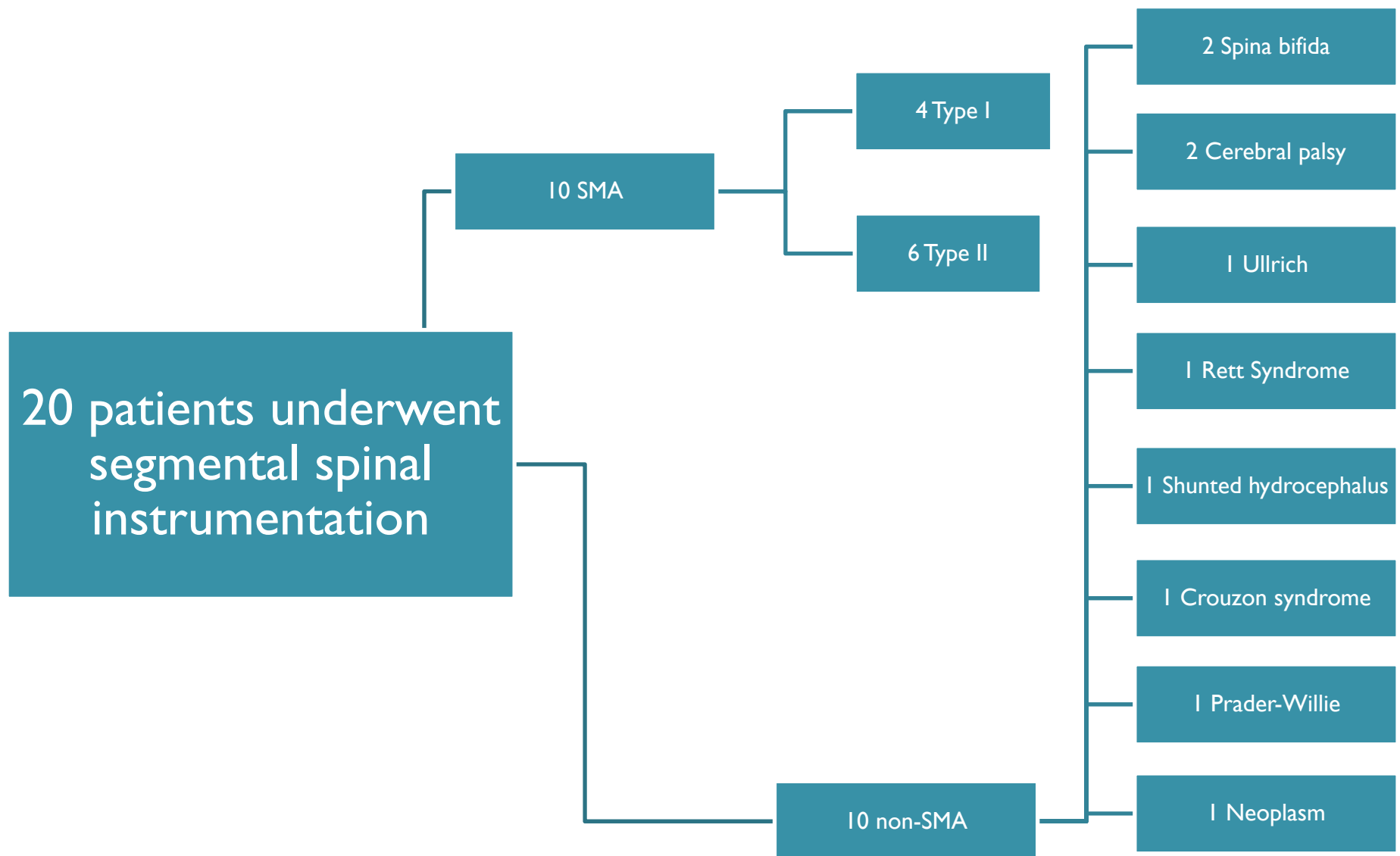
Thompson, G.H., Berenson, F.R. *Other neuromuscular Disorders*, in *Lovell and Winter's Pediatric Orthopaedics*, R.T. Morrissy, Weinstein, Stuart L., Editor. 2006, Lippincott Williams and Wilkins. p. 669-673.

# Background

- Spinal deformity is commonly associated with SMA.
  - The pelvic obliquity is proportional to the severity of the curve
  - Early onset
  - Progresses rapidly prior to the onset of puberty
- Restrictive lung disease advances simultaneously with the progression of the spinal curvature.
- In SMA, survival typically depends on the degree of respiratory involvement with atelectasis and pneumonia as the usual causes of death.

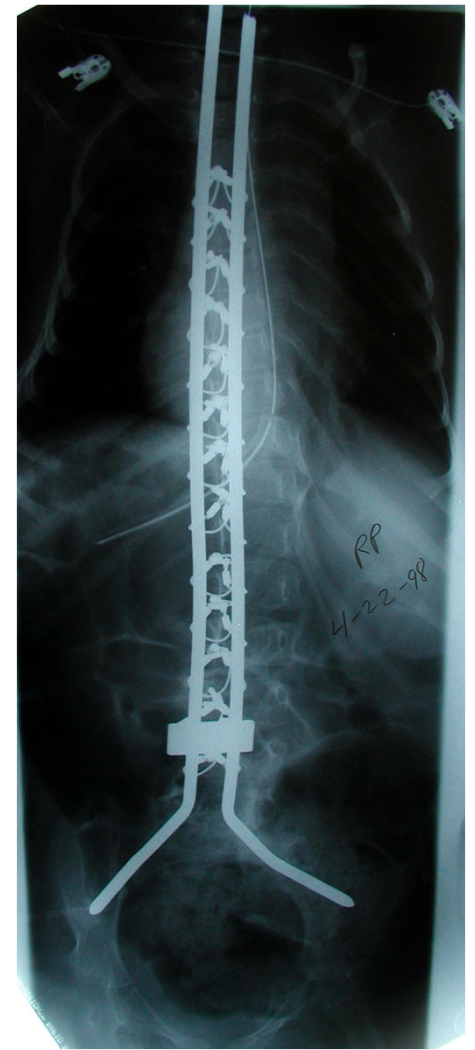
Rodillo, E., et al., *Scoliosis in Spinal Muscular Atrophy: Review of 63 cases*. J Child Neuro, 1989. 4(2): 118-23.

Russman, B.S., et al, *Spinal Muscular Atrophy: The natural course of disease*. Muscle Nerve, 1983. 6(3): 179-81.



# Surgical Technique

- A standard posterior approach
- Subperiosteal dissection of the lamina was carried laterally to the facet joints which were preserved.
- Sublaminar cables were passed at each level
- Two stainless steel rods were cut and contoured for maximal curve correction, normal sagittal alignment, and secured in the ilium (except for 2 hybrid Shilla type constructs)





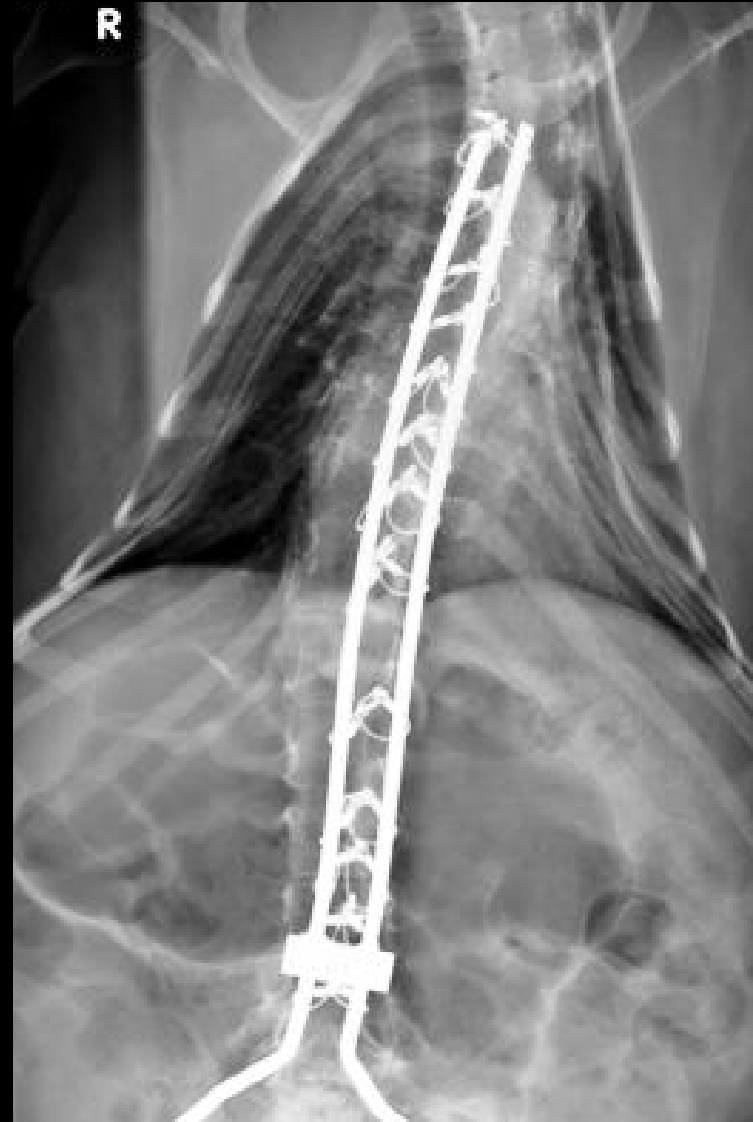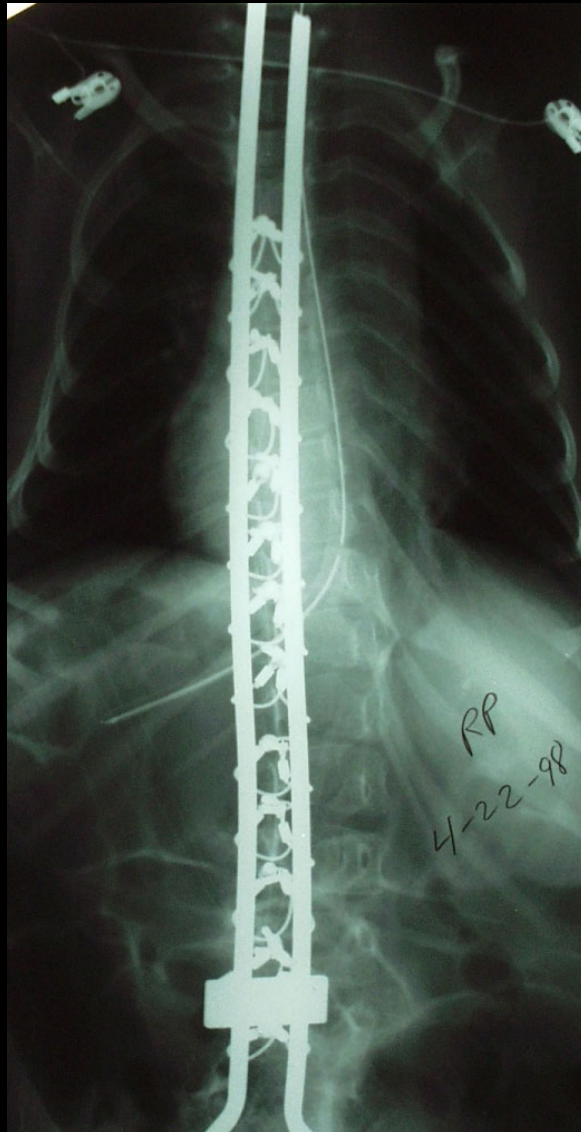
# Surgical Technique

- A crosslink was placed at the caudal end of the construct
- The cephalad rod ends were left long
  1. To Allow spinal growth along the construct
  2. Obviate the need for further lengthening surgeries
- Postoperative bracing was not utilized

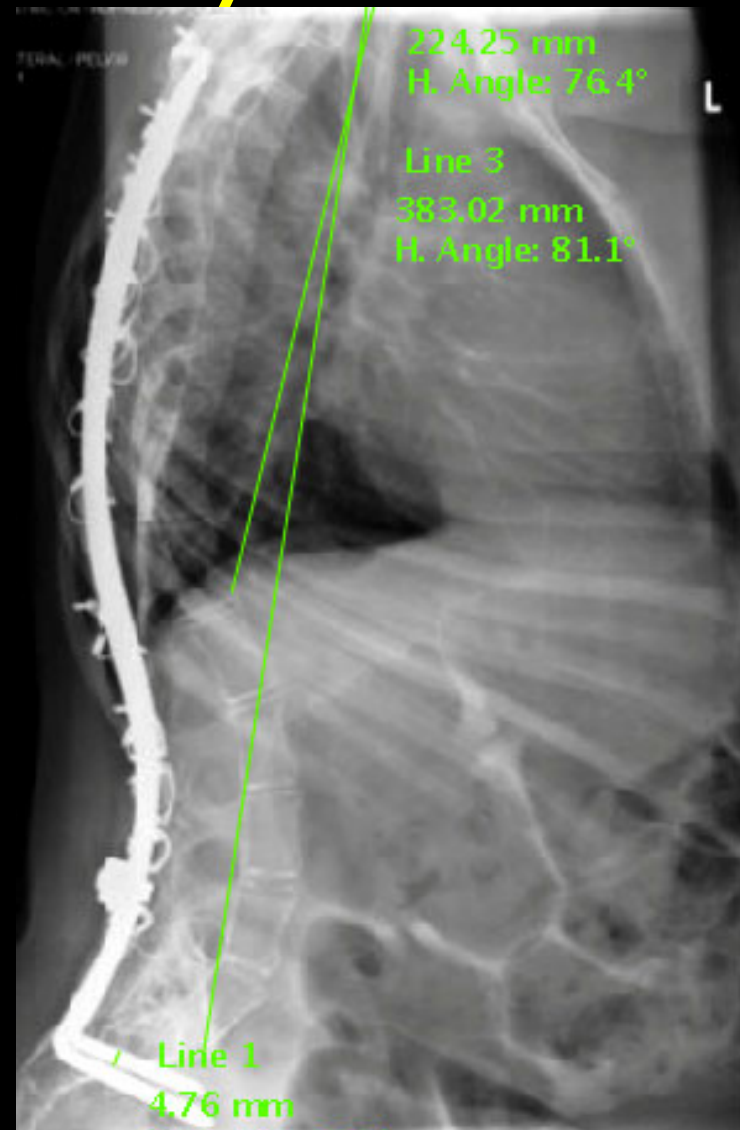
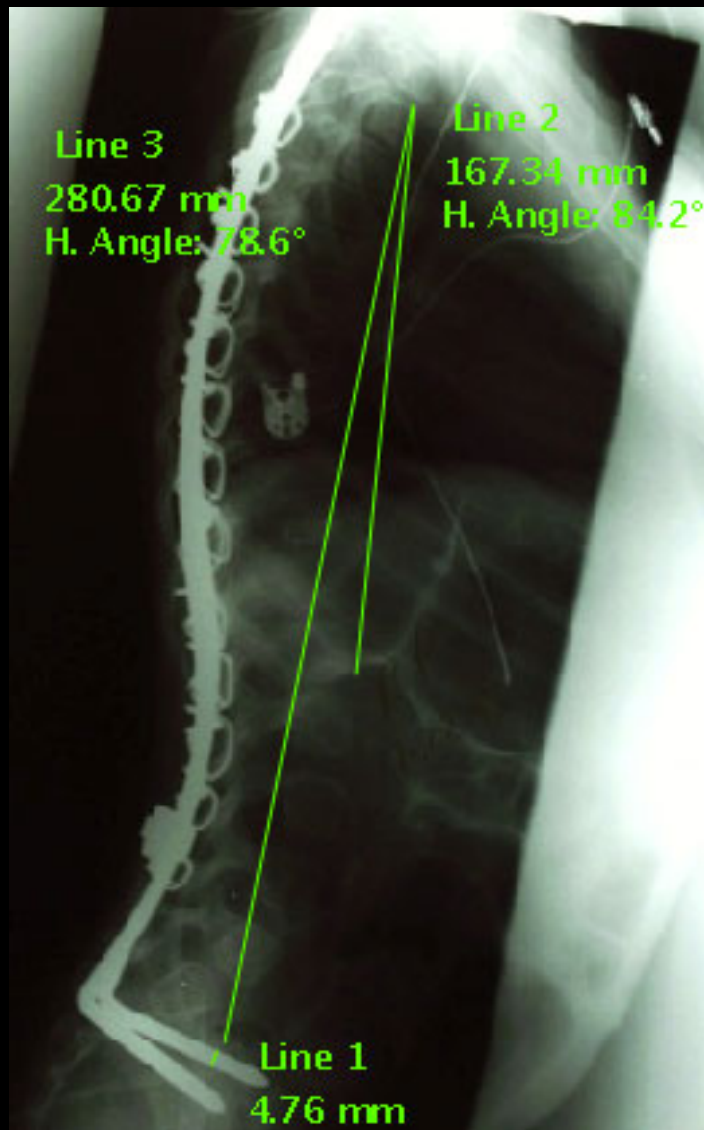
# Methods

- Radiographs were evaluated via Surgimap spine software for:
  - Correction and maintenance of deformity
  - Spinal growth (T1-L2 and T1-S1)
  - Proximal Junctional Kyphosis
  - Evidence of hardware failure

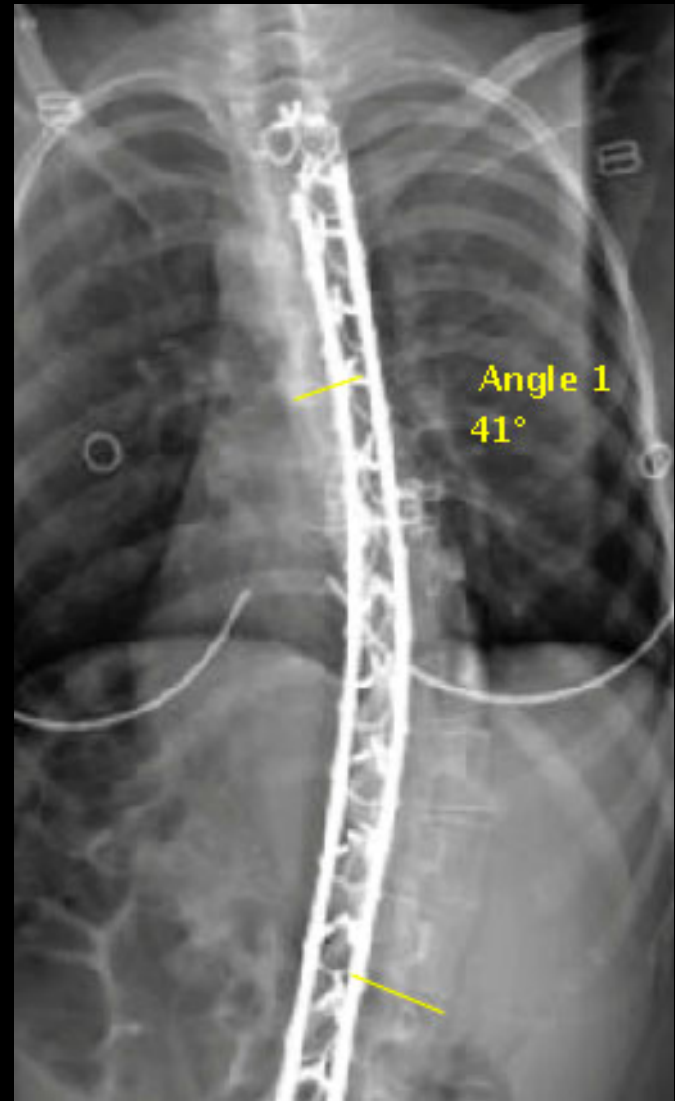
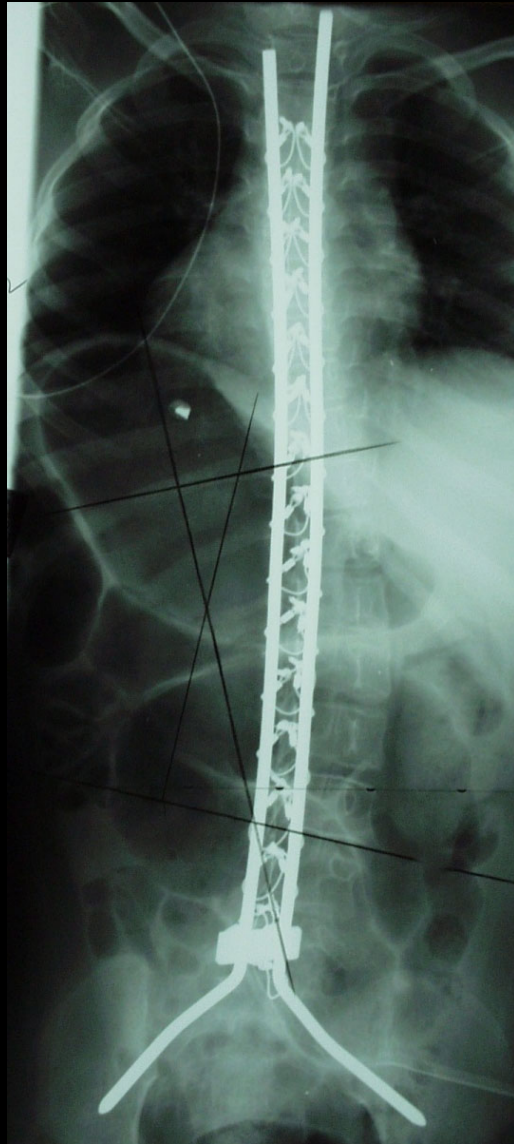
# SMA II with 13 year f/u



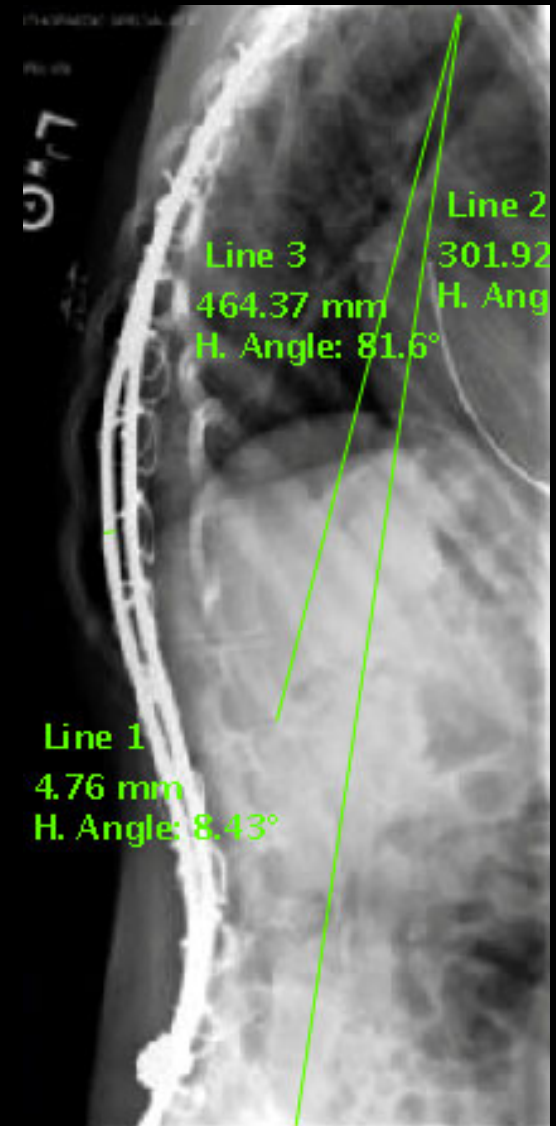
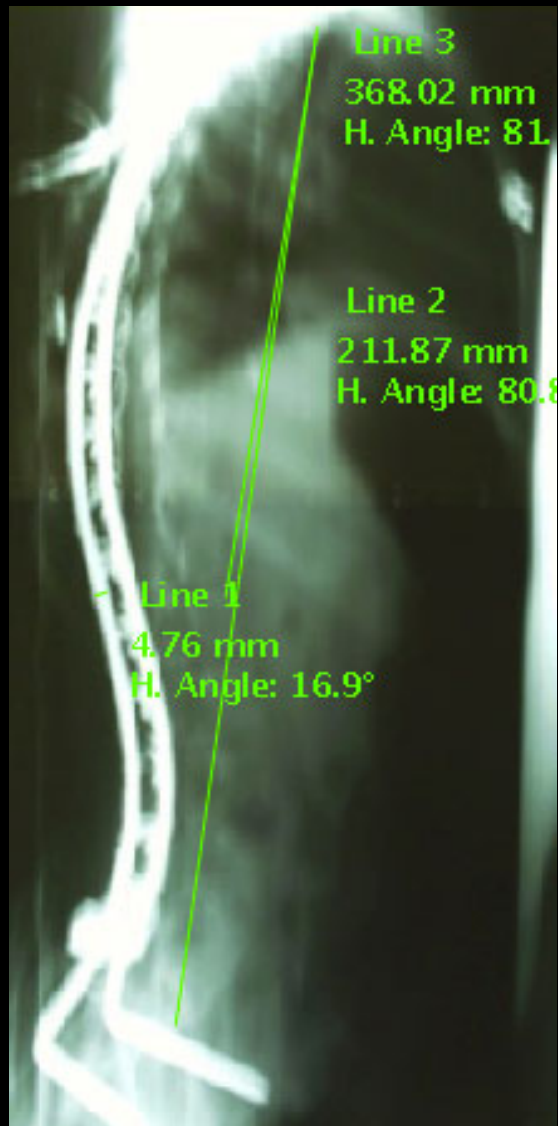
# SMA II with 13 year f/u



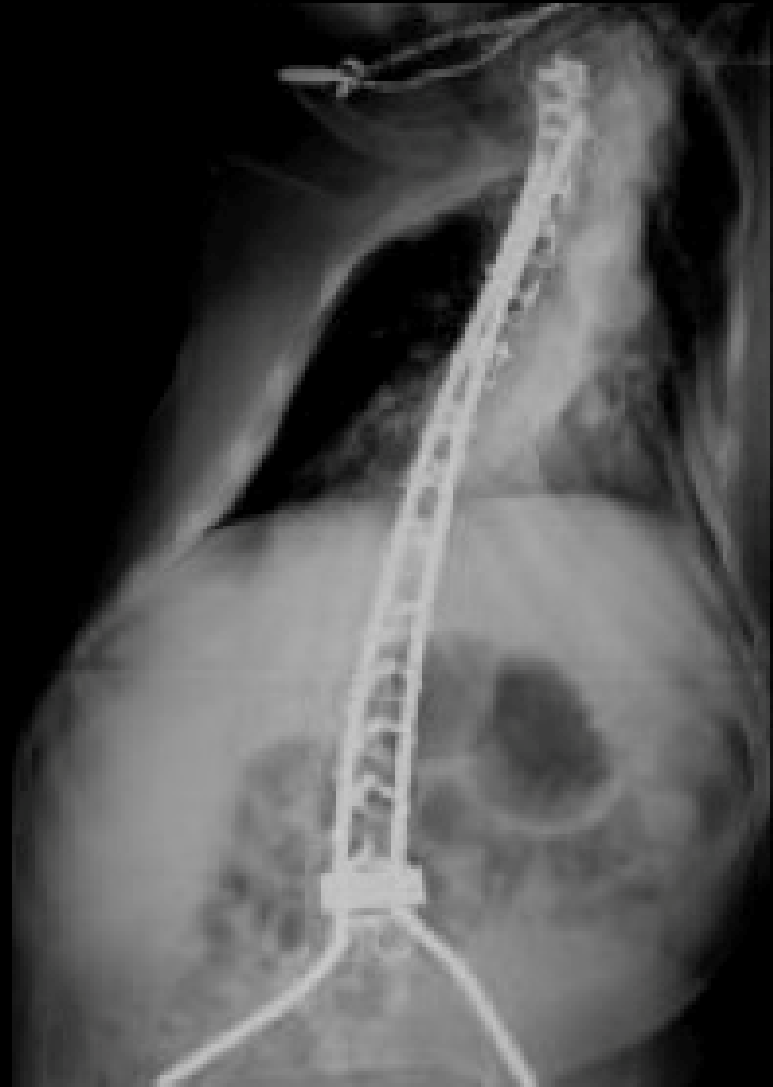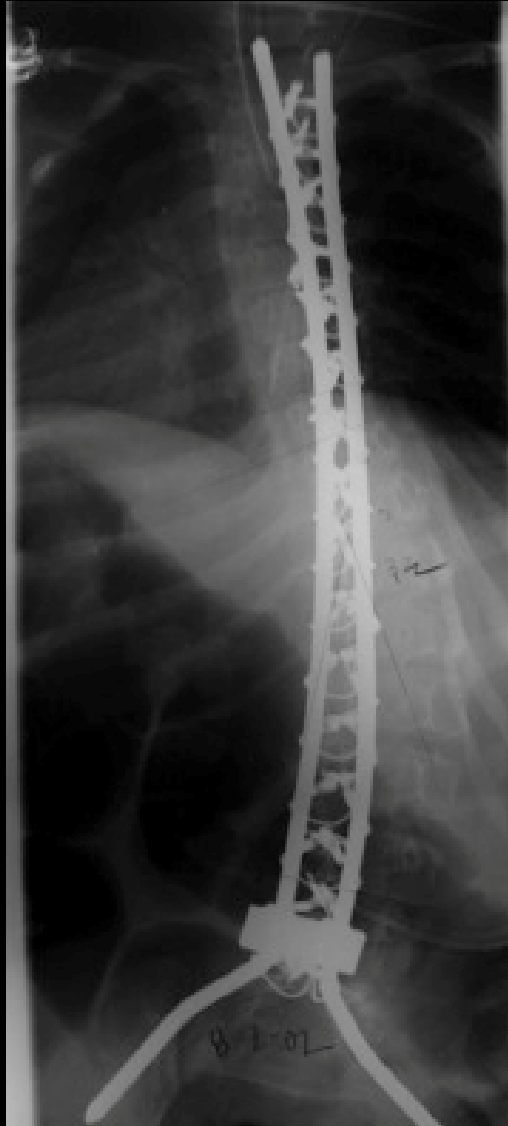# SMA II with 9 year f/u



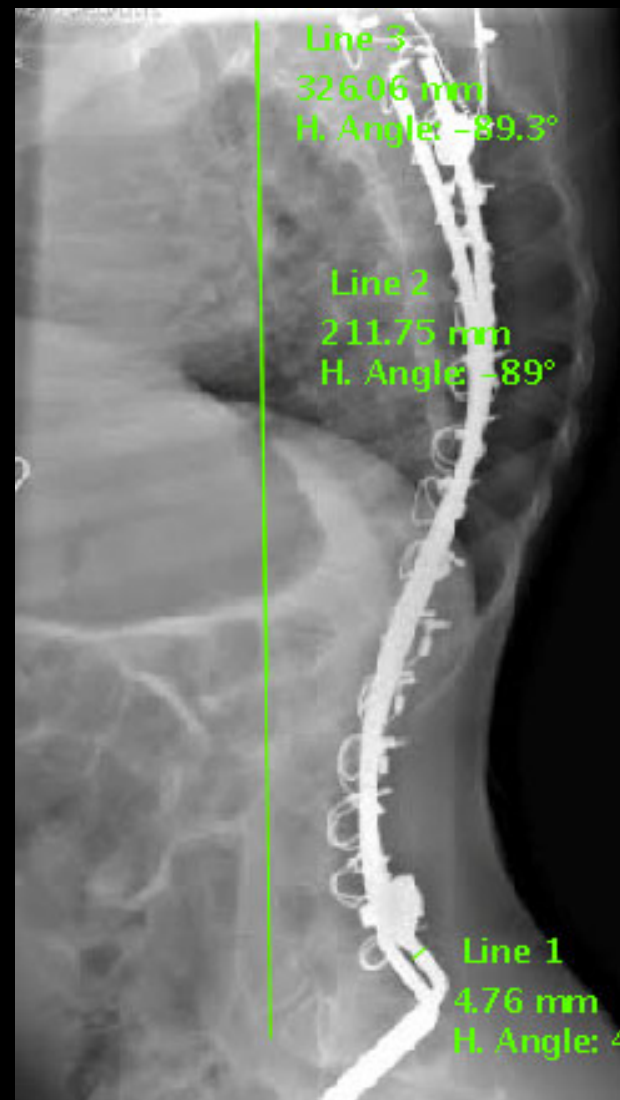
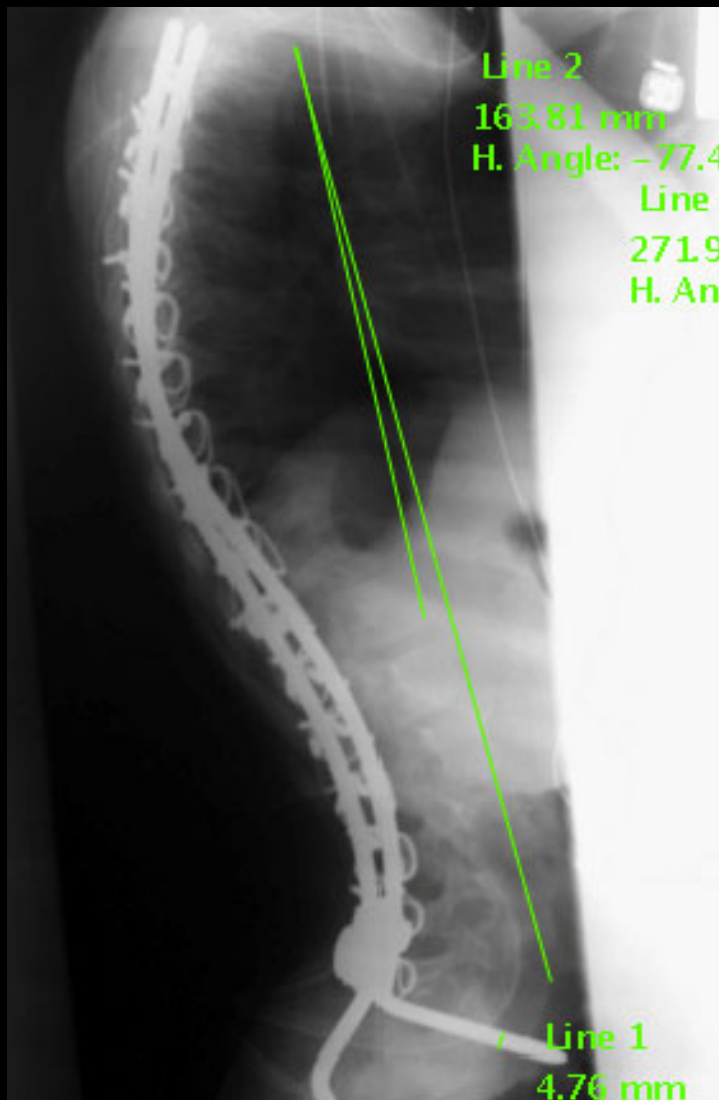
# SMA II with 9 year f/u



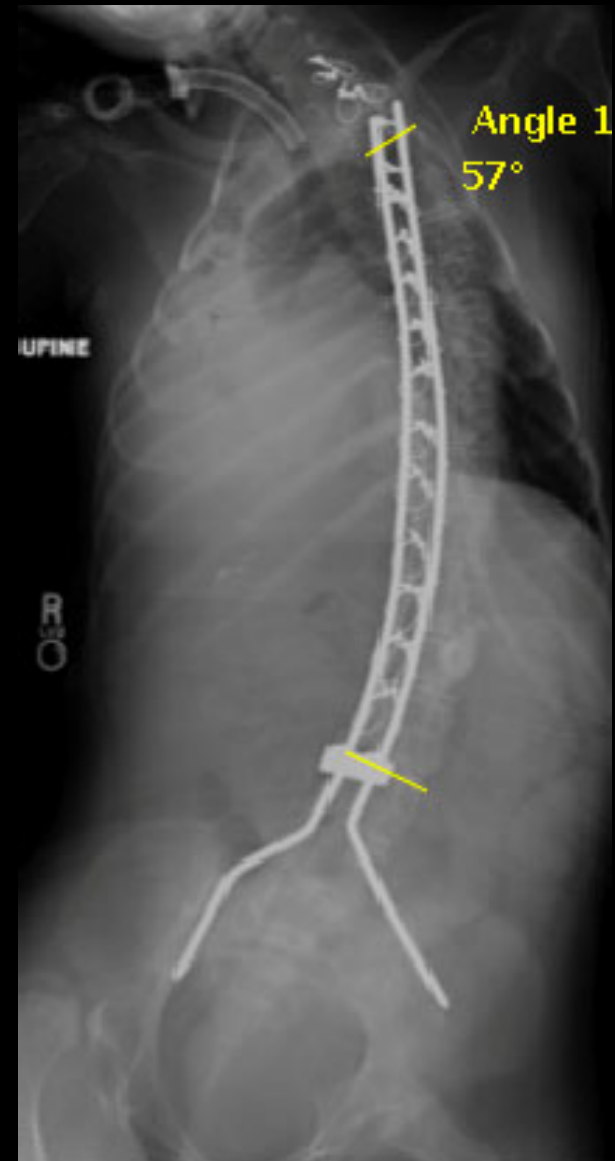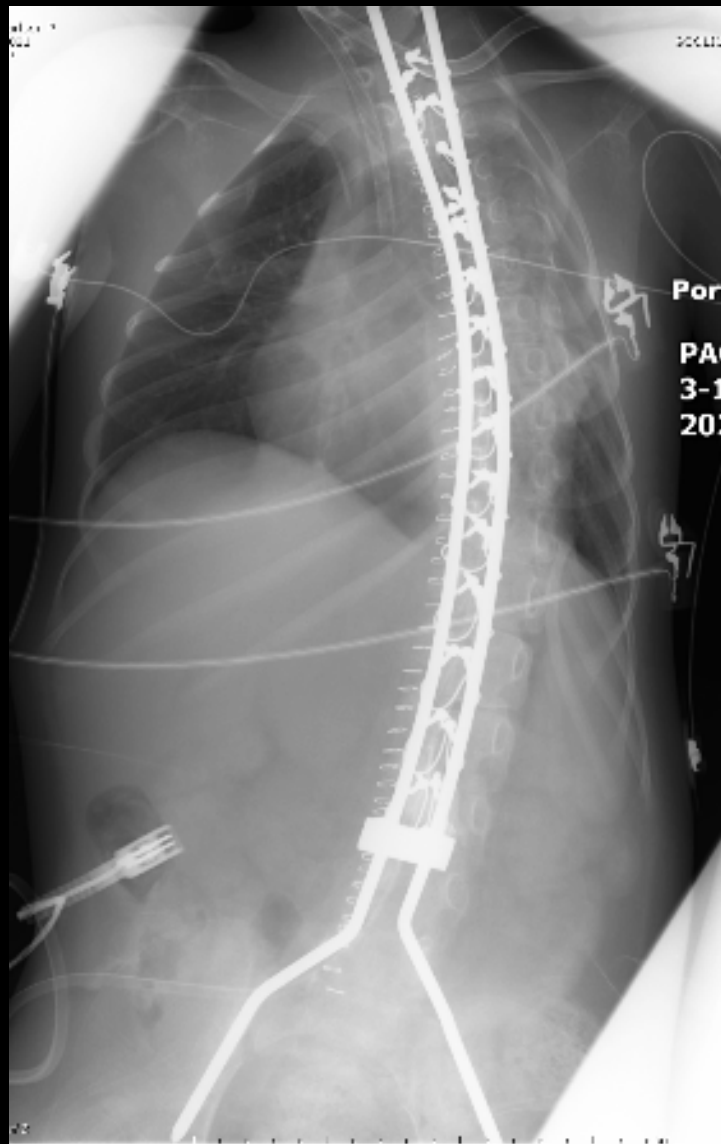
# SMA I with 13 year f/u



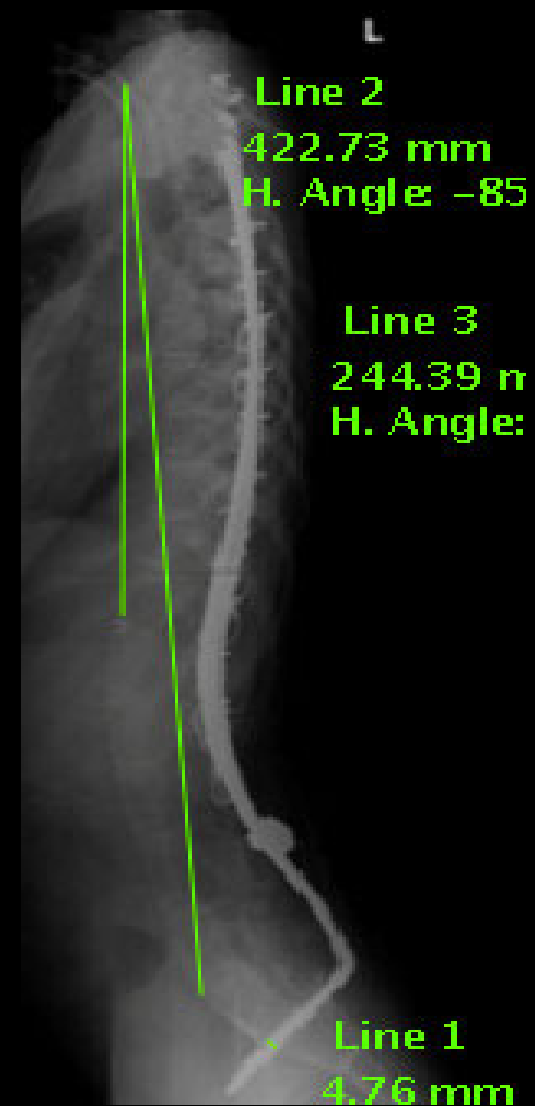
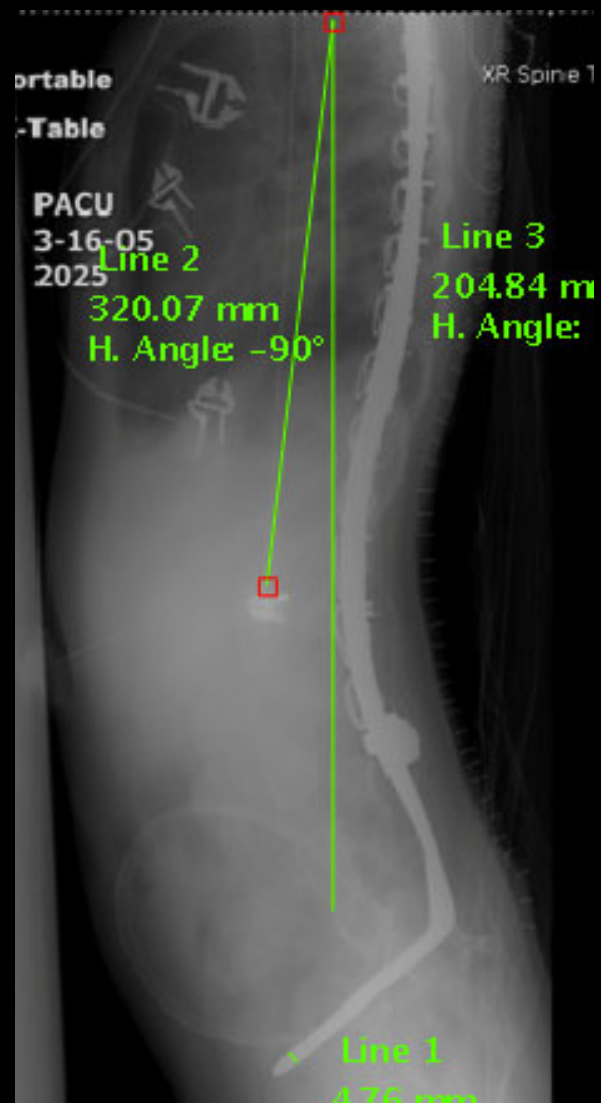
# SMA I with 13 year f/u



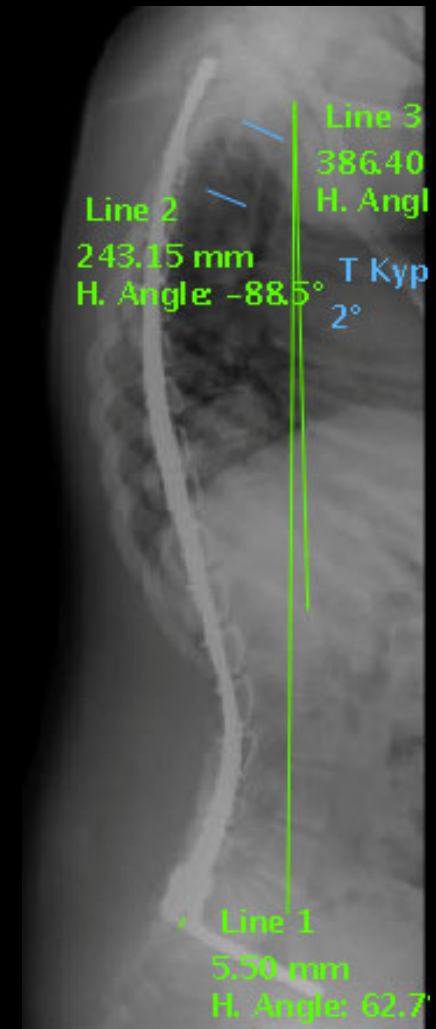
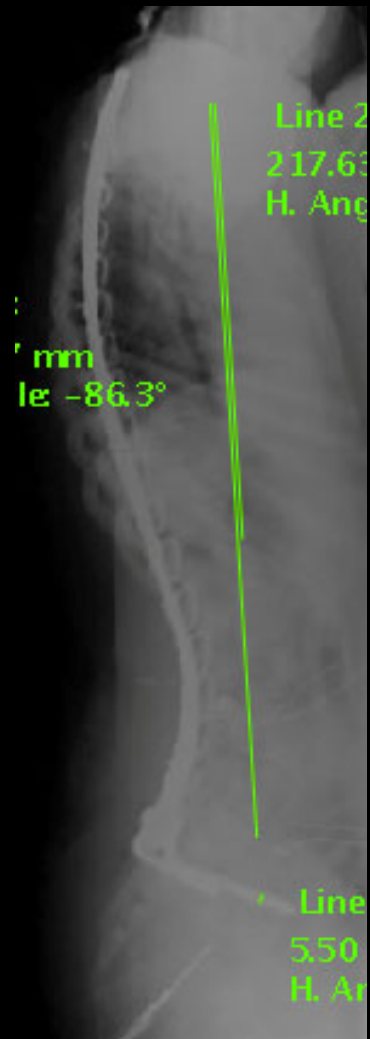# SMA I with 6 year f/u



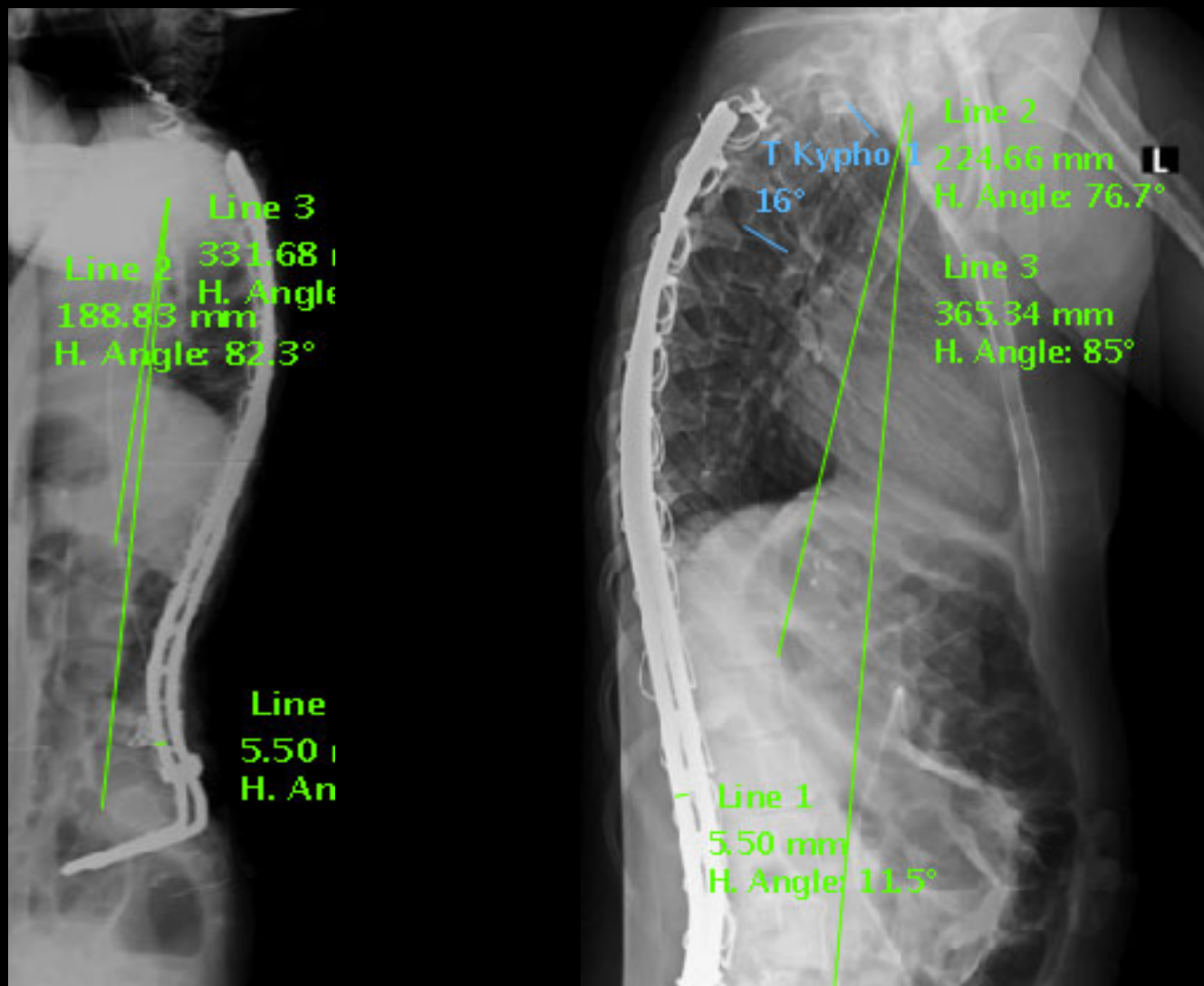
# SMA I with 6 year f/u



# Ullrich Muscular Dystrophy with 37 month f/u



# Rett Syndrome with 28 month f/u





# Data

- 15 of the 20 patients meet the criteria for 2 year follow up
- The average age at surgery was 7 years, 9 months (59-126 months)
- On average 15 spinal segments were instrumented (8-16 segments)
- Average follow up was 43.6 months (24-124 months)

# Results

	<b>SMA (9)</b>	<b>Non-SMA (6)</b>
<b>Age</b>	83 months (59-126)	103 months (92-117)
<b>Average Follow Up</b>	58 months (28-124)	29 months (24-36)
<b>Pre-op Cobb</b>	47°	60°
<b>Post-op Cobb</b>	21°	21°
<b>Current Cobb</b>	30°	29°
<b>Percent Loss of Correction</b>	35%	23%
<b>Average PJK</b>	11°	7°
<b>T1-T12 Average Growth</b>	0.9 cm/year	1.3 cm/year
<b>T1-S1 Average Growth</b>	1.5 cm/year	1.9 cm/year
<b>T1-I2 Average Total Growth</b>	4.3 cm	2.9 cm
<b>T1-S1 Average Total Growth</b>	7.2 cm	4.1 cm



# Conclusion

- Segmental Spinal Instrumentation without fusion is a safe and effective procedure when treating the spinal deformity in the EOS patient population
- Scoliosis correction and sagittal alignment were maintained while allowing for continued growth without the use of external immobilization
- None of these patients exhibited progressive restrictive pulmonary disease during treatment and all patients are currently alive and doing well
- Complications did not interfere with the spinal growth or compromise the instrumentation



# Conclusion

- Growing Segmental Spinal Instrumentation without fusion is a well-tolerated & effective surgical technique that avoids the morbidity associated with multiple surgeries in early onset neuromuscular scoliosis
- The Growth Documented with Guided Segmental Spinal Instrumentation is comparable to Distraction techniques without the risks associated with multiple surgical procedures.